

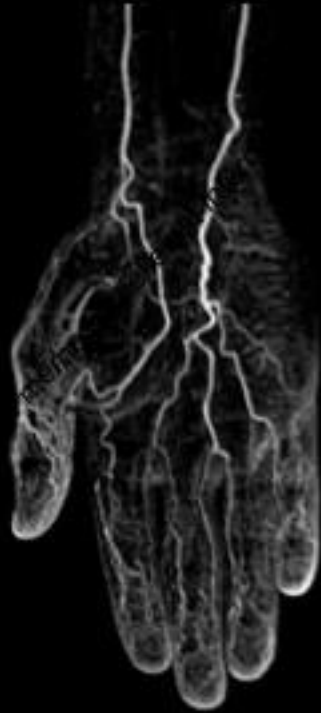
A l'Aide,  
Rien ne passe sur le guide de CTO !



Institut  
Cardio-Vasculaire

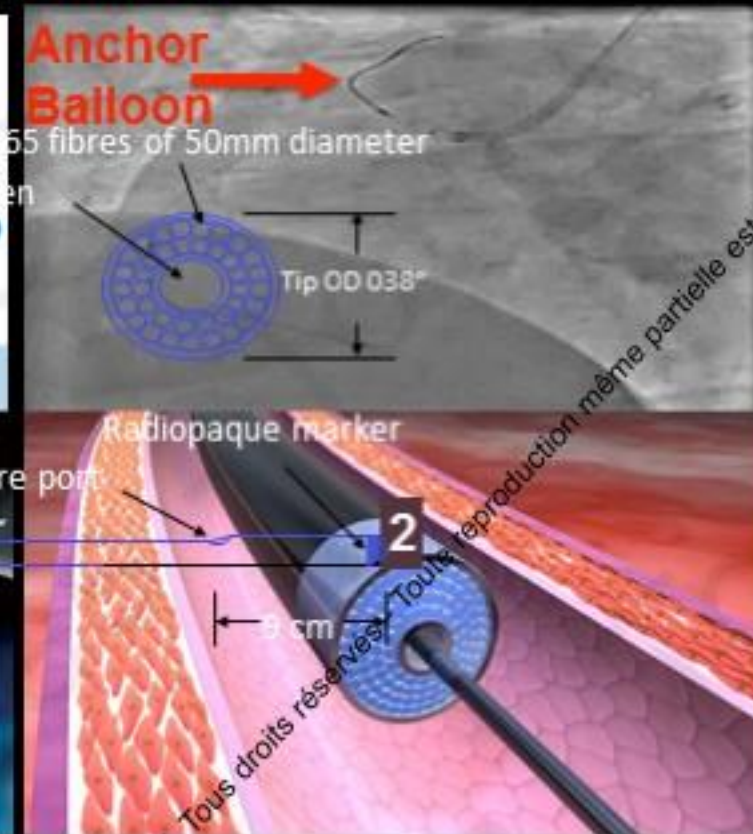
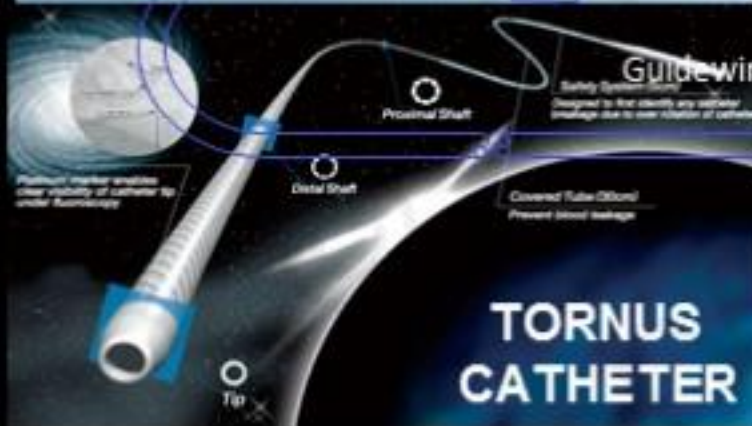
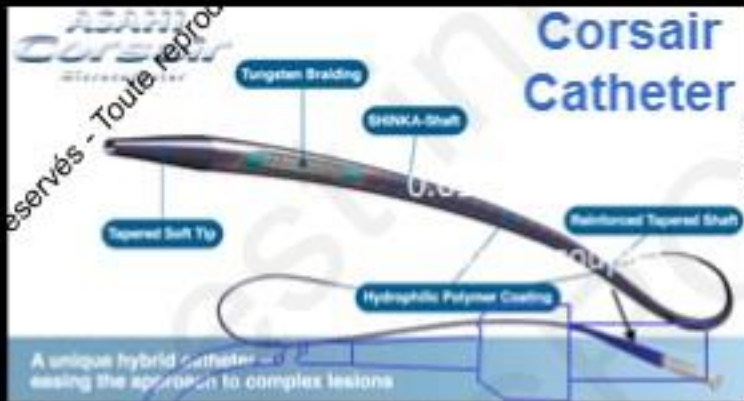GROUPE HOSPITALIER  
MUTUALISTE DE GRENOBLE

# GRCI 2017



**Dr Benjamin Faurie**  
CardioVascular Institute  
Groupe Hospitalier Mutualiste de Grenoble  
Grenoble, FRANCE

# Nothing but a wire can cross



# Nothing but a wire can cross

- Push hard ! Push harder !
- Good Backup
  - Large GC
  - Active intubation
  - Guide Cath extension (Guideliner, M&Child, Guidezilla)
- Anchoring (antegrade, OTW, retrograde)
- Tornus (Ca++)
- Grenadoplasty...

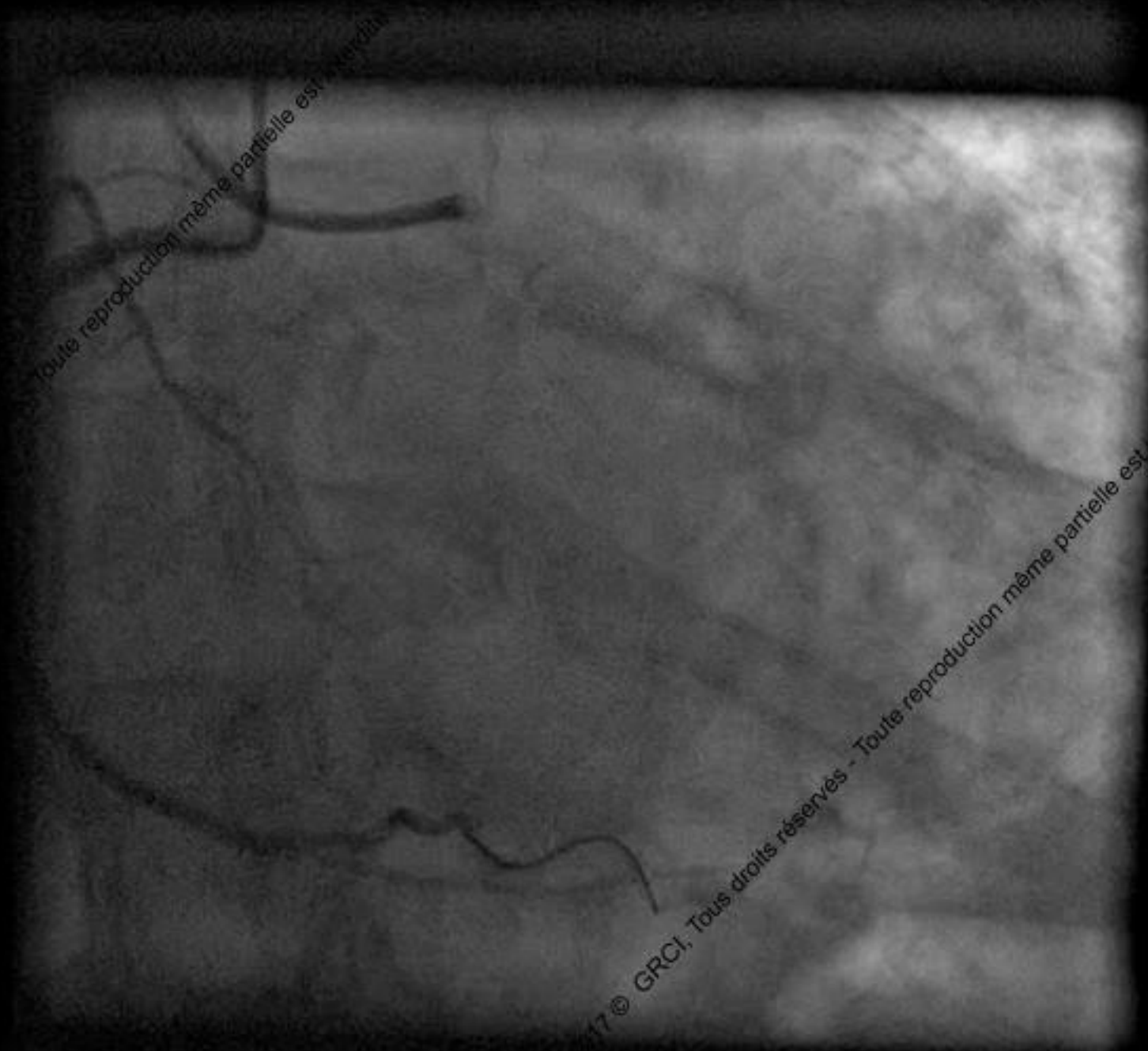# Nothing but a wire can cross

- Diprivan / Rotaglide
- Rotablator (if 0.009' wire cross)
- Lazer
- out of lumen (ADR, R-CART, balloon outside)



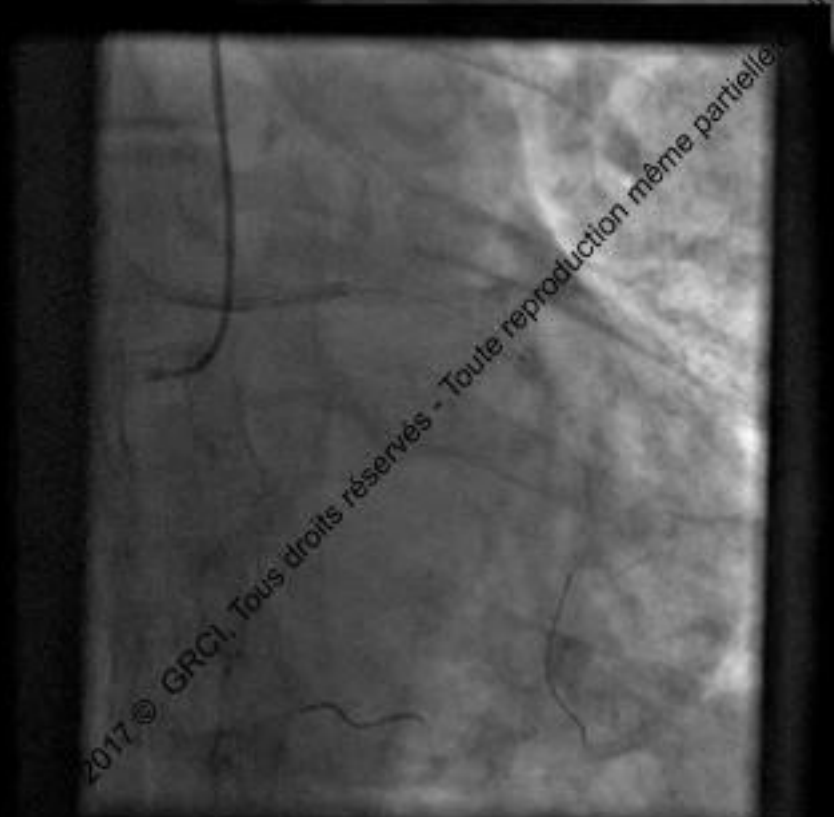
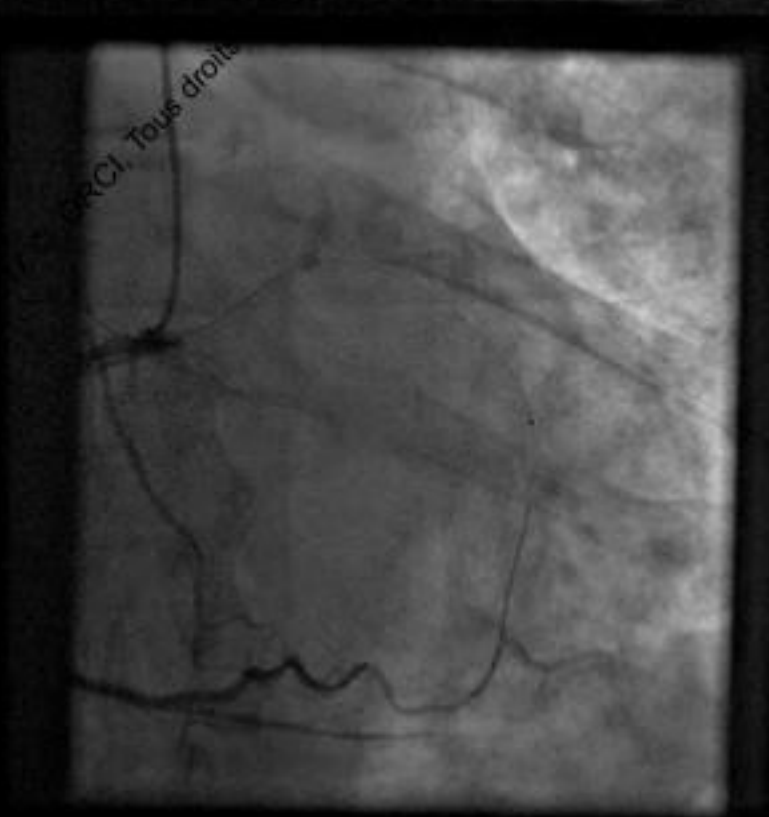
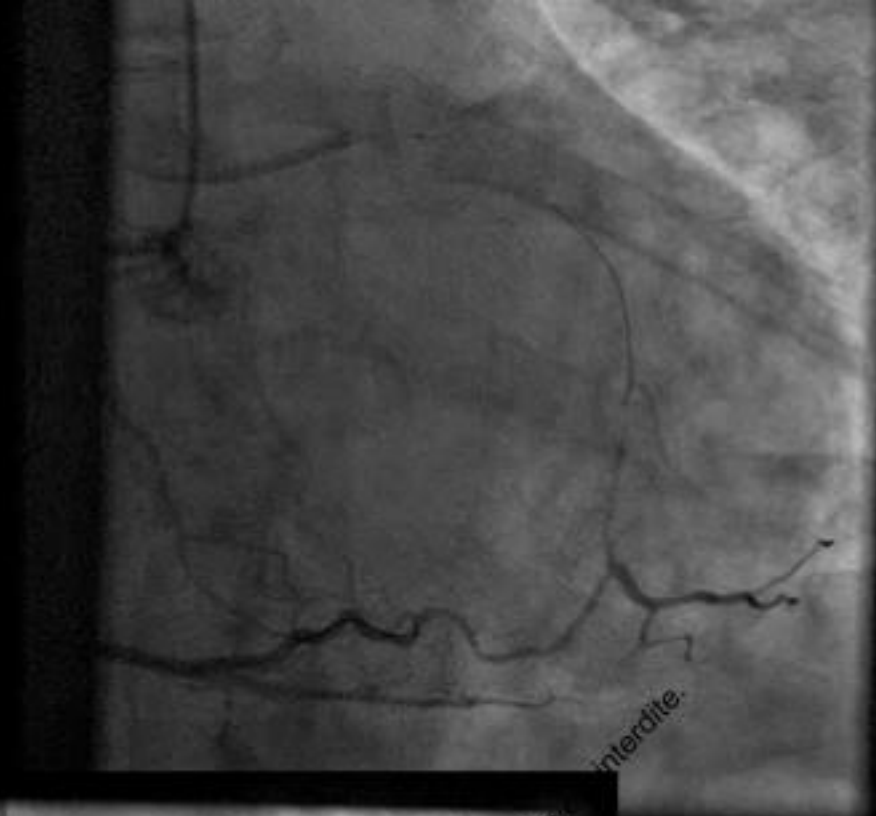
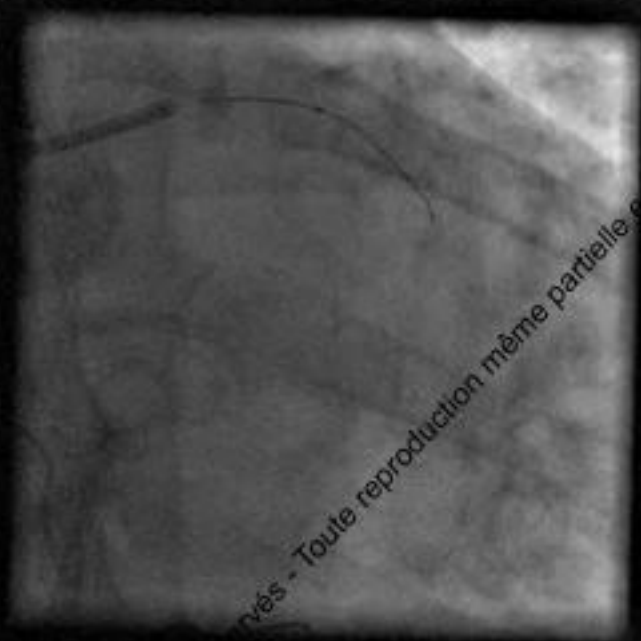
# A very difficult CTO !

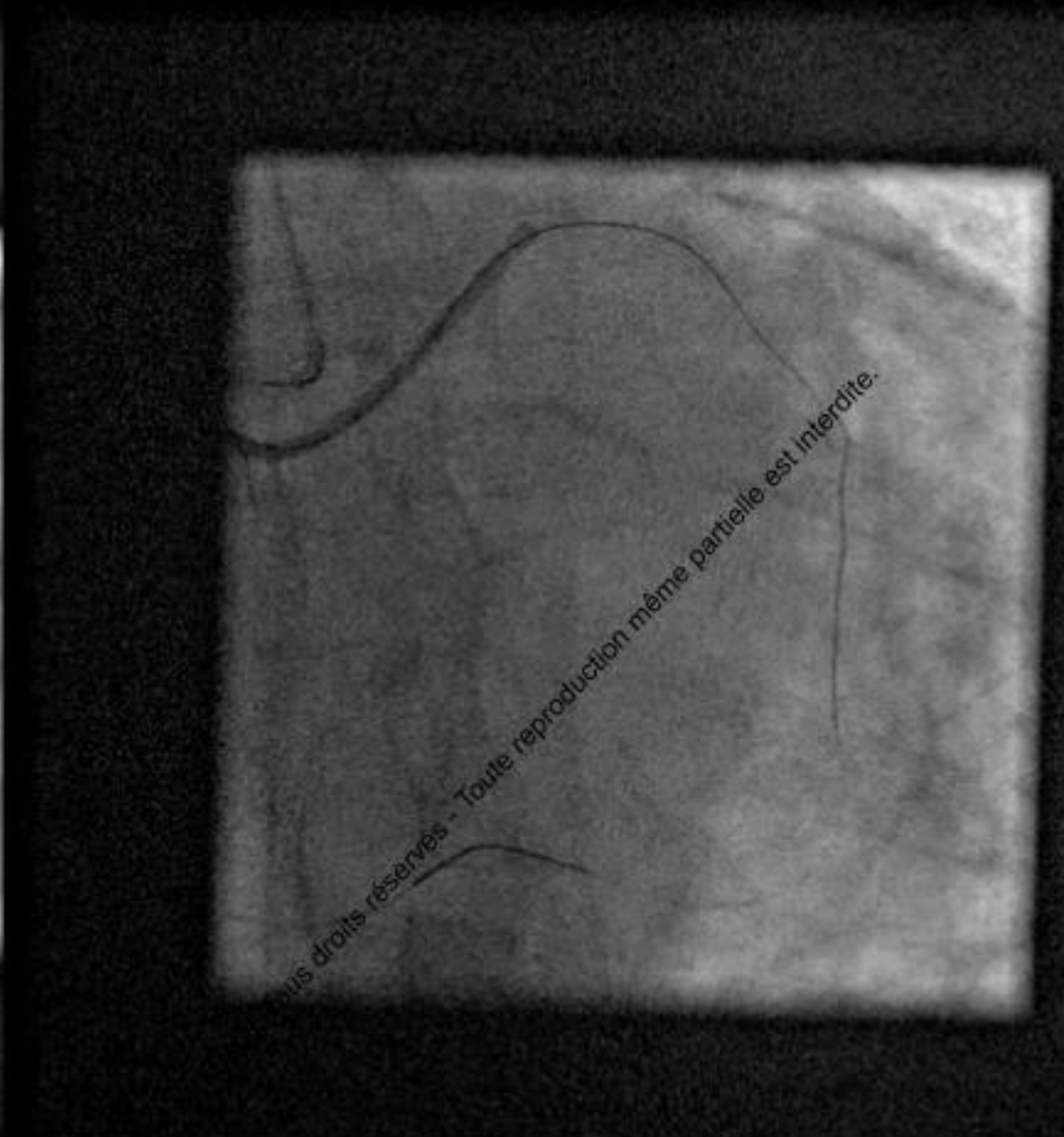
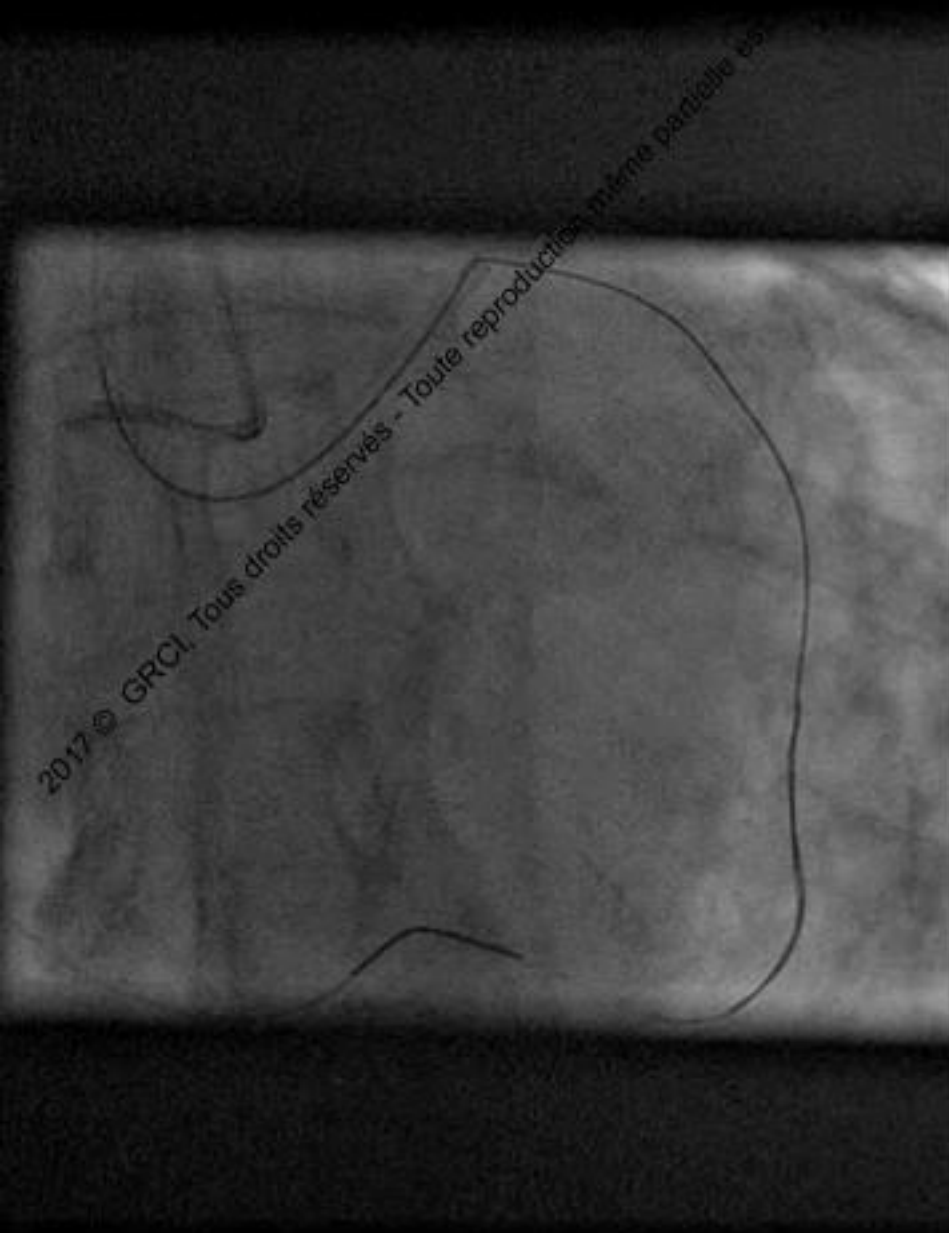
- 70 YO Gentelman
- MI 10 years ago with BMS on RCA
- DM, Dyslipidemia
- MIBI : inferior MI with infero-lateral and anteroapical ischemia.



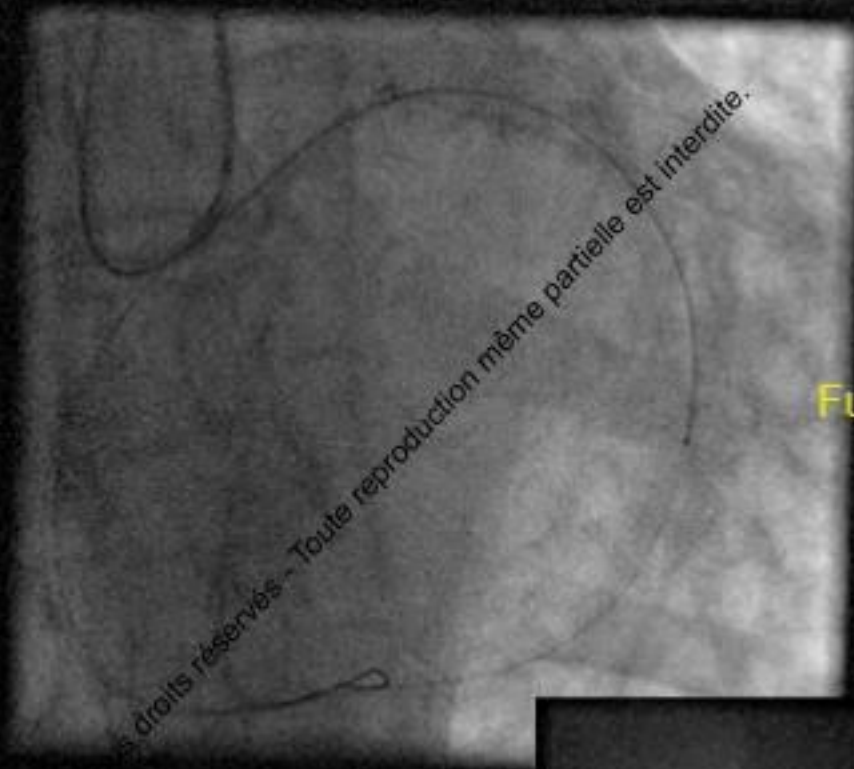
Toute reproduction même partielle est interdite

© 2017 GRCI, Tous droits réservés - Toute reproduction même partielle est interdite

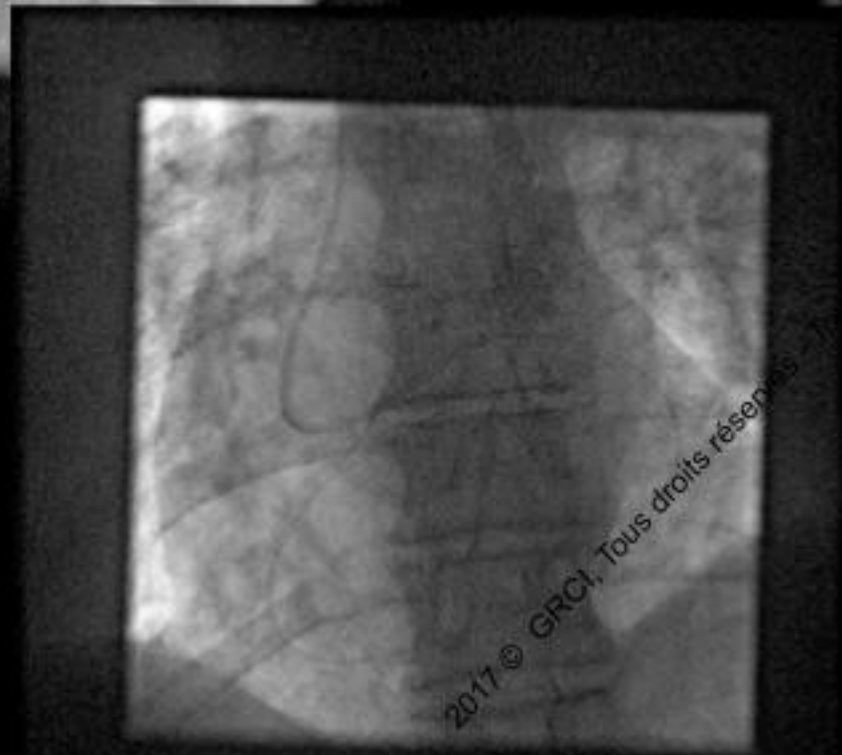
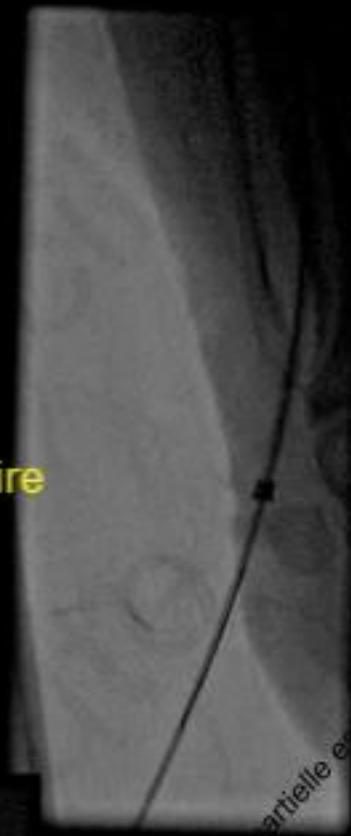







Fully externalized 0.14' wire



Tous droits réservés - Toute reproduction même partielle est interdite.

2017 © GRCI, Tous droits réservés

# Coronary Intervention

Failure of crossing with :  
-Finecross (despite twisting...)  
-Tazuna® 1.25x10mm  
-Across CTO® 1.1x10mm

Tous droits réservés - Toute reproduction même partielle est interdite.

2017 © GRCI, Tous droits réservés - Toute reproduction même partielle est interdite.

# Coronary Intervention

## Reverse anchoring balloon technique

Emerge® 2.5x20mm  
trapping the

Fielder® FC retrograds

Toute reproduction même partielle est interdite

Despite reverse anchoring  
balloon !  
Failure of anterograde crossing with

- Tazuna® 1.25x10mm
- Across CTO® 1.1x15mm

2017 © GRCI, Tous droits réservés - Toute reproduction même partielle est interdite



# Coronary Intervention

Tous droits réservés - Toute reproduction même partielle est interdite.

## Failure of anterograde crossing with :

-Tazuna® 1.25x10mm

-Across CTO® 1.1x10mm

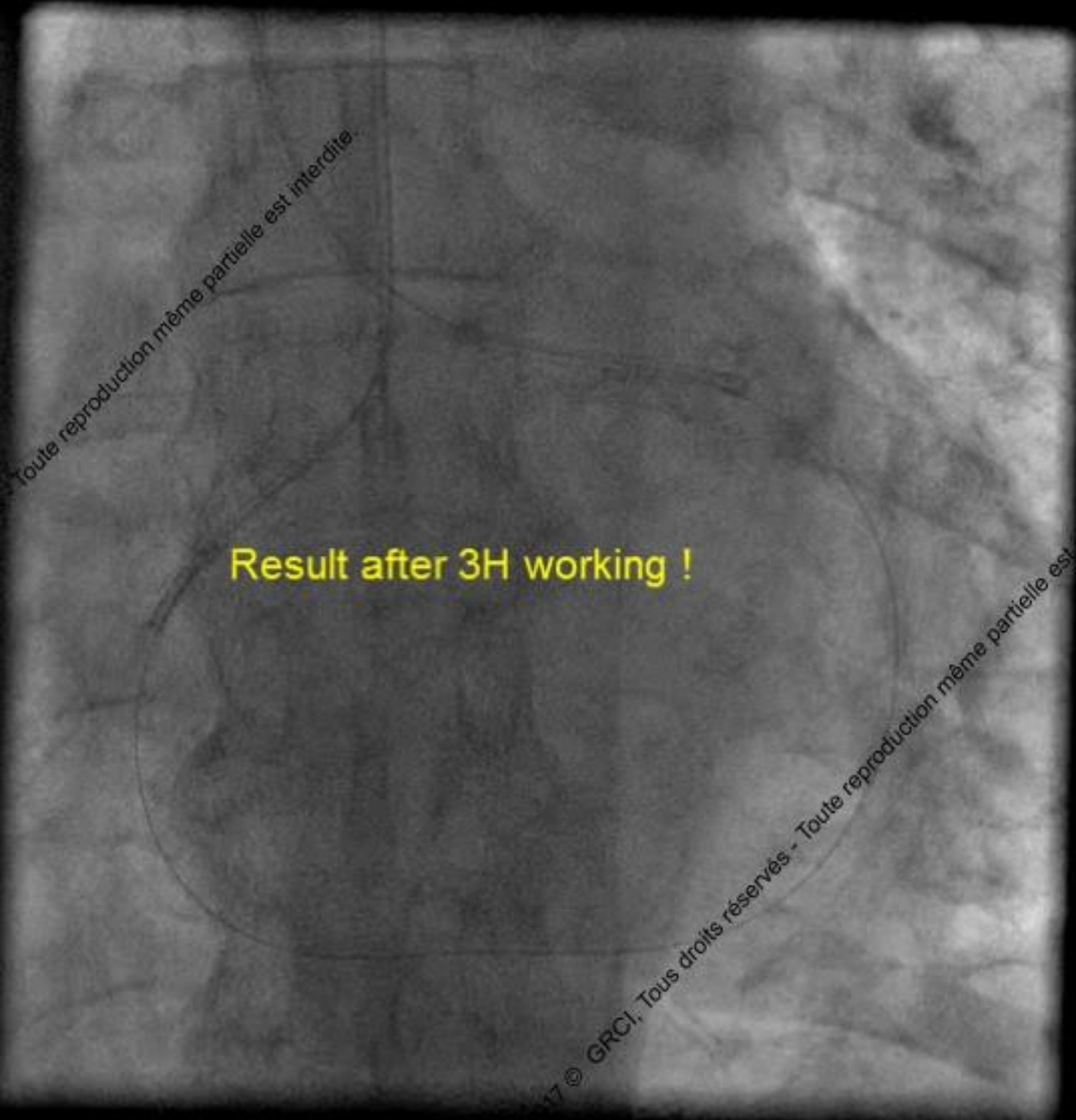Despite inflations, «reptation technique», «grenade technique»...



Tous droits réservés - Toute reproduction même partielle est interdite.

2017 © GRCI, Tous droits réservés - Toute reproduction même partielle est interdite.



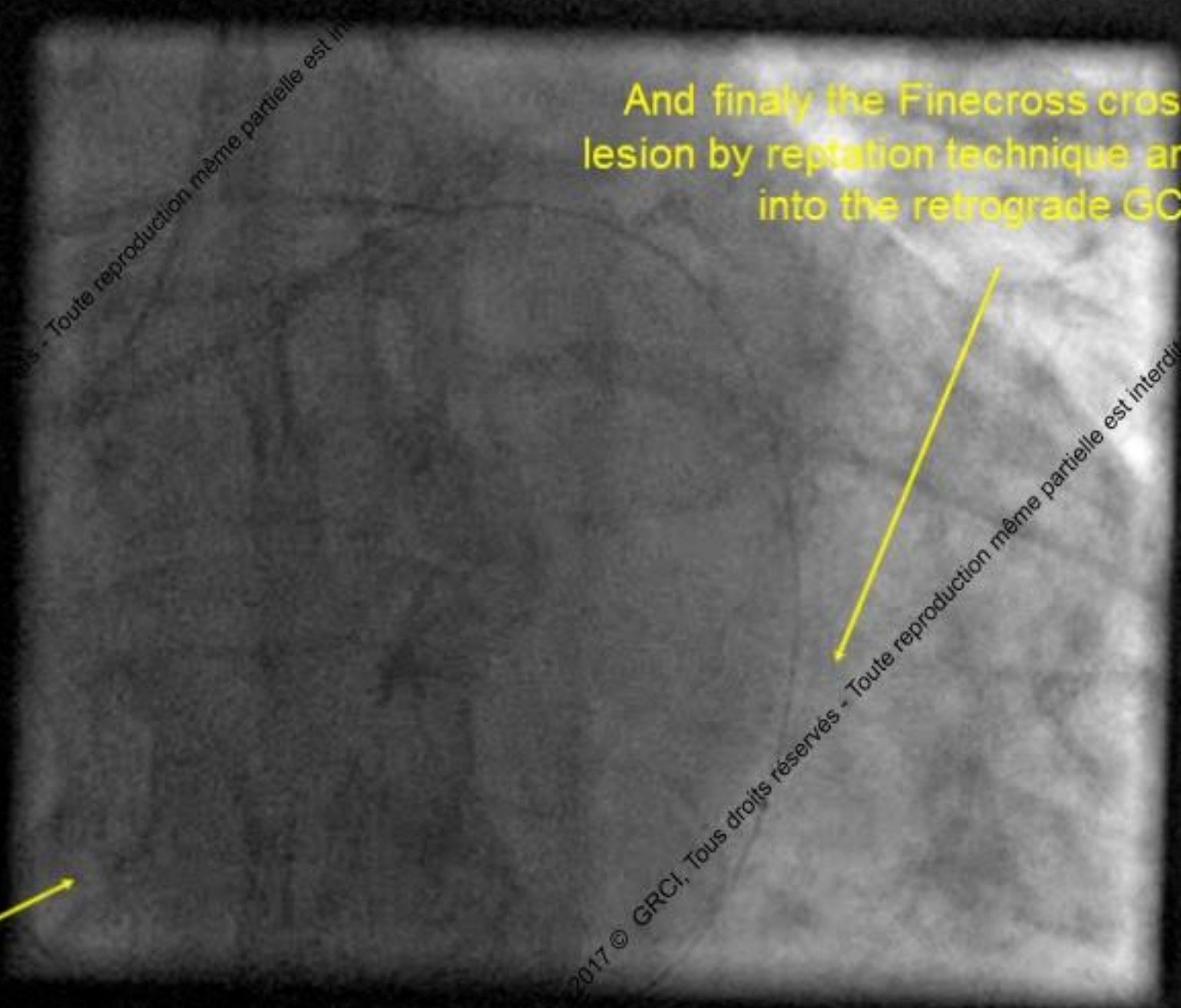


**Result after 3H working !**

© GRCI, Tous droits réservés - Toute reproduction même partielle est interdite.

Barbeau  
deep  
intubation

And finally the Finecross crossed the  
lesion by reptation technique and jumped  
into the retrograde GC



Toute reproduction même partielle est interdite

Toute reproduction même partielle est interdite

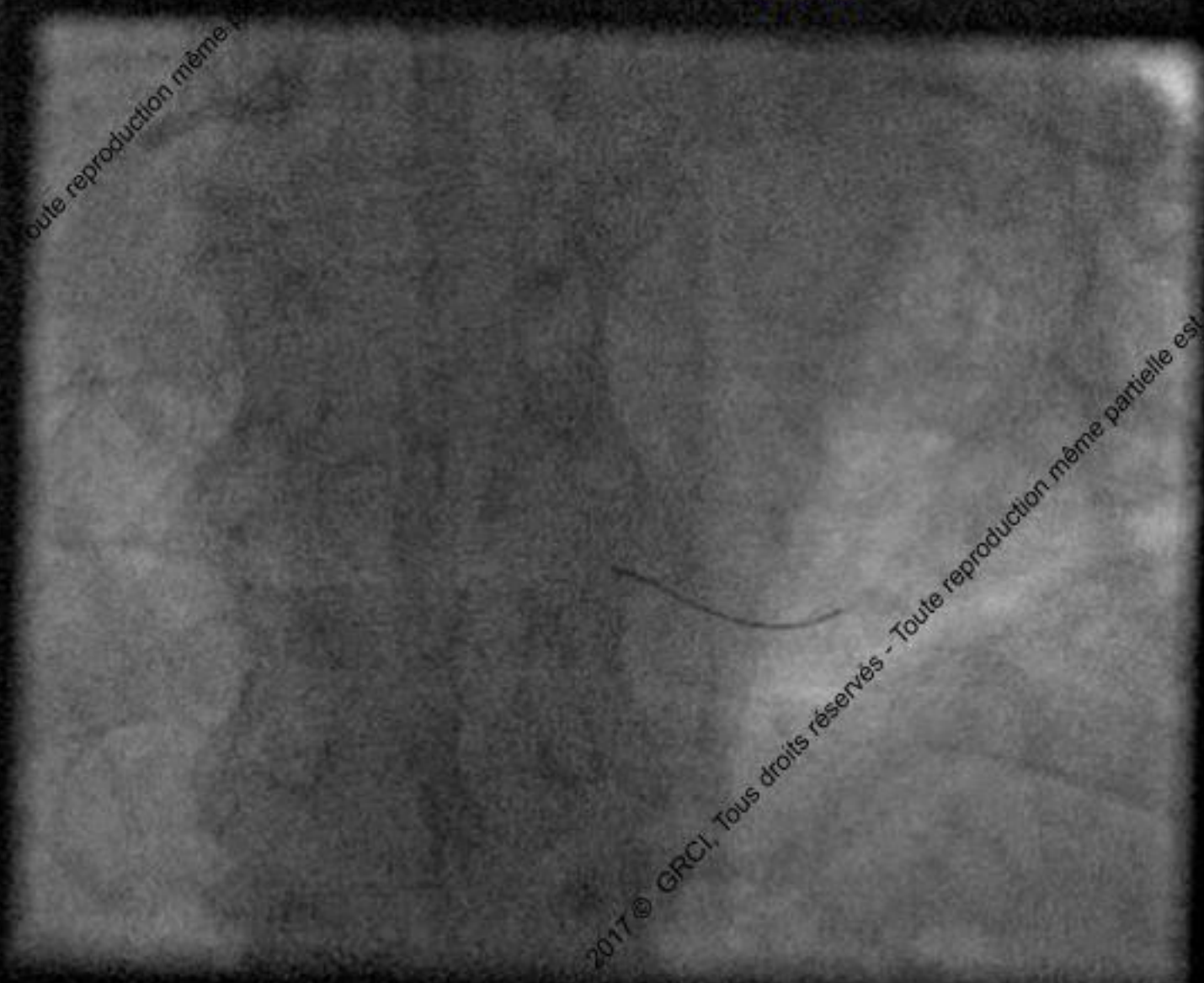
© 2017 GRCI, Tous droits réservés

# Coronary Intervention

**Fielder® FC 300cm was exchange through the Finecross®  
for a Rotawire Floppy®**



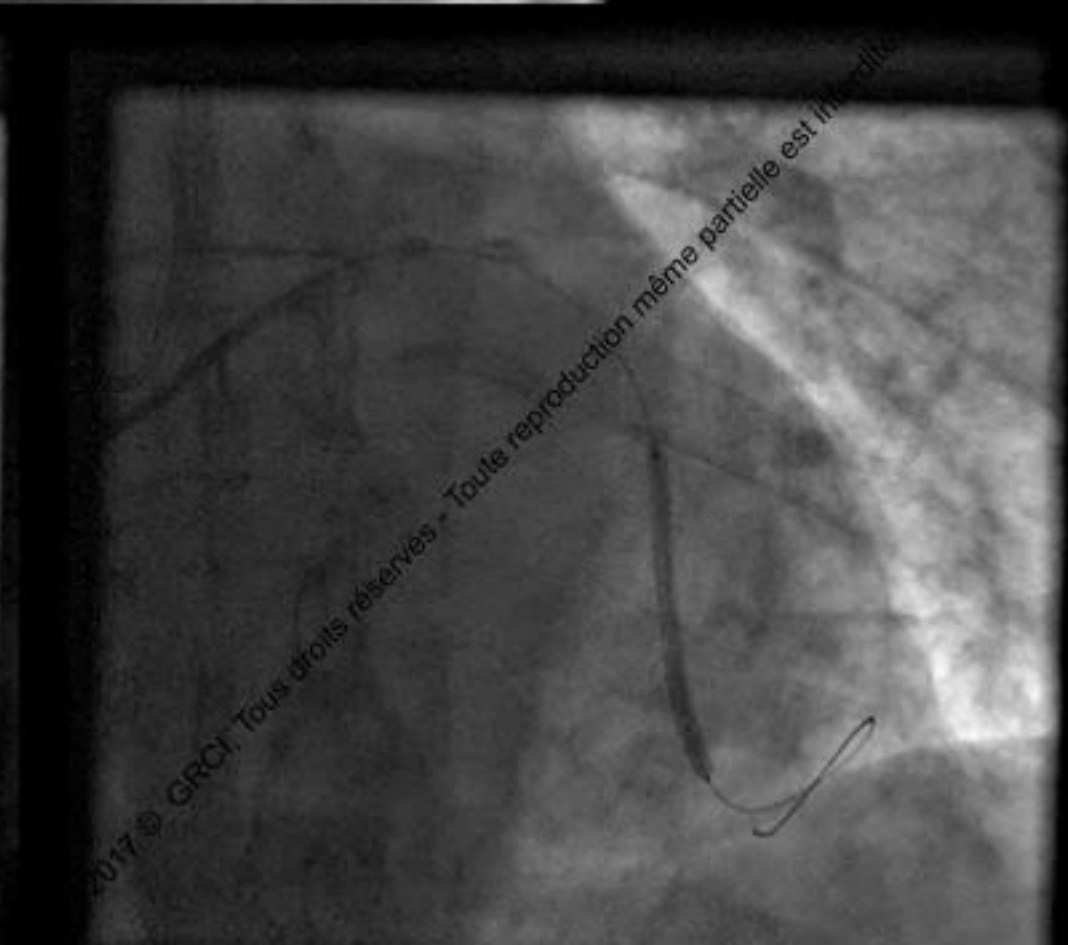
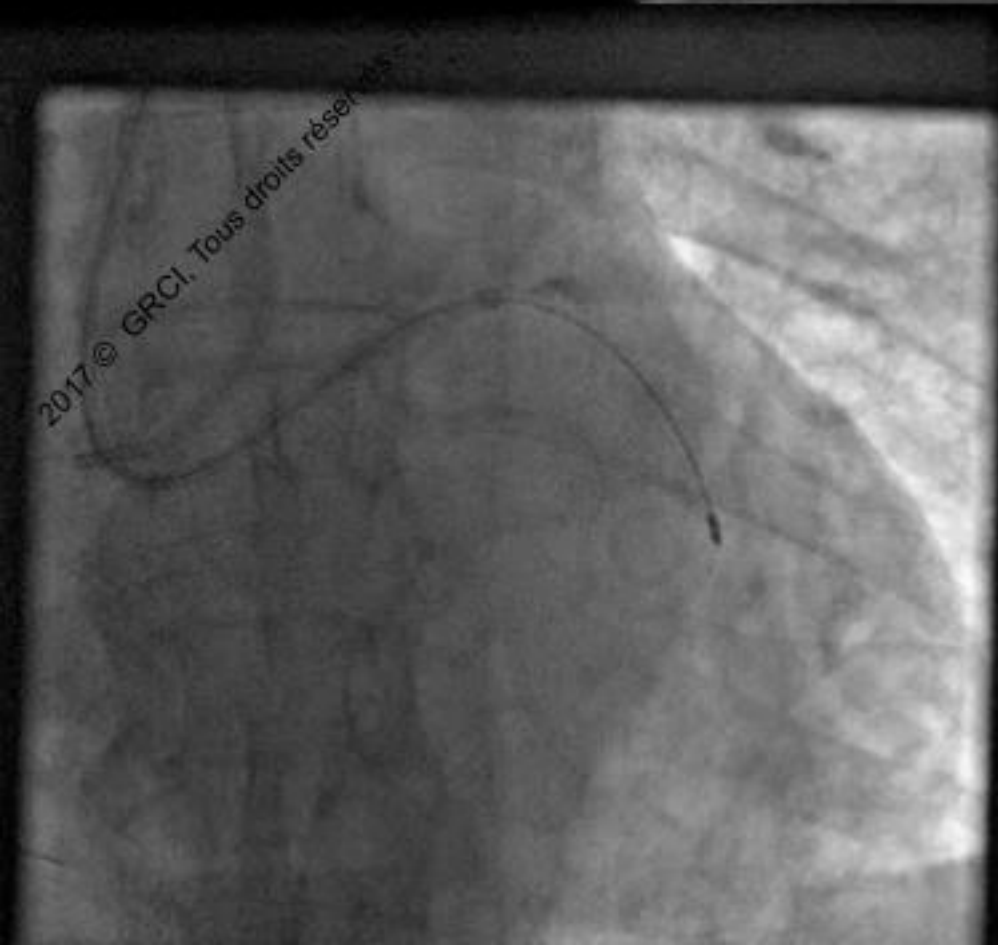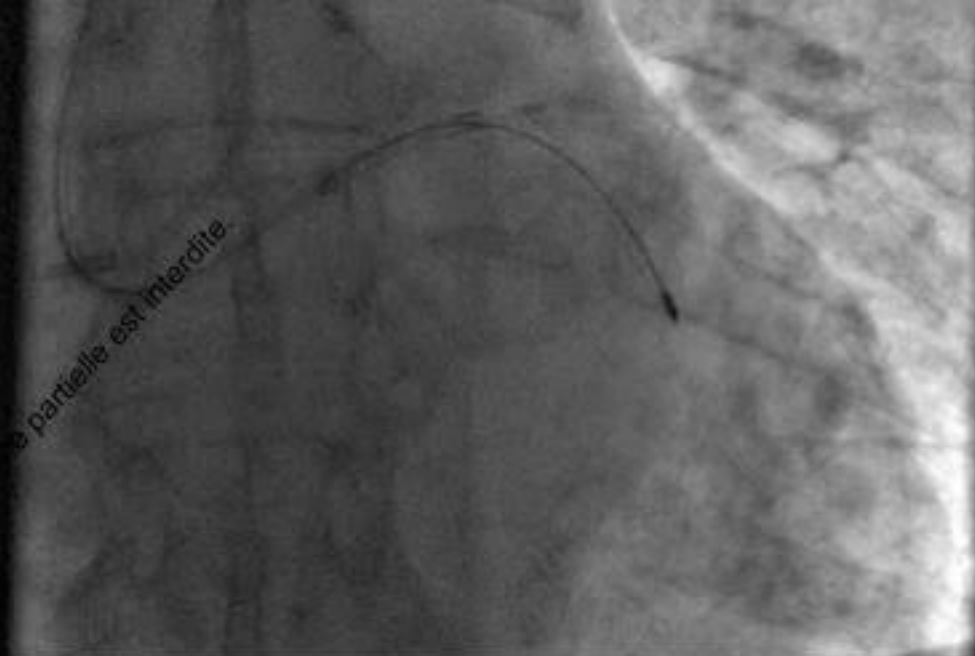# Fielder® FC 300cm was exchange through the Finecross® for a Rotawire Floppy®

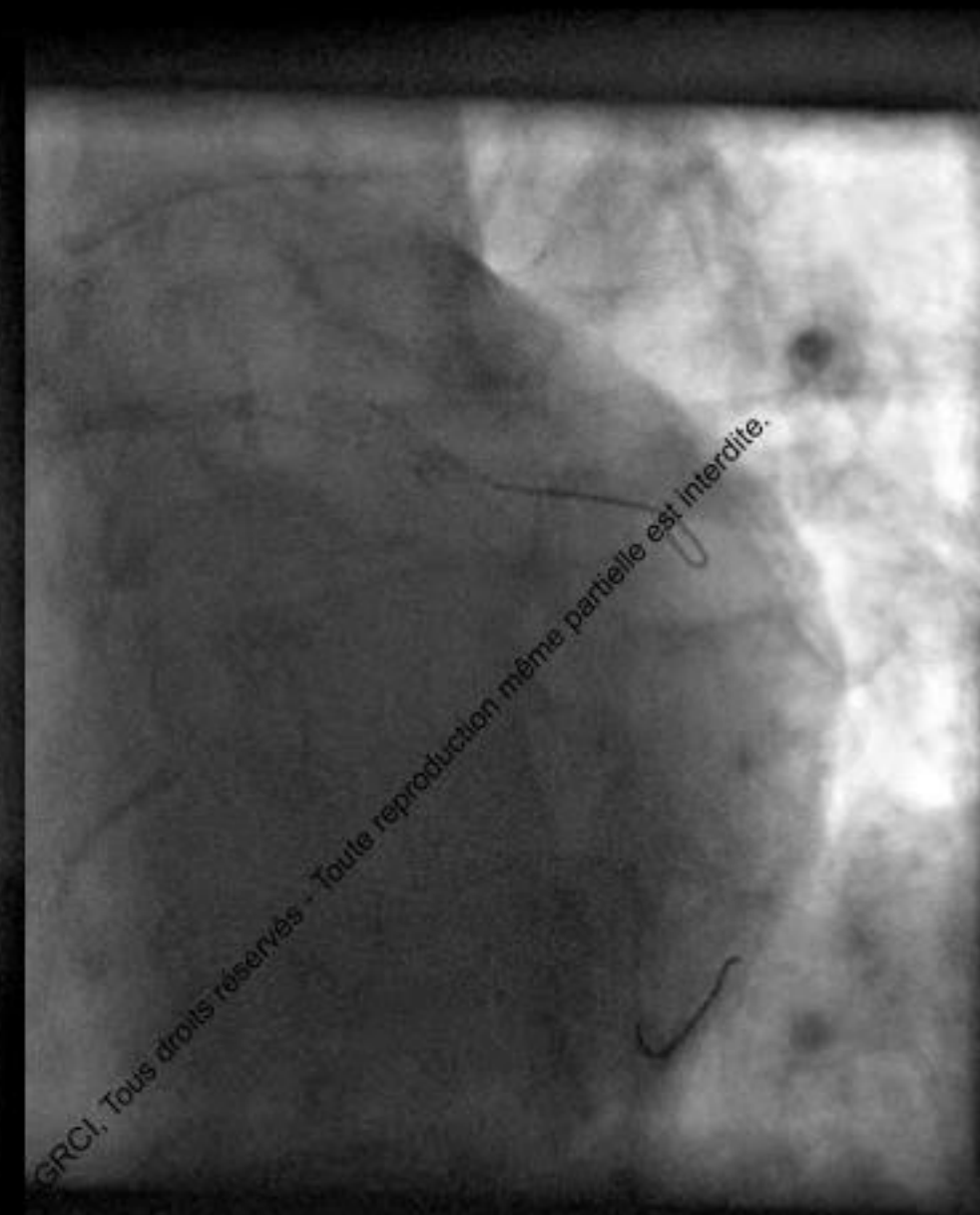
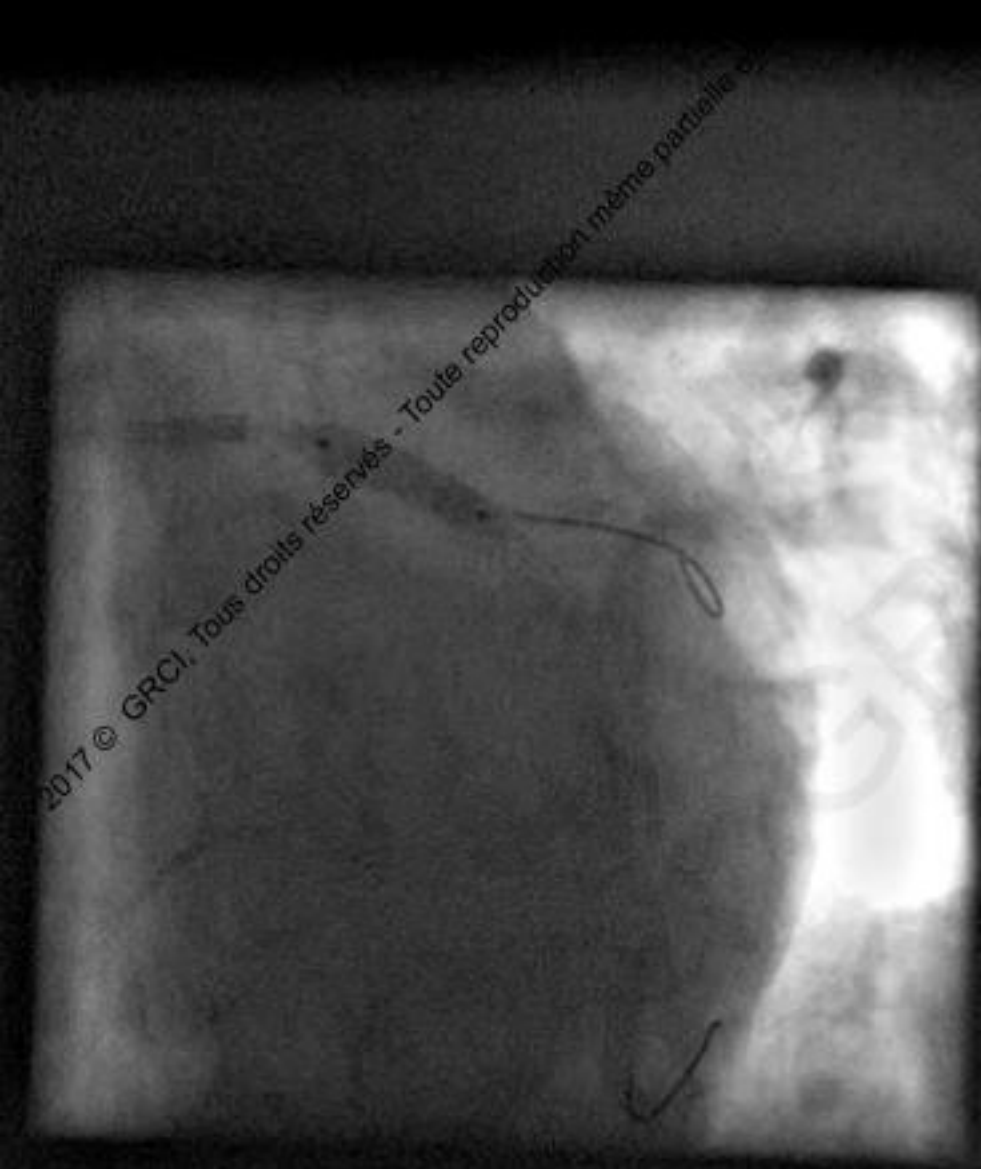

Toute reproduction même partielle est

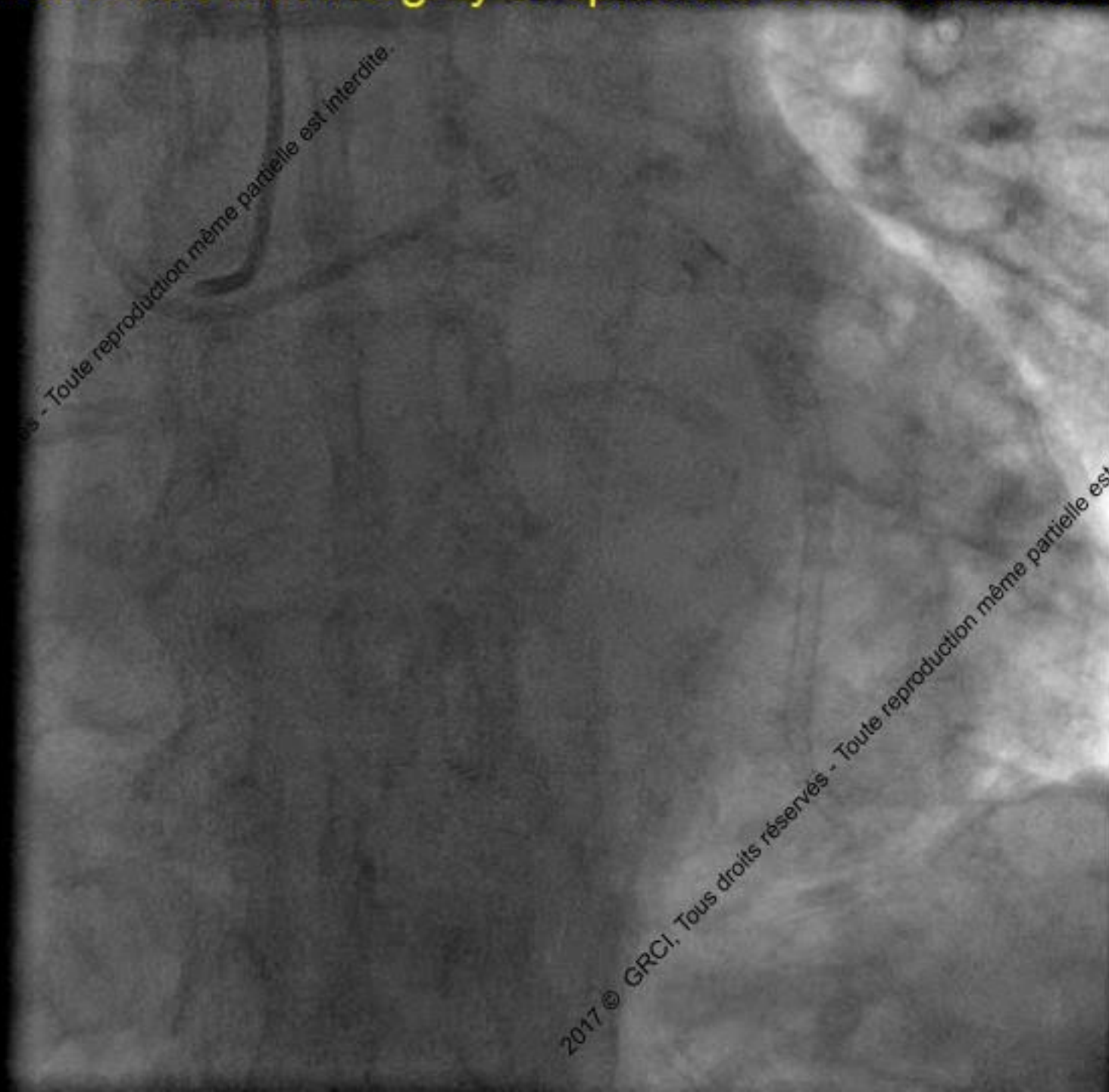
2017 © GRCI, Tous droits réservés - Toute reproduction même partielle est





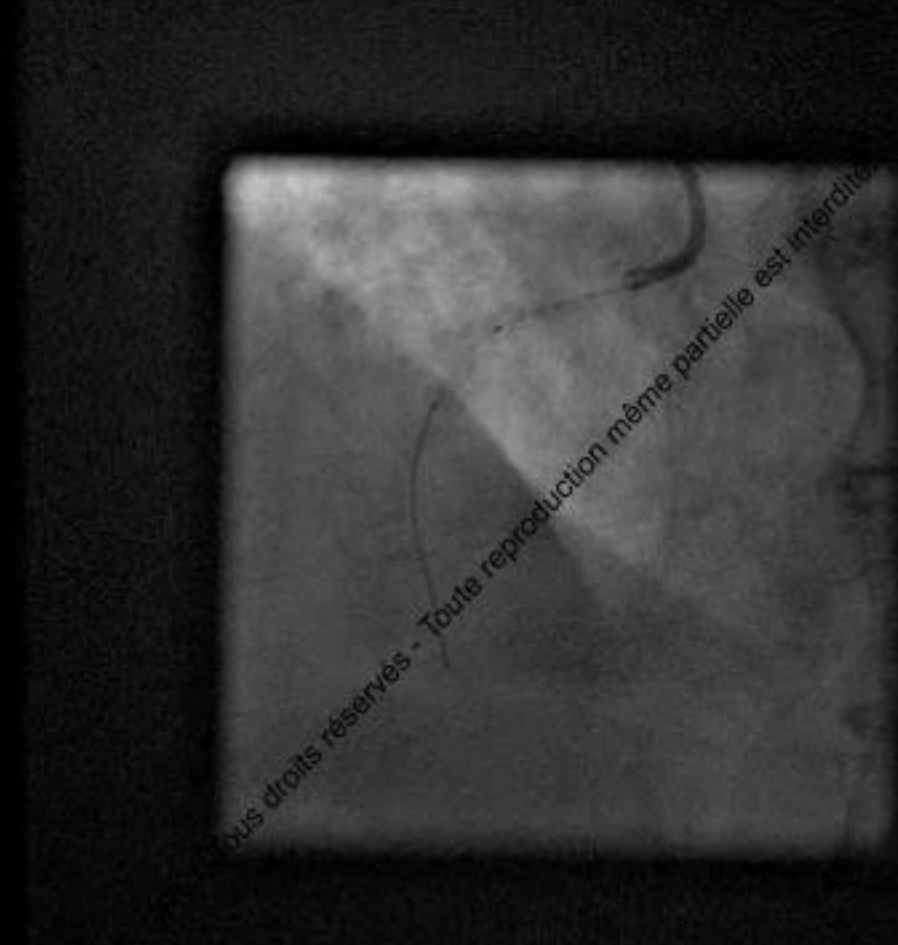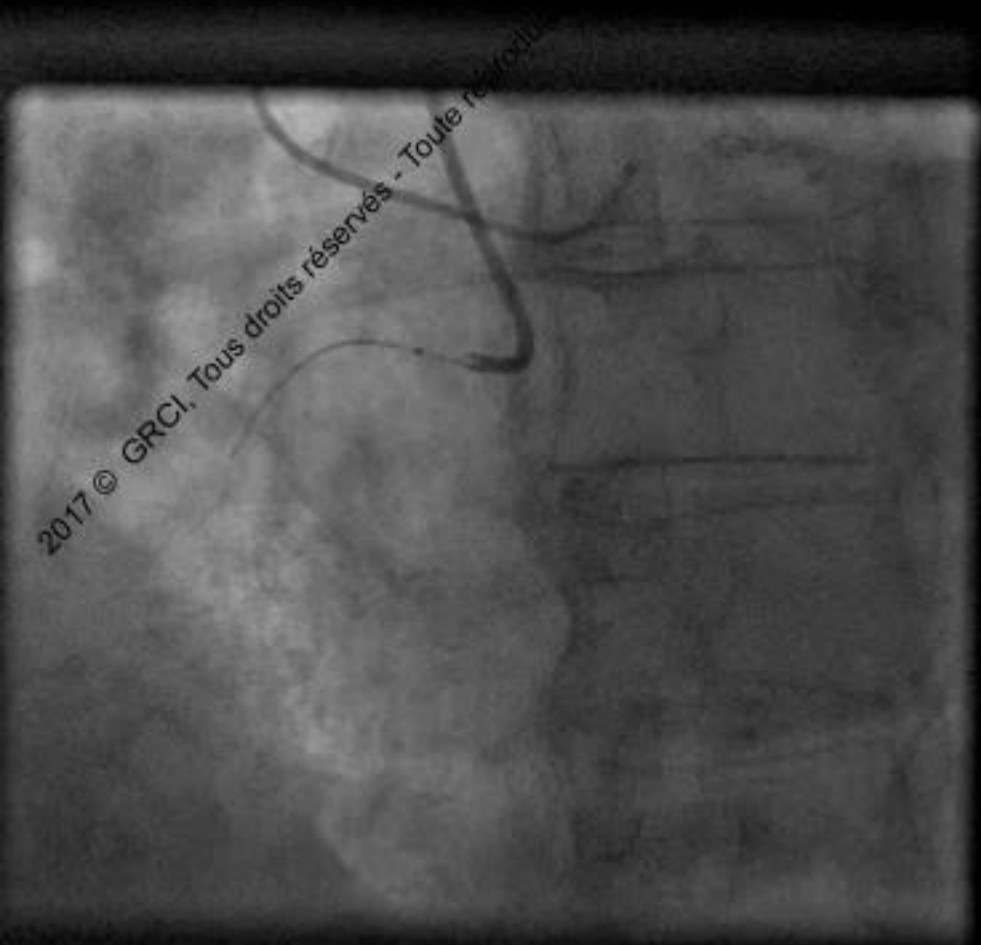


## Final result with integrity of epicardic collateral branch



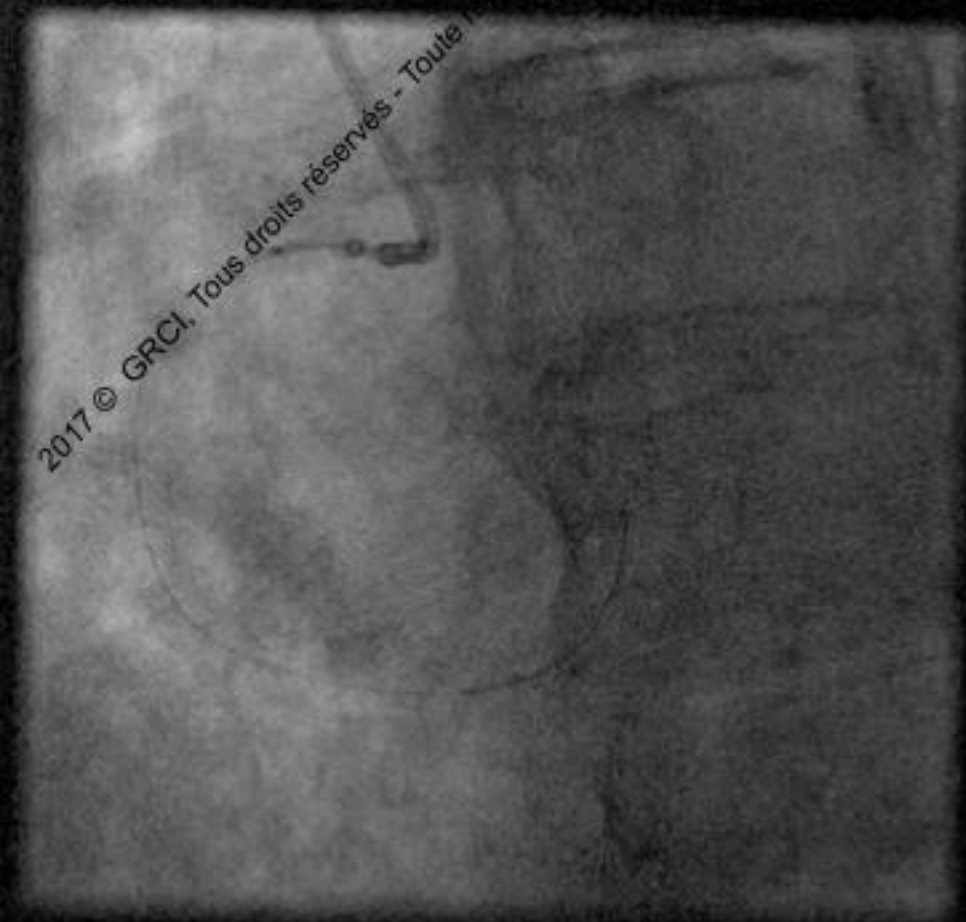


# Nothing but a wire can cross

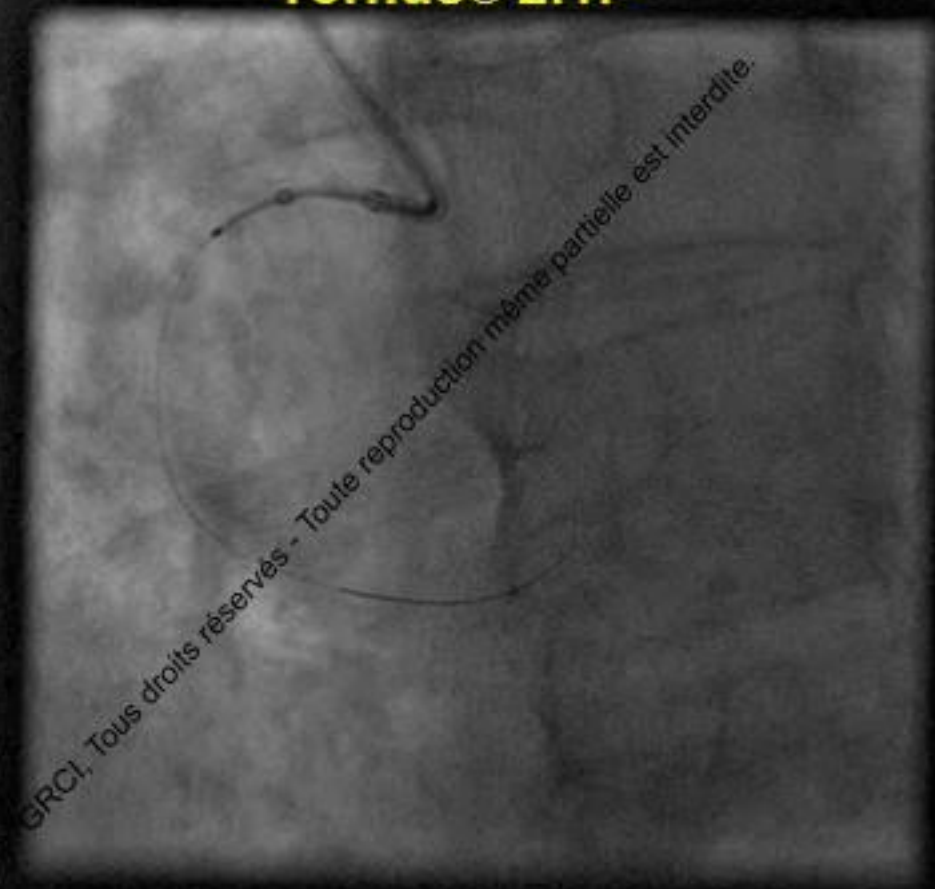




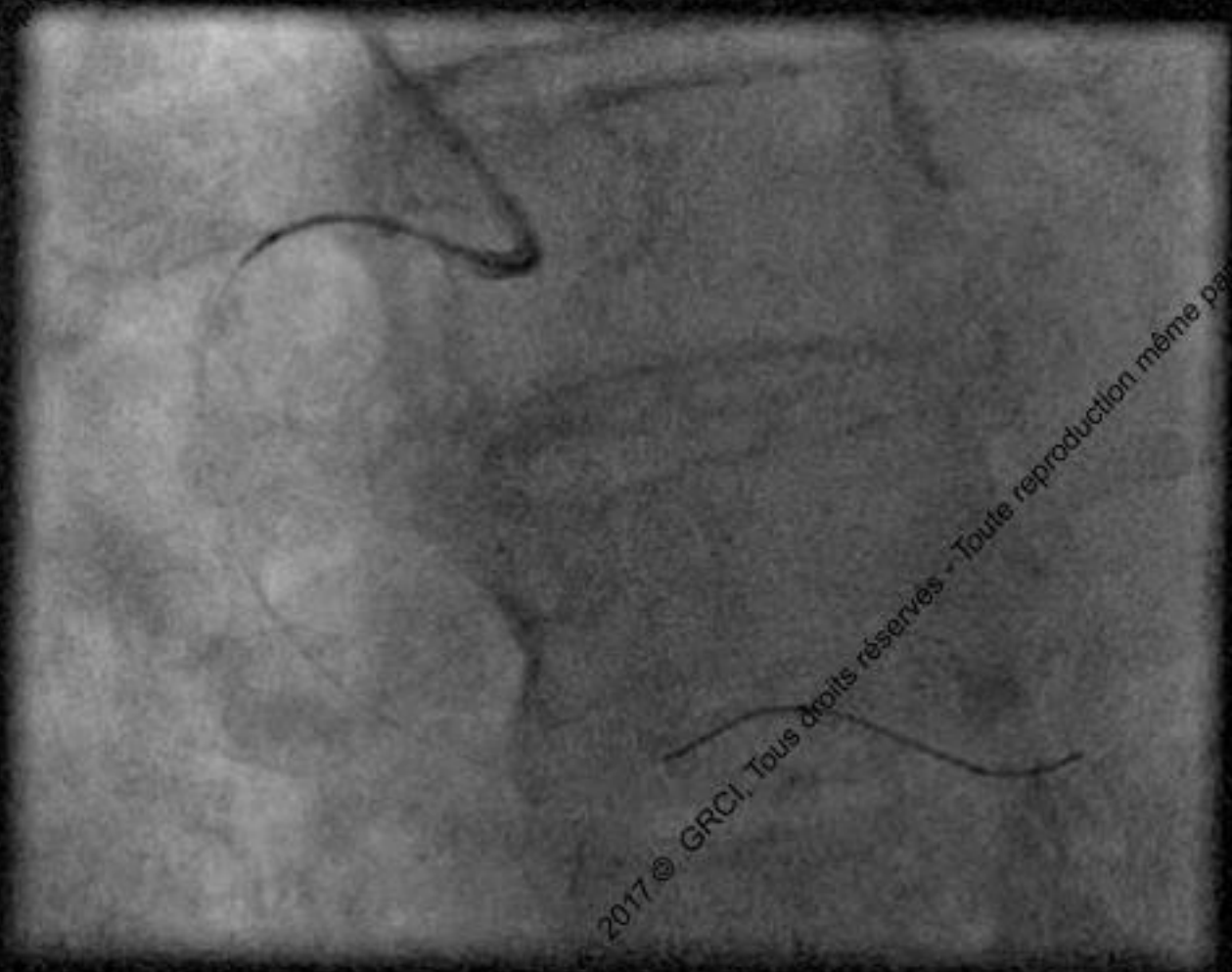
# Nothing but a wire can cross



**Tornus® 2.1F**

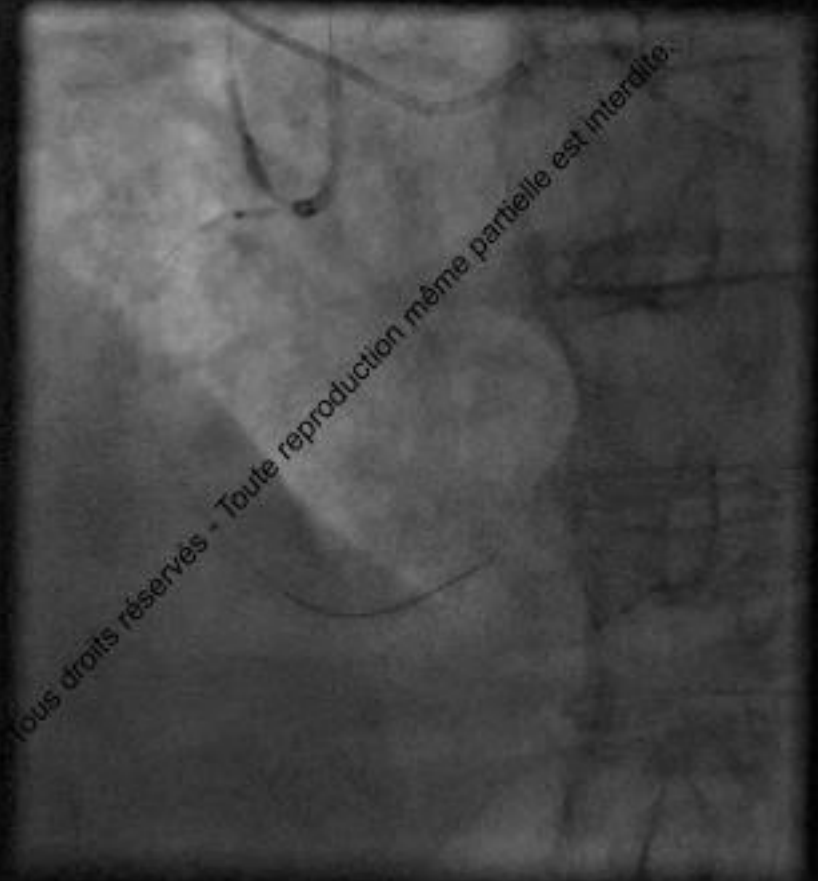
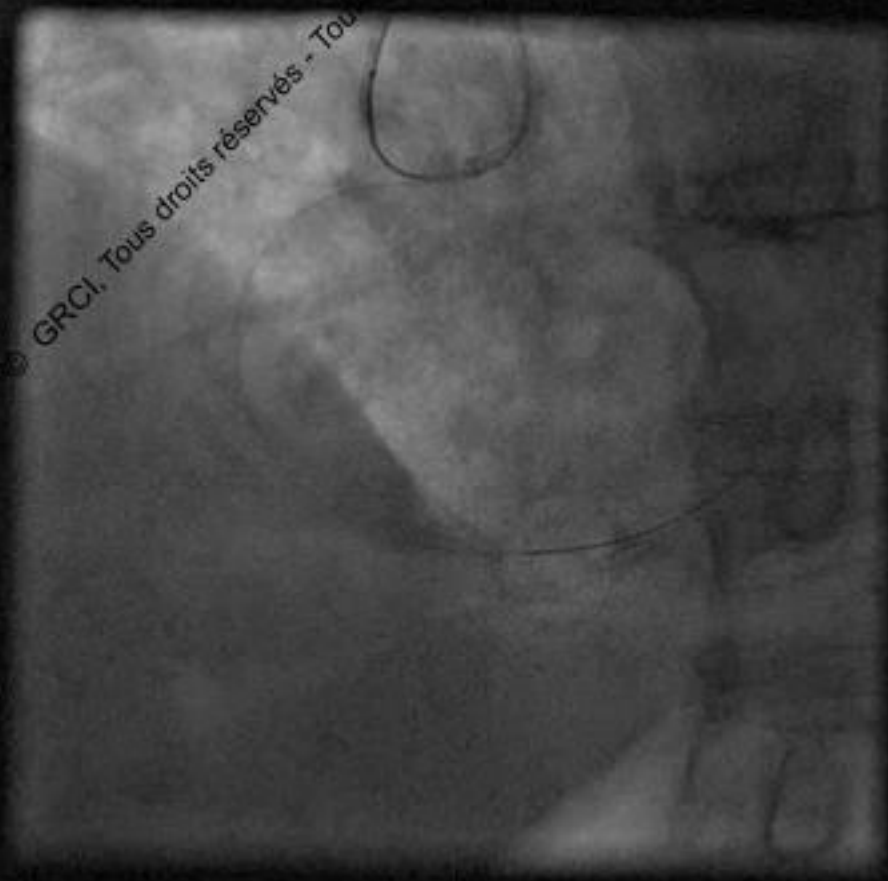


# Nothing but a wire can cross



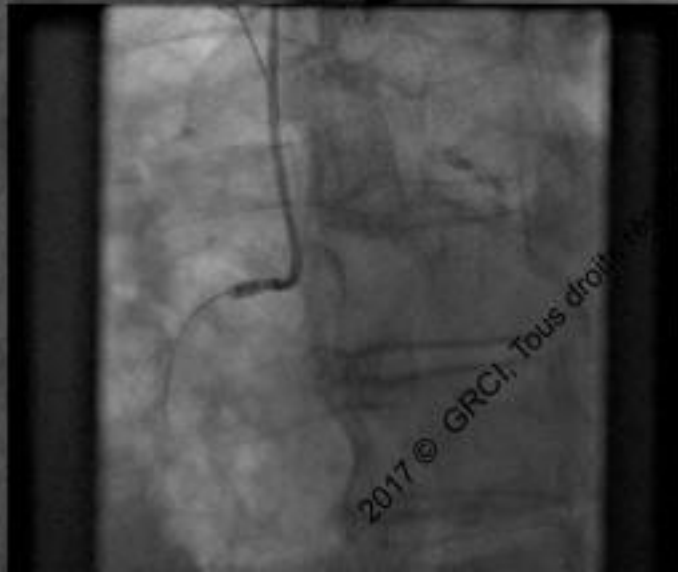
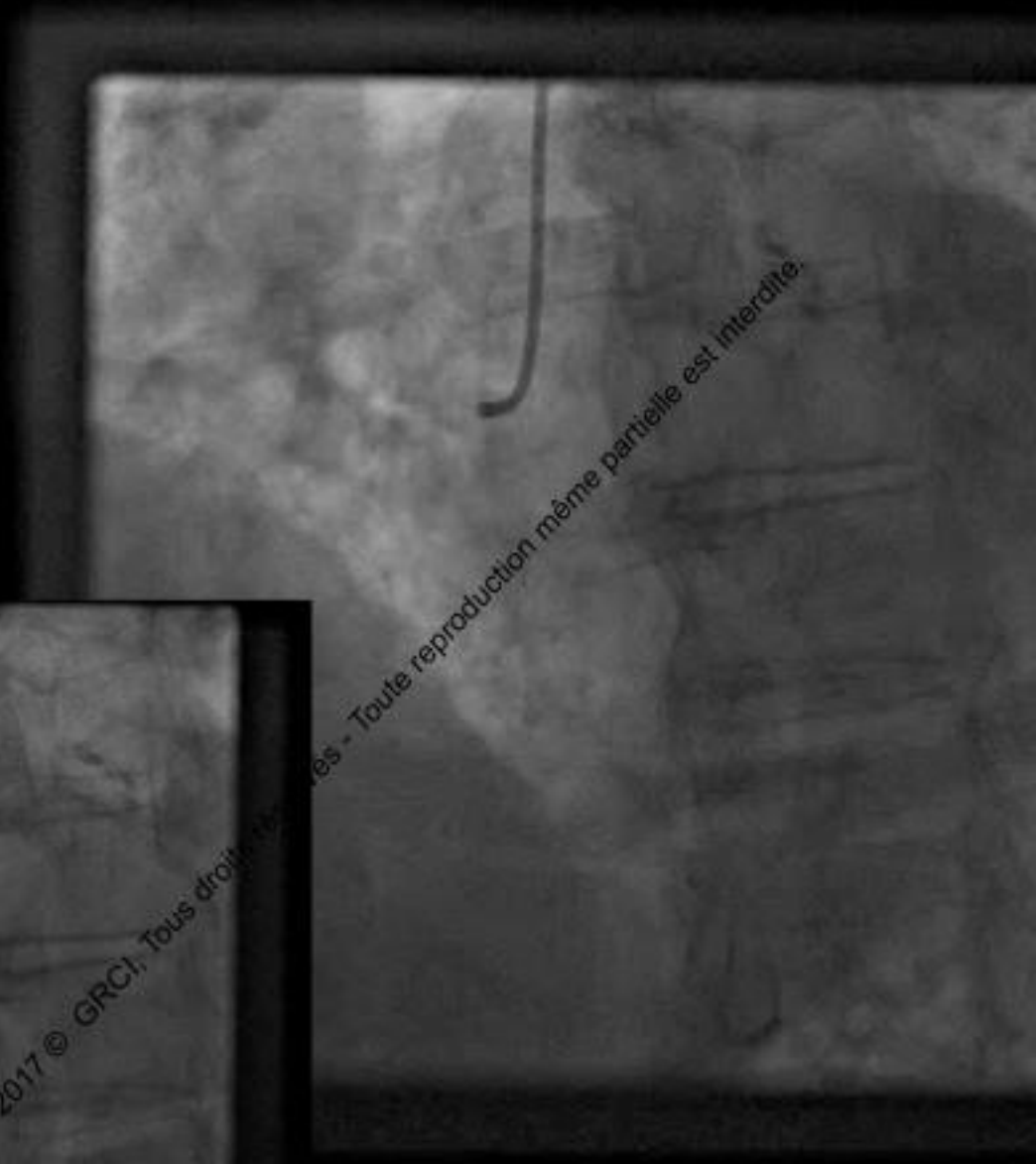
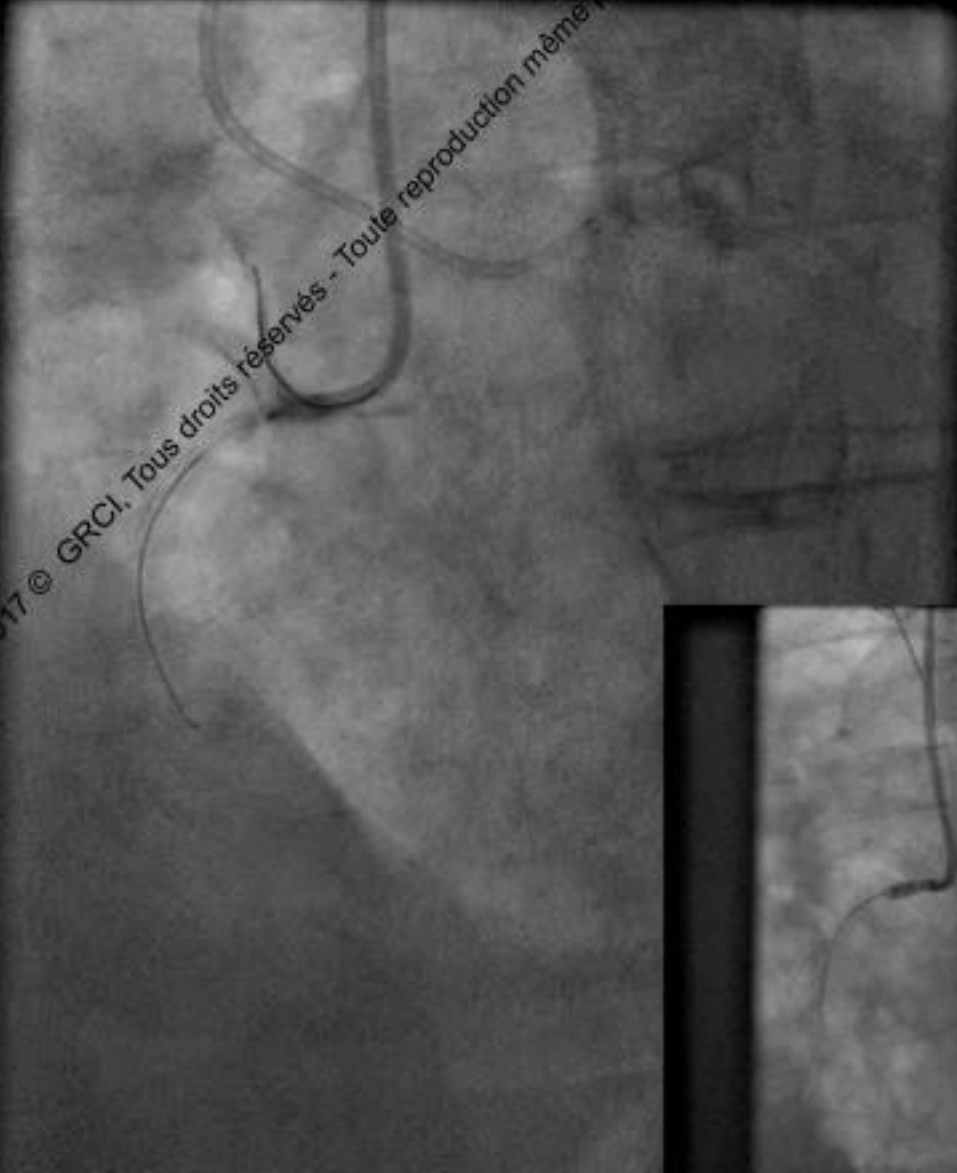# Nothing but a wire can cross

## Anchoring balloon





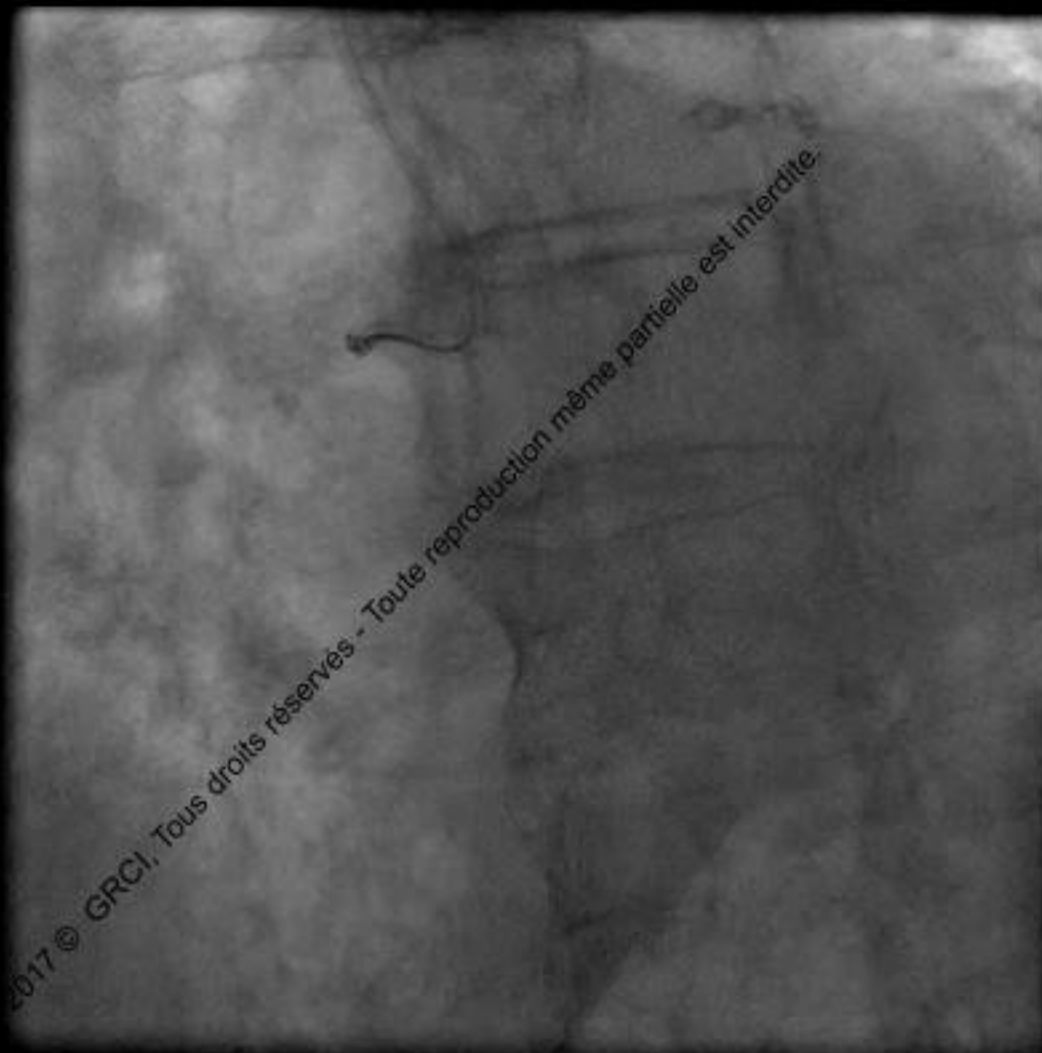
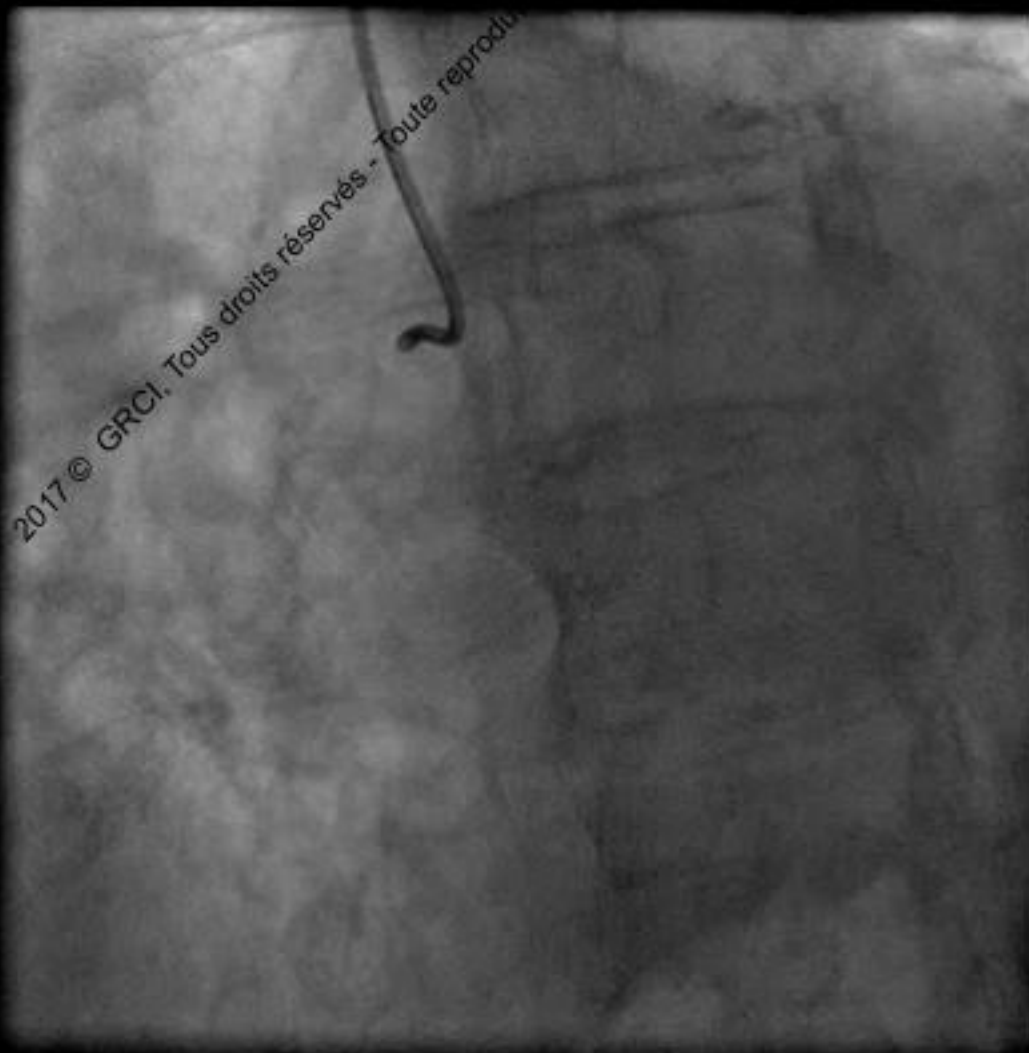
# Nothing but a wire can cross



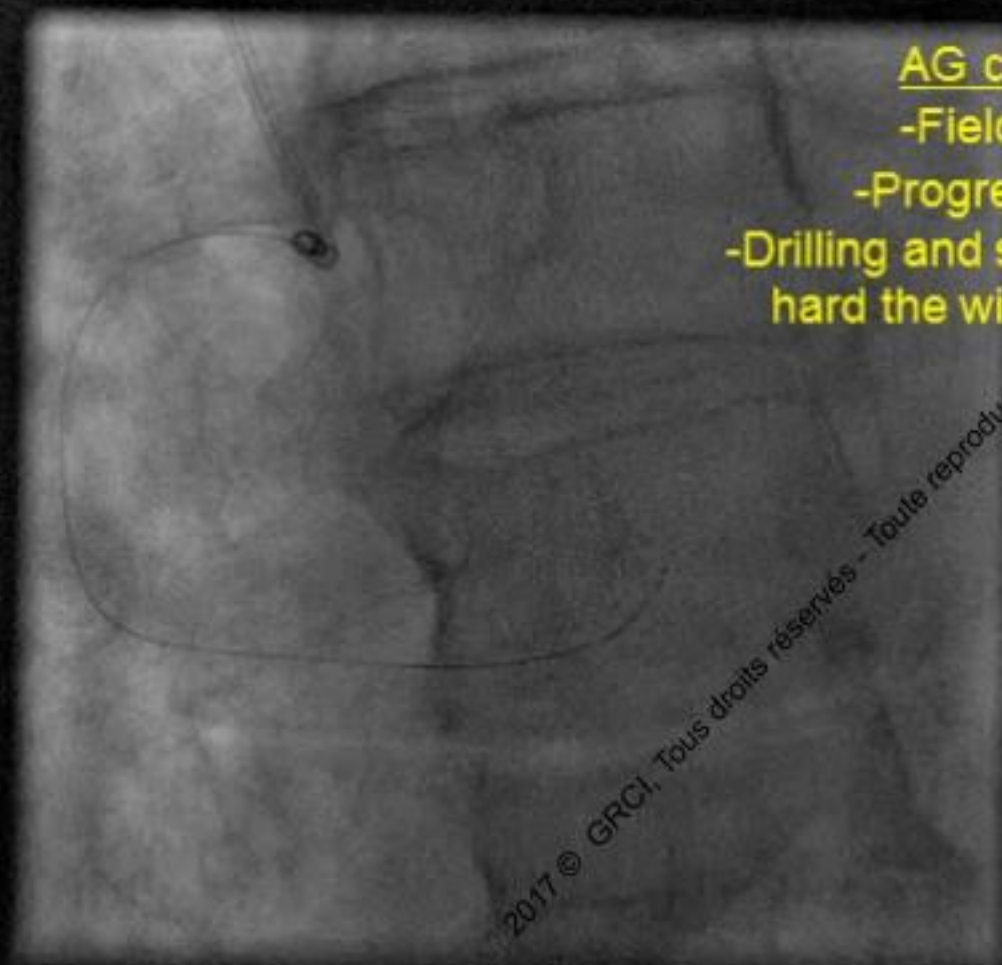


# Nothing but a wire can cross

2nd Procedure 6 week later



# Nothing but a wire can cross



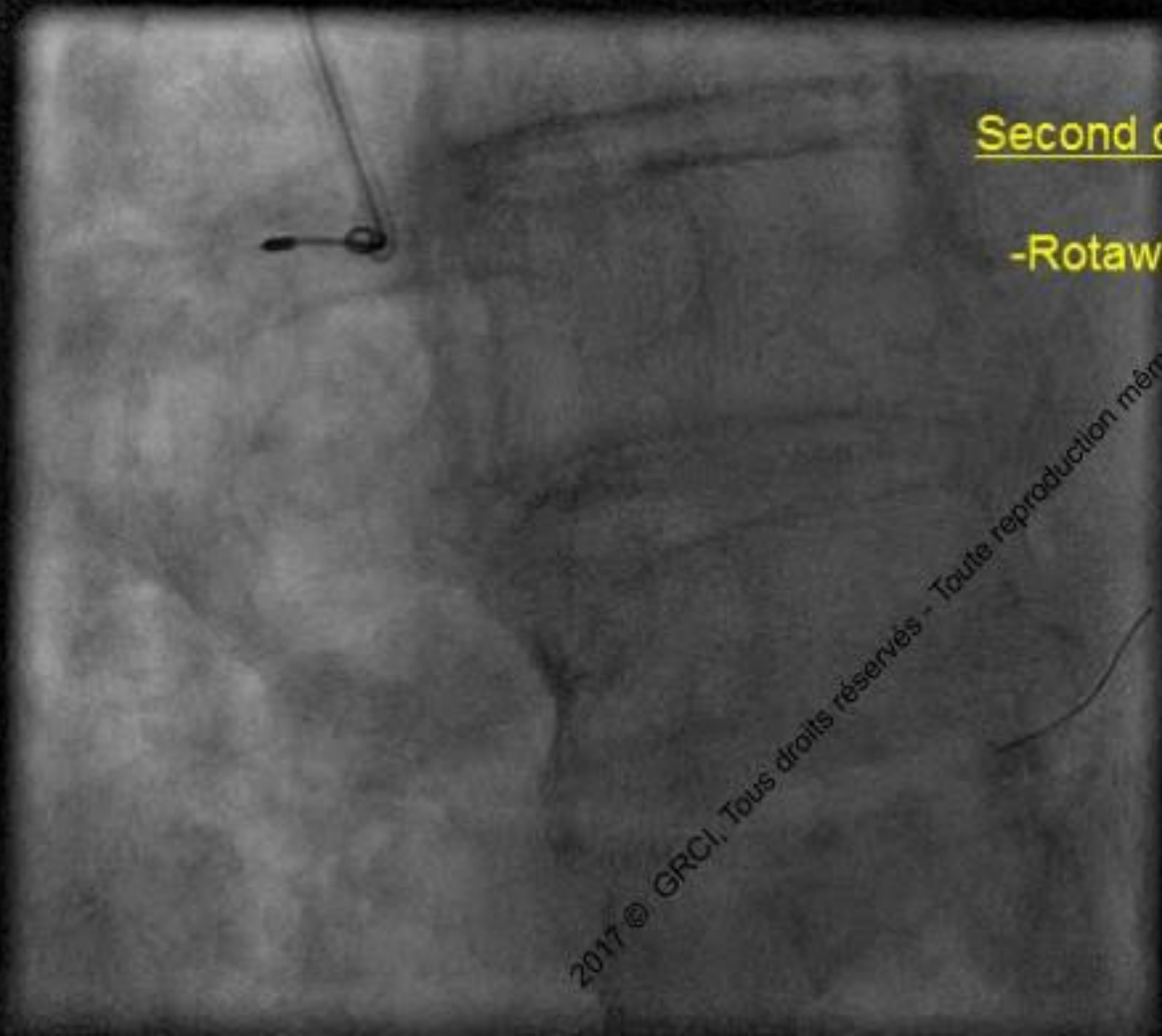AG crossing with :

-Fielder XT® then

-Progress 200T® then

-Drilling and spinning very fast and  
hard the wire by withdrawing it

# Nothing but a wire can cross

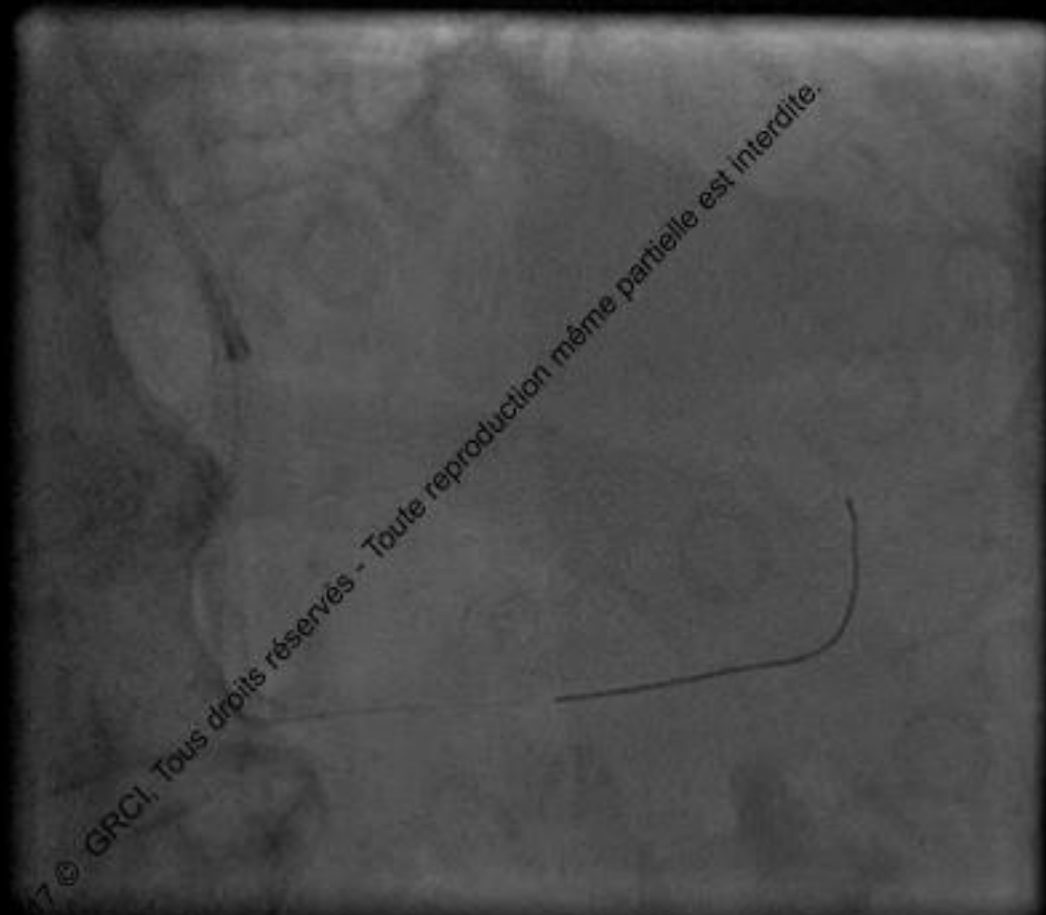
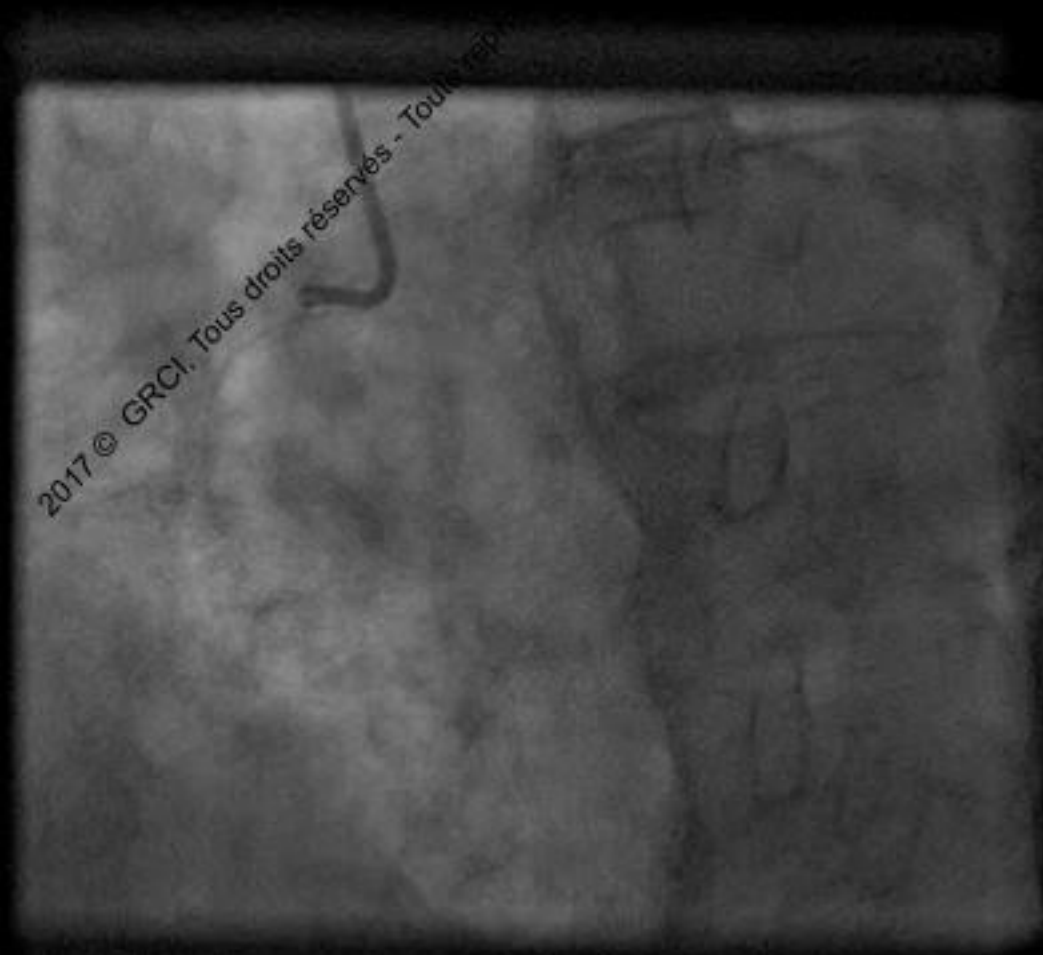


Second crossing with:

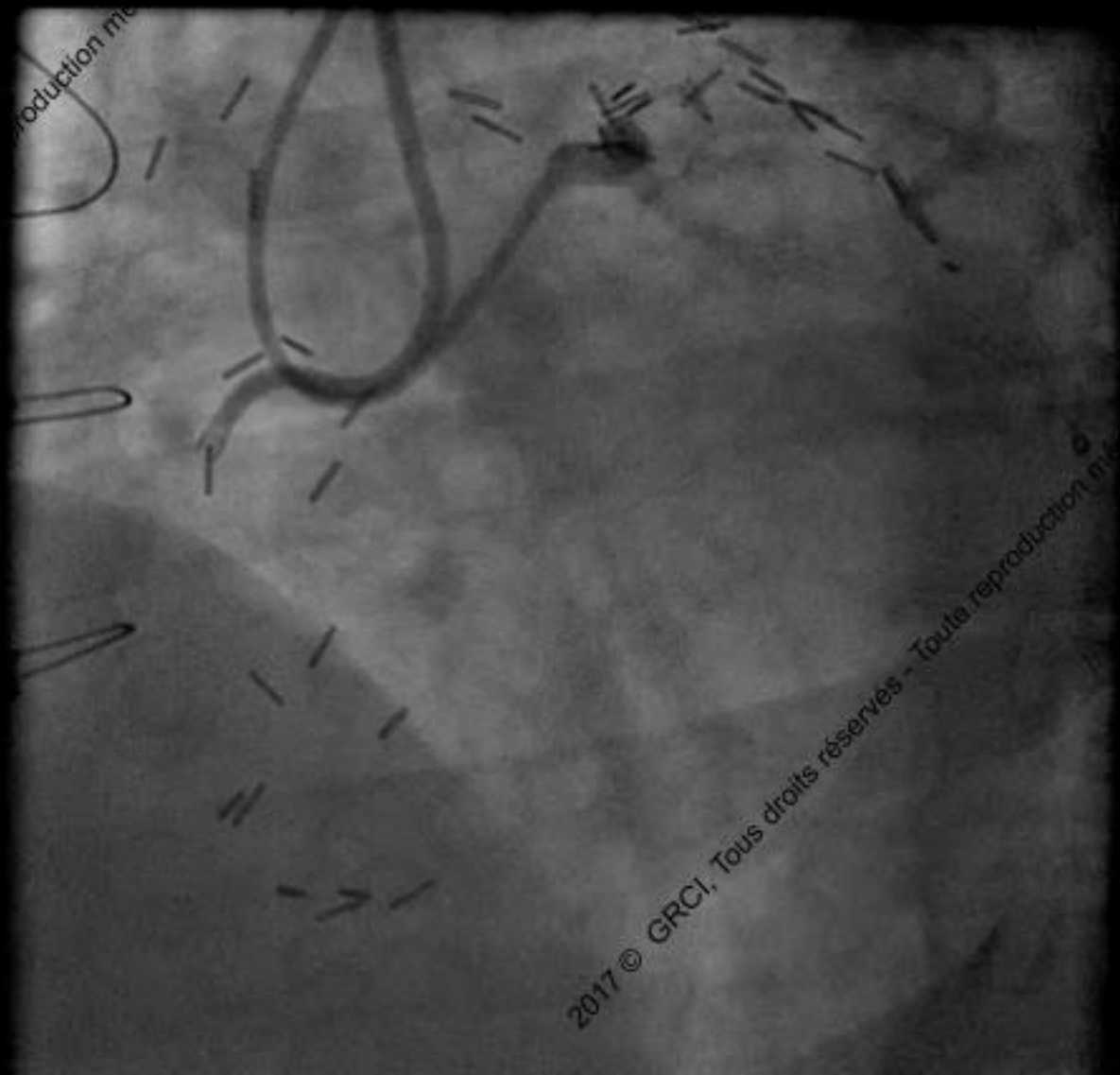
-Rotawire floppy ®



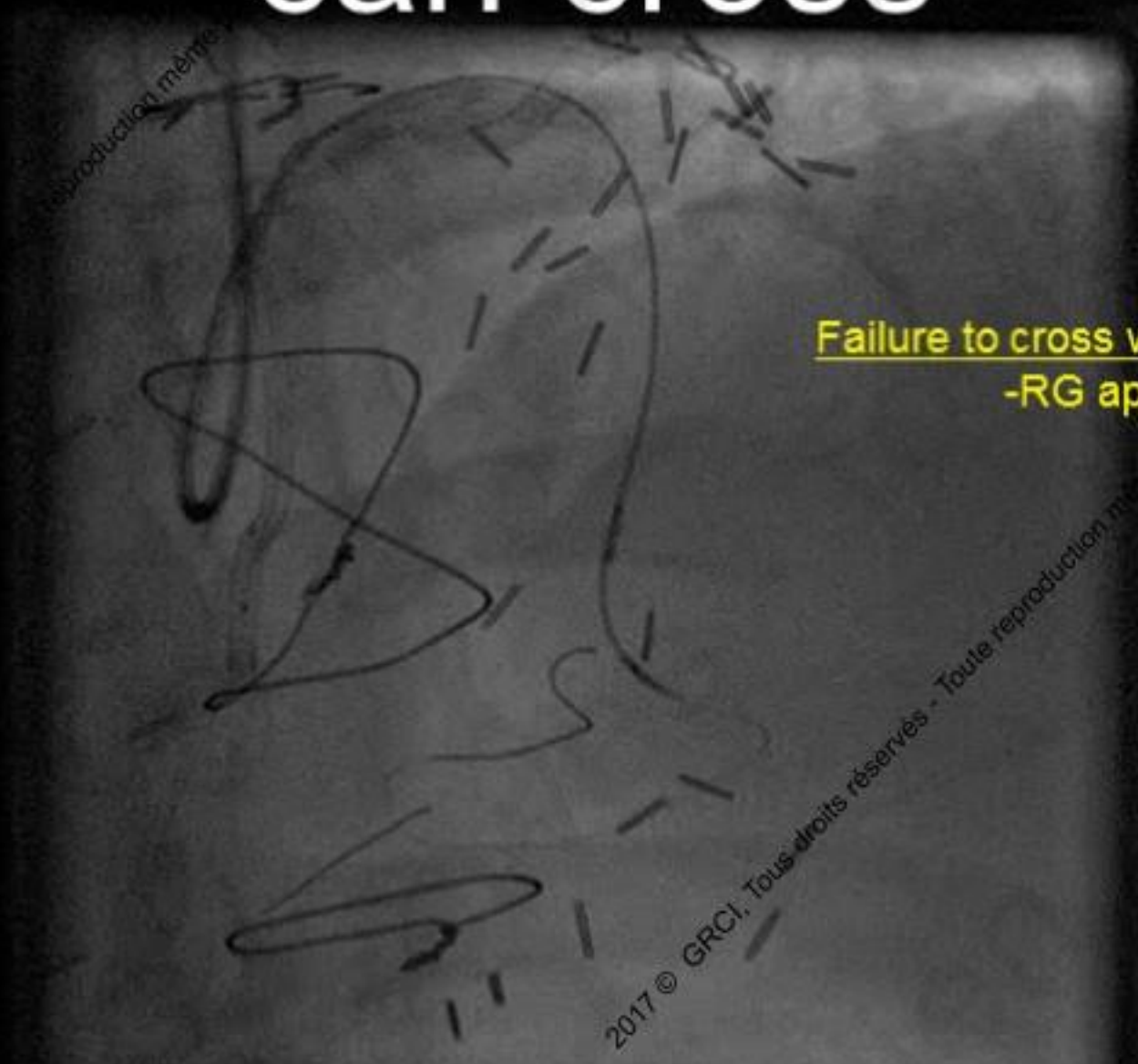
# Nothing but a wire can cross



# Nothing but a wire can cross



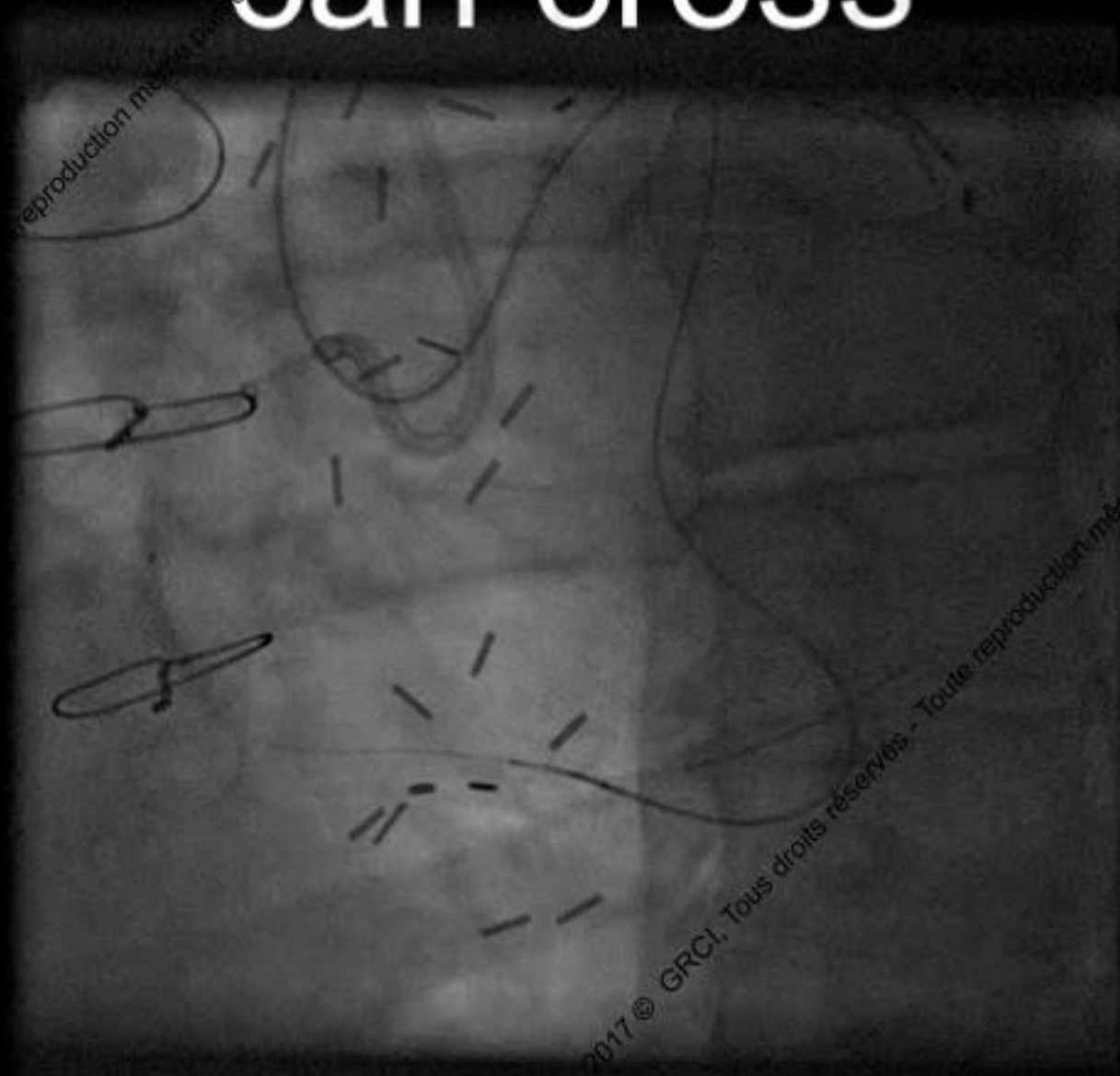
# Nothing but a wire can cross



Failure to cross with AG Devices :  
-RG approach

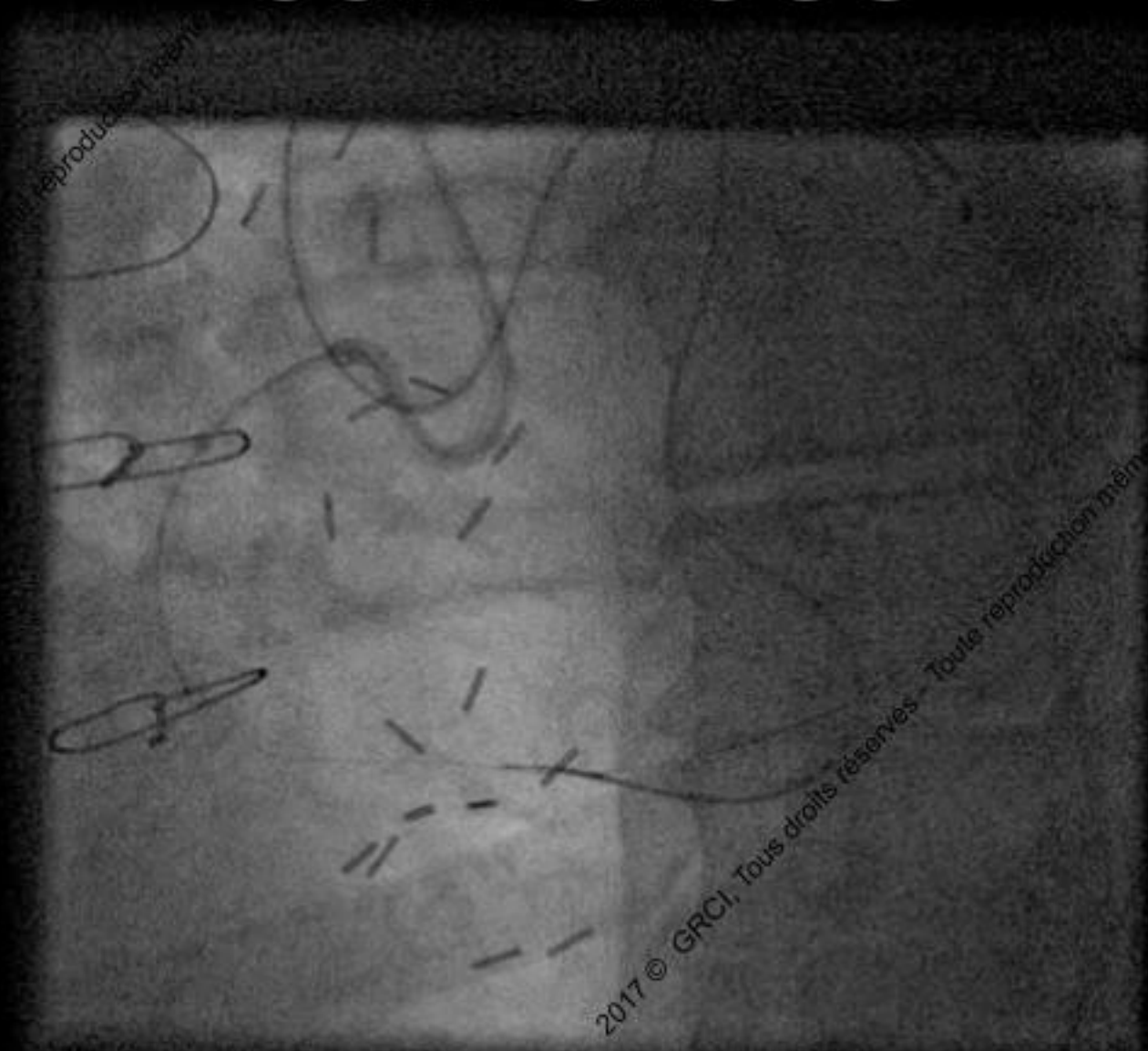

# Nothing but a wire can cross

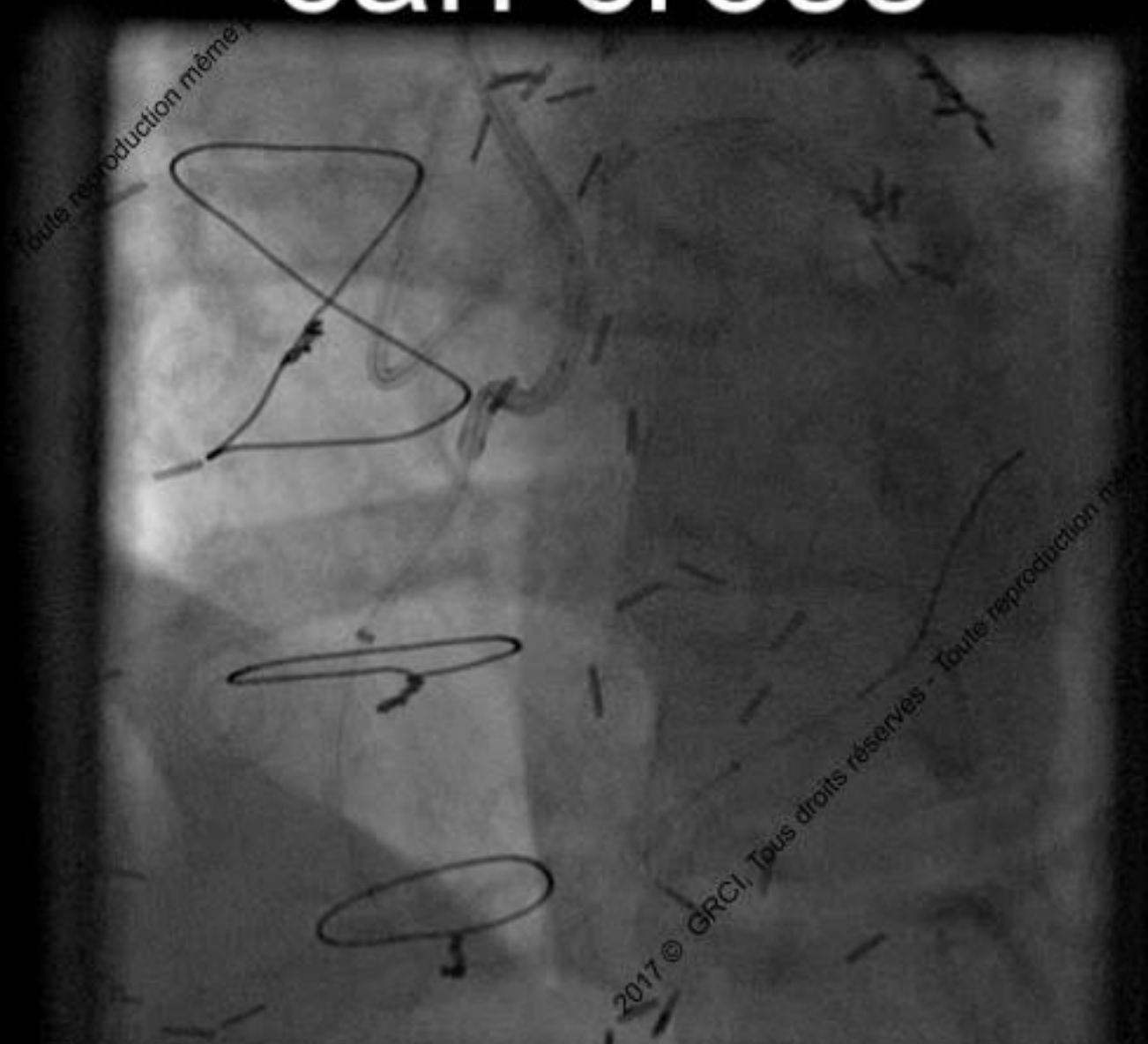


2017 © GRCI, Tous droits réservés - Toute reproduction mé

# Nothing but a wire can cross



# Nothing but a wire can cross



Toute reproduction même

2017 © GRCI, Tous droits réservés - Toute reproduction même

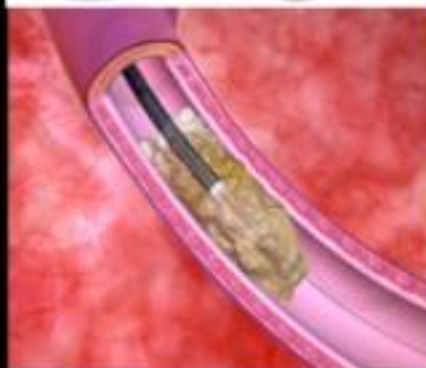


# Nothing but a wire can cross : Use the Laser

## How does ELCA work?

Photochemical

Dissolving molecular  
bonds

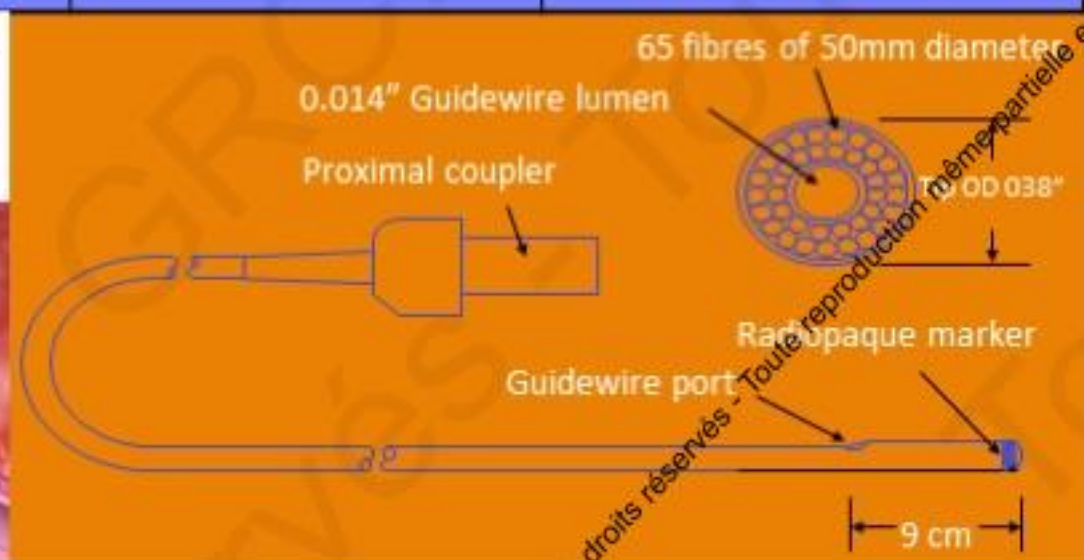


Photothermal

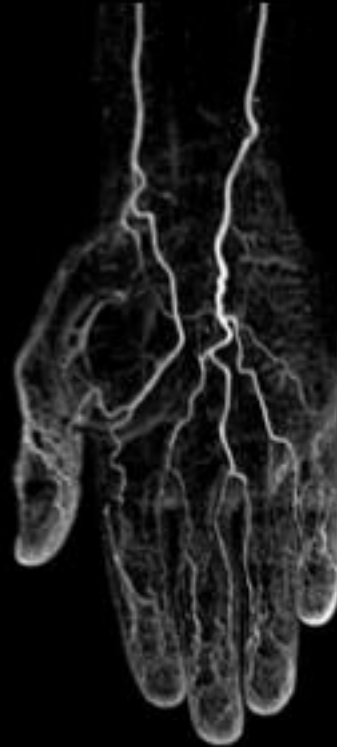
Produces photo-  
thermal energy

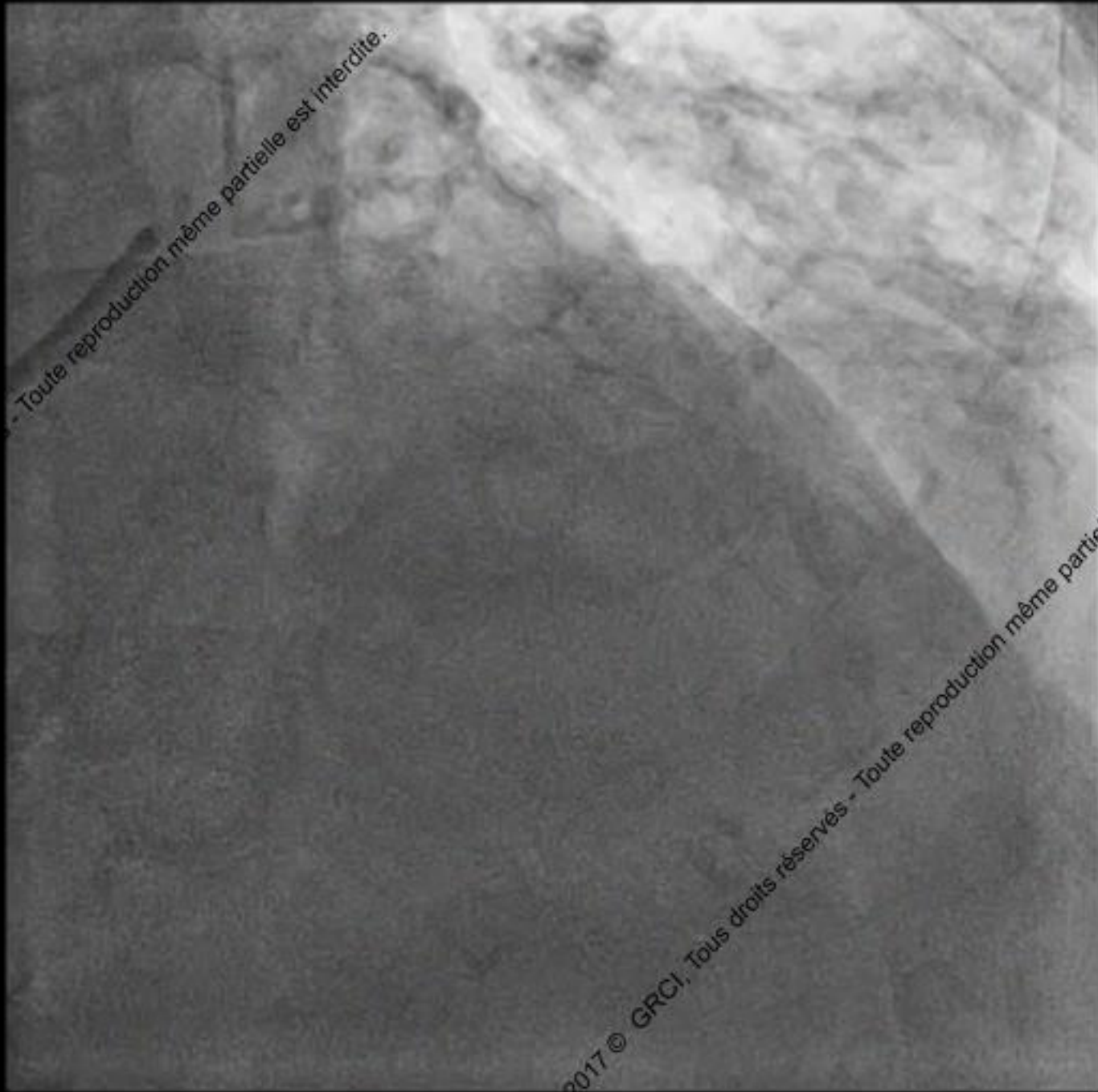Photomechanical

Creating  
kinetic energy

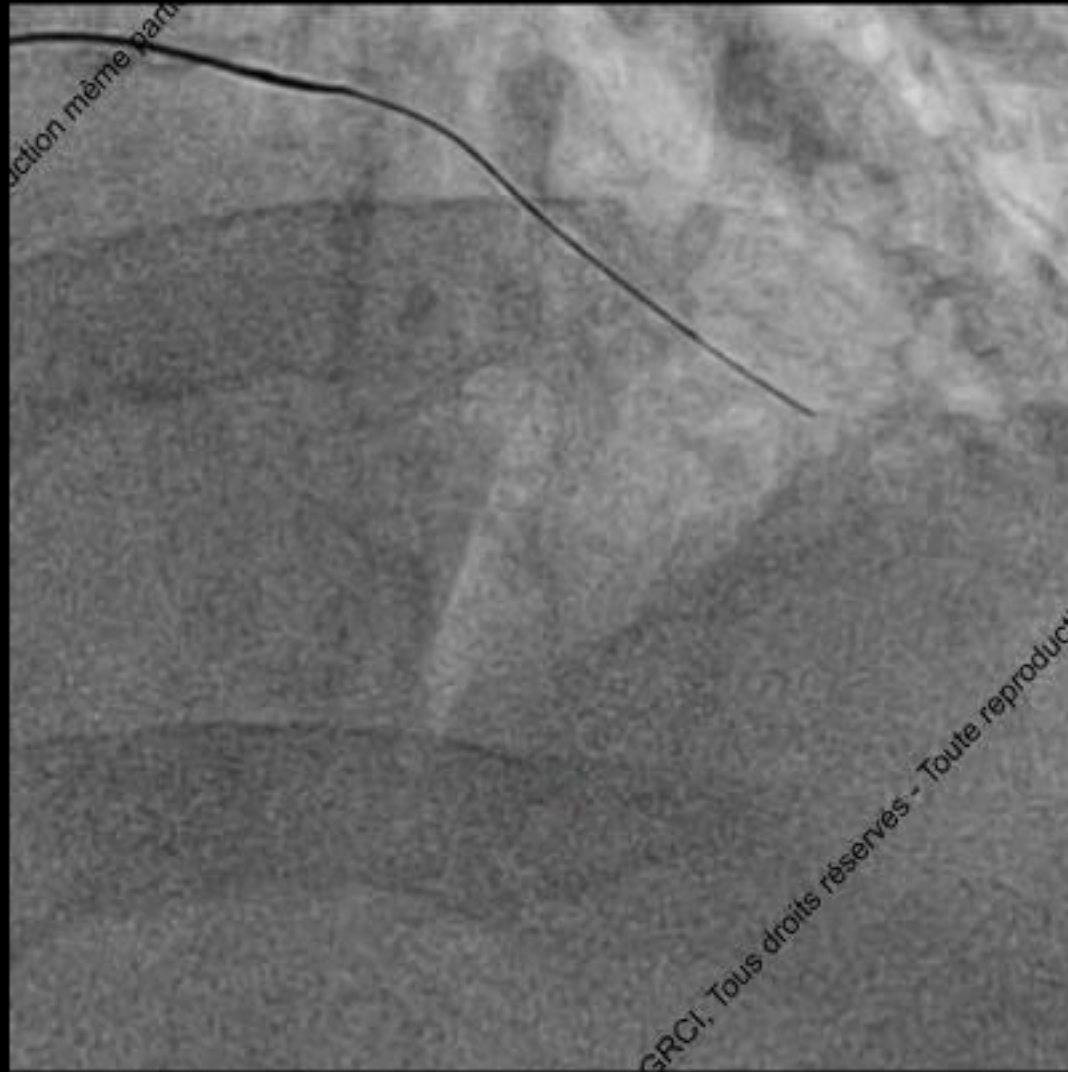


# Nothing can cross Tornus Failure

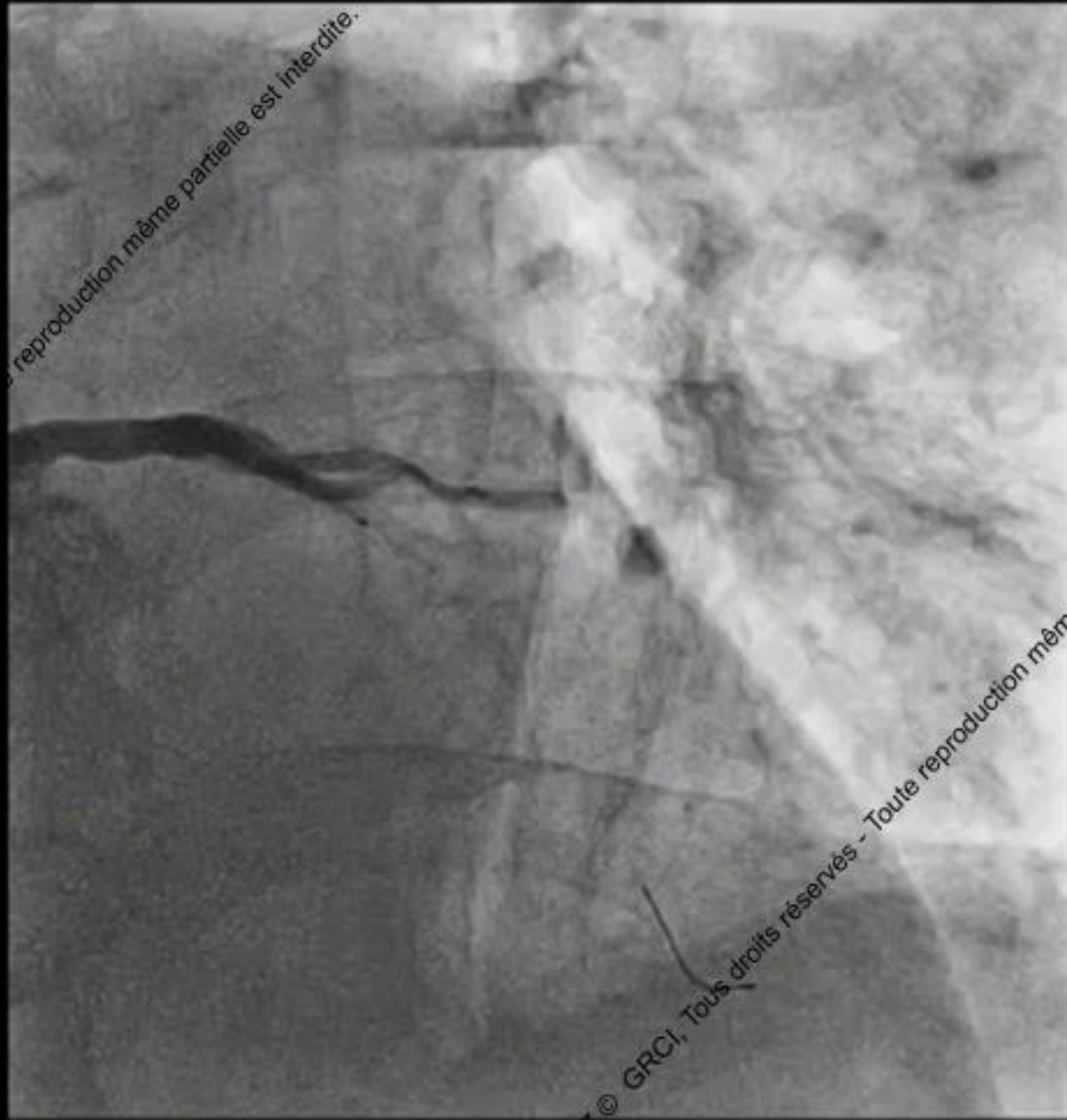




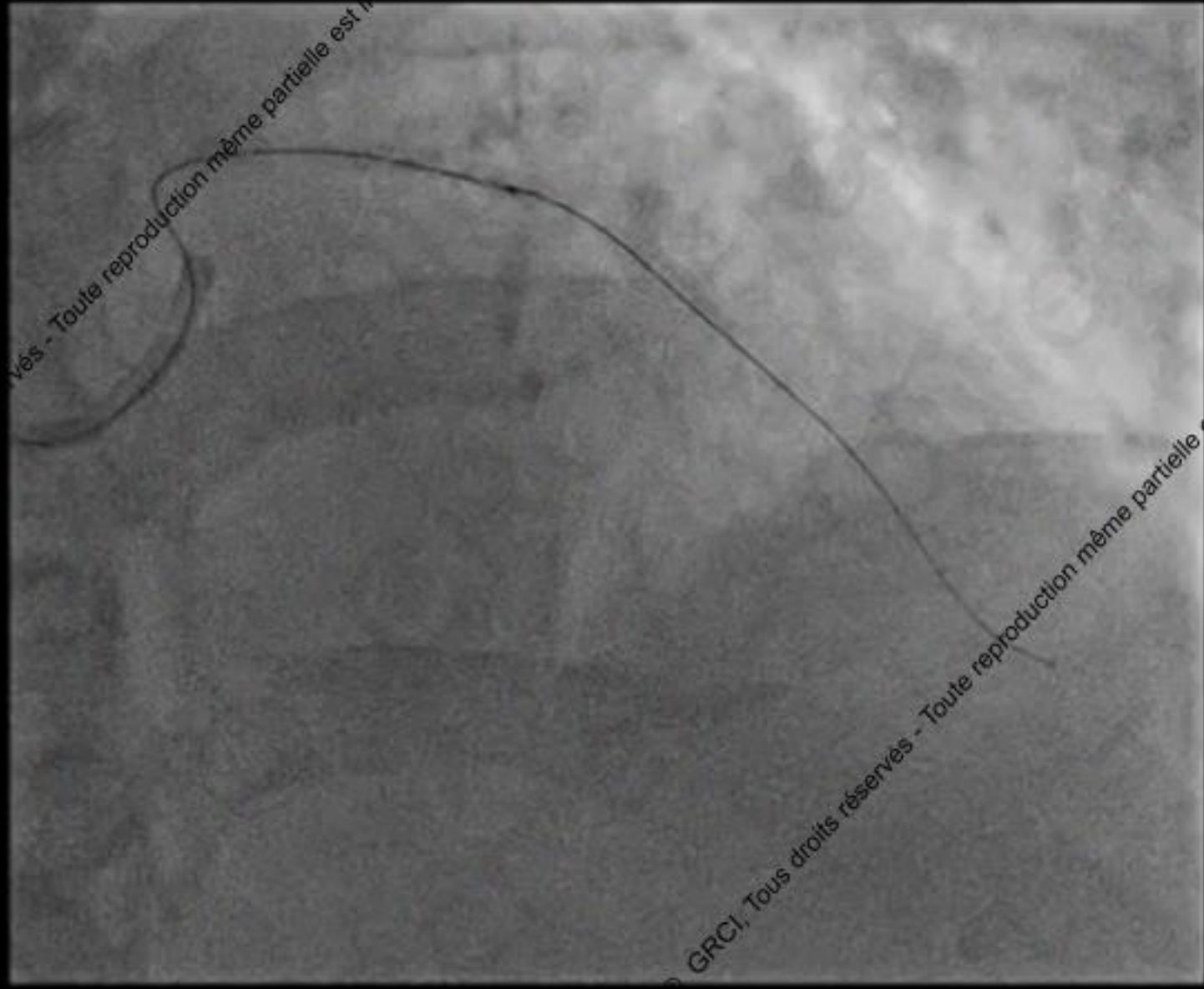
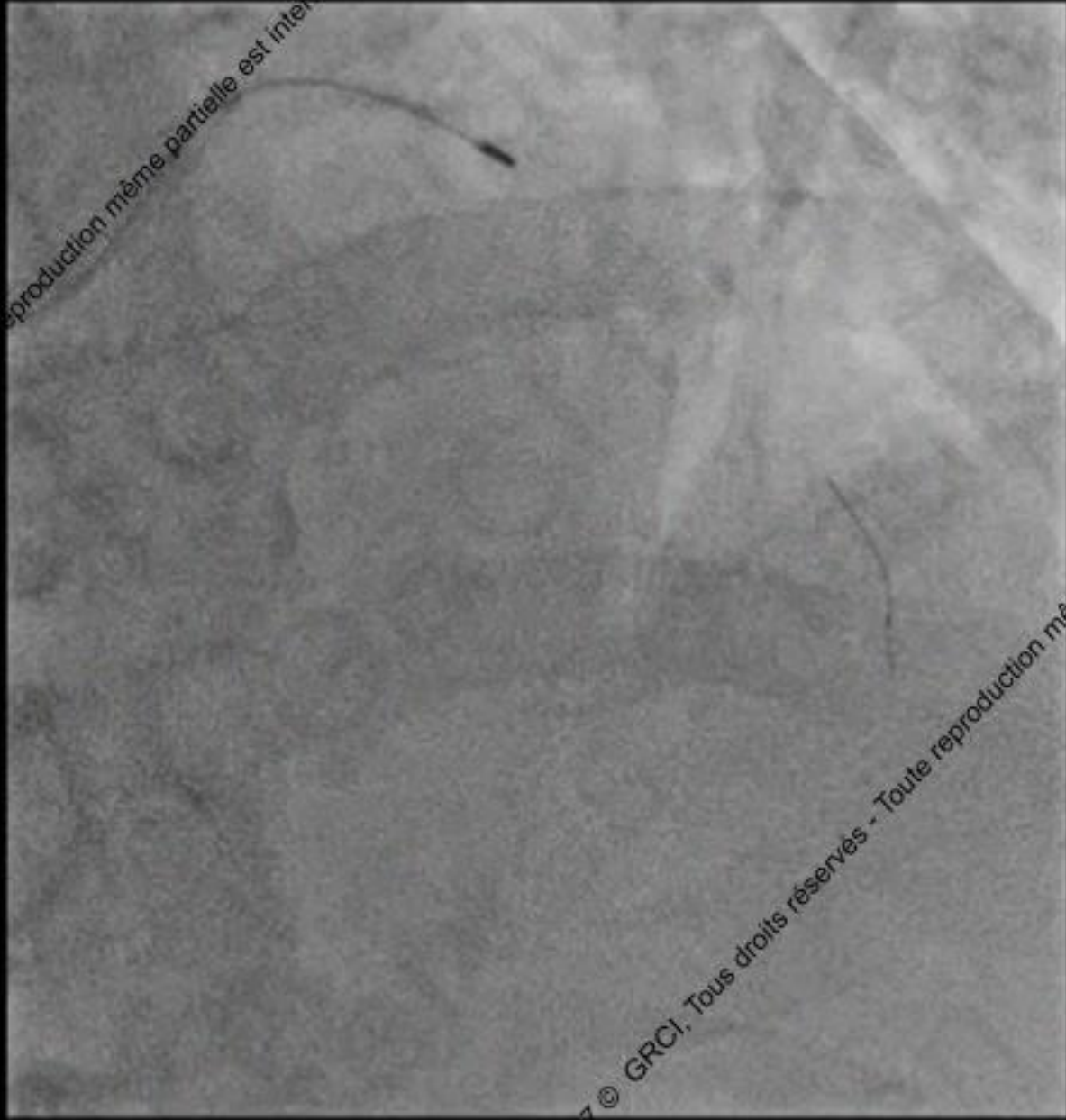


reproduction même partielle est interdite.

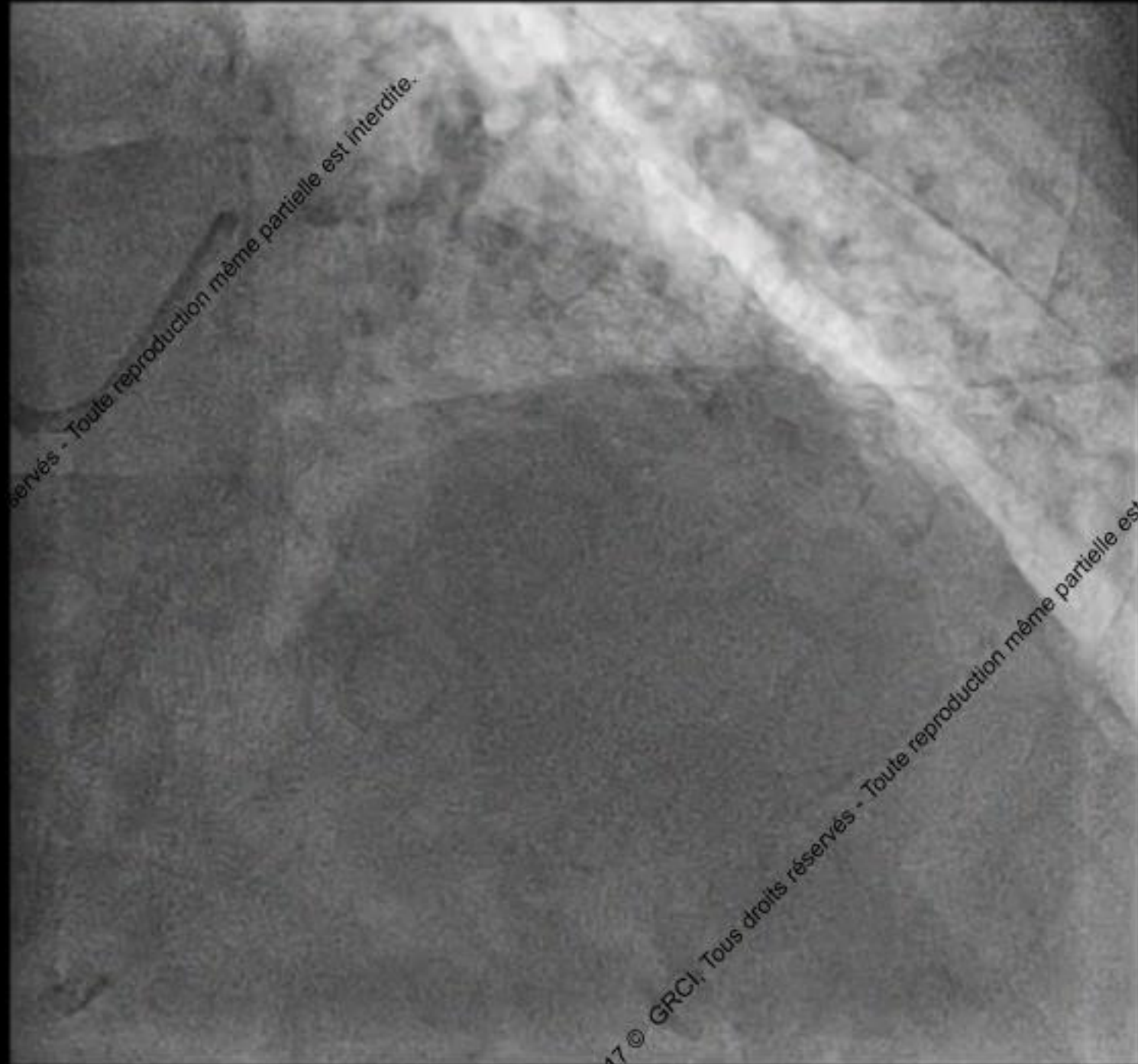


© GRCI, Tous droits réservés - Toute reproduction même



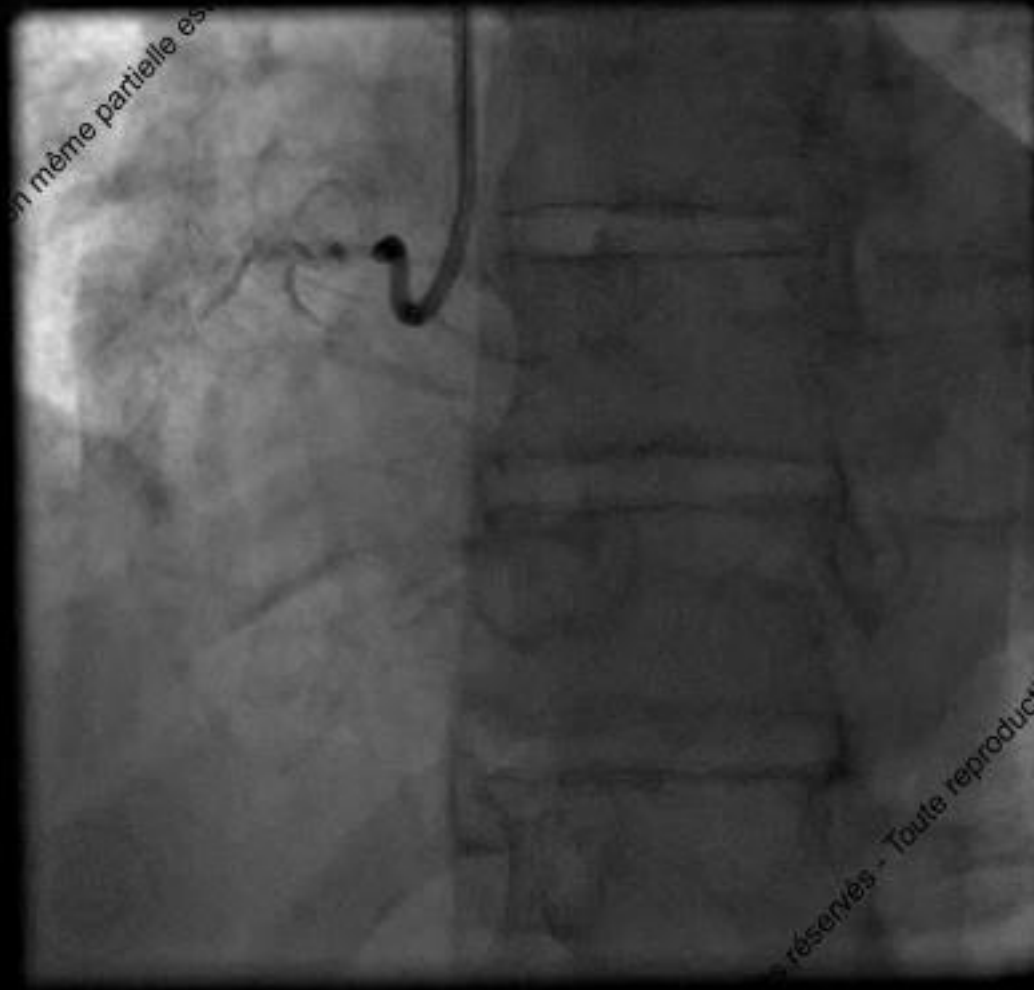


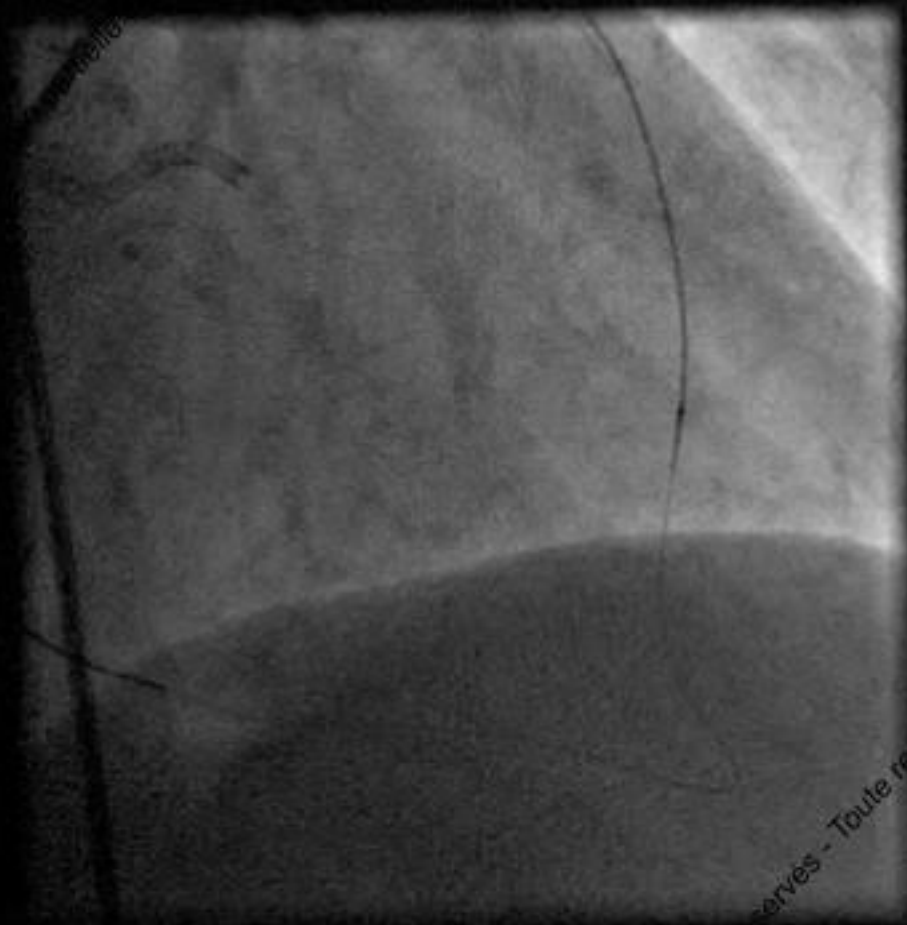



Tous droits réservés - Toute reproduction même partielle est interdite.

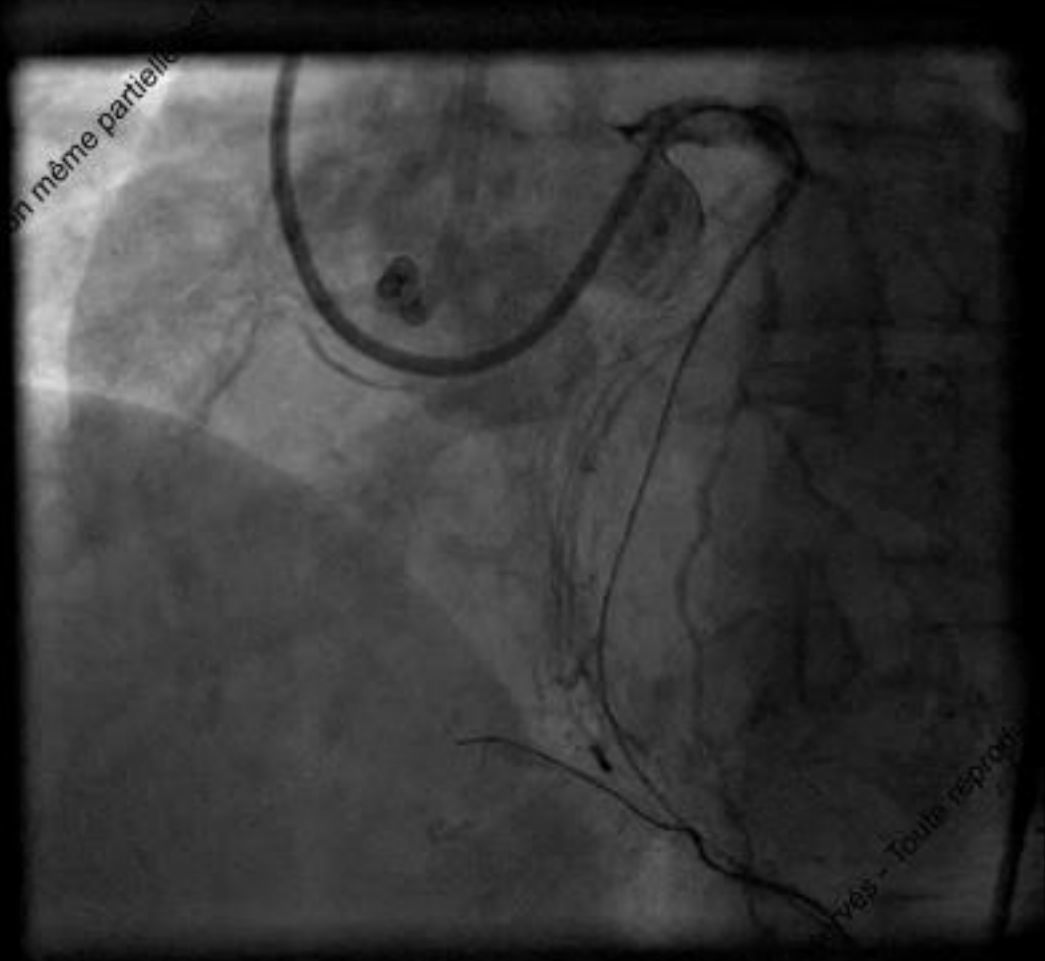
# Nothing can cross: SubIntimal angioplasty

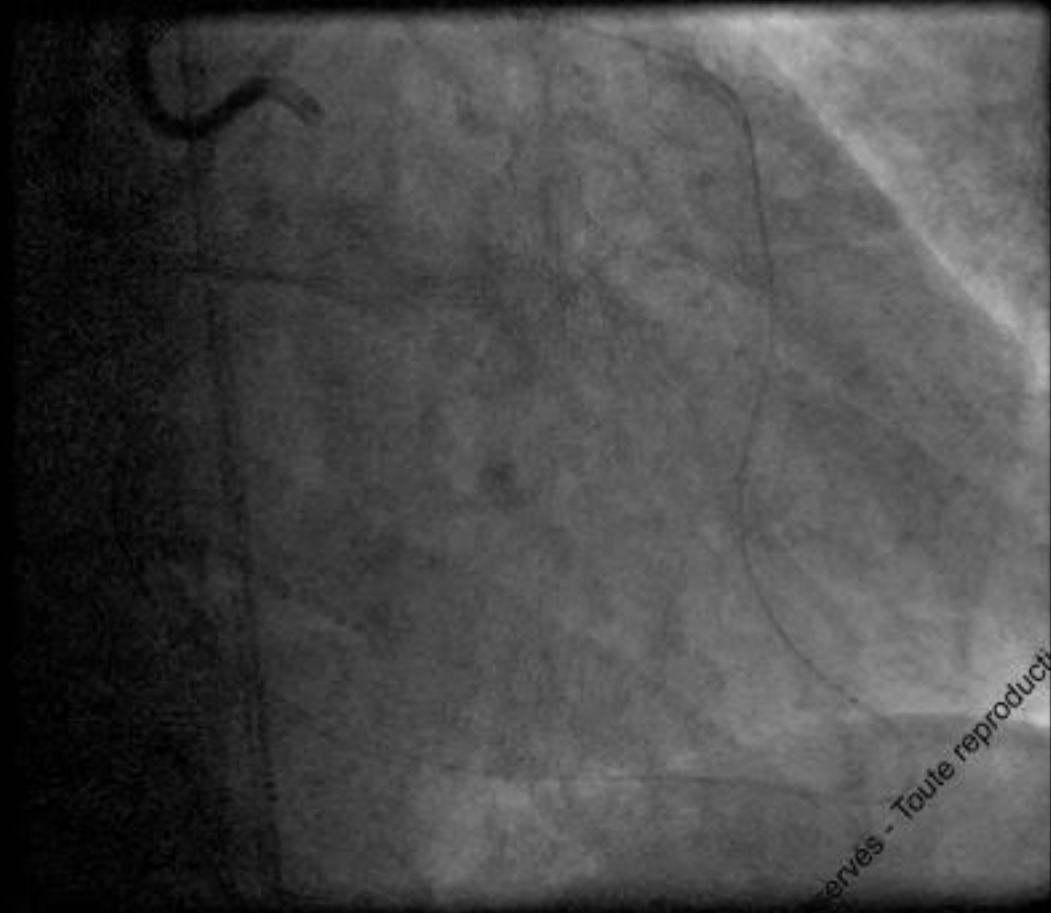




corvès - Toute res





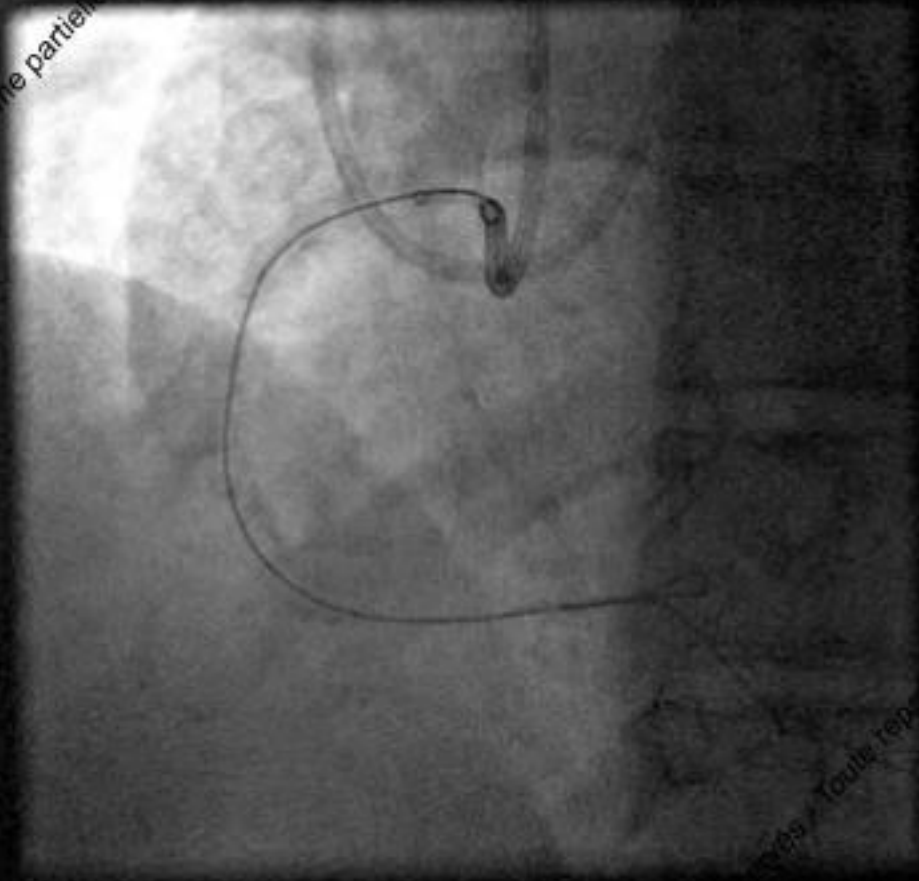


Reservés - Toute reproduction

Toute reproduction même partielle

2017 © GRCI, Tous droits réservés - Toute reproduction

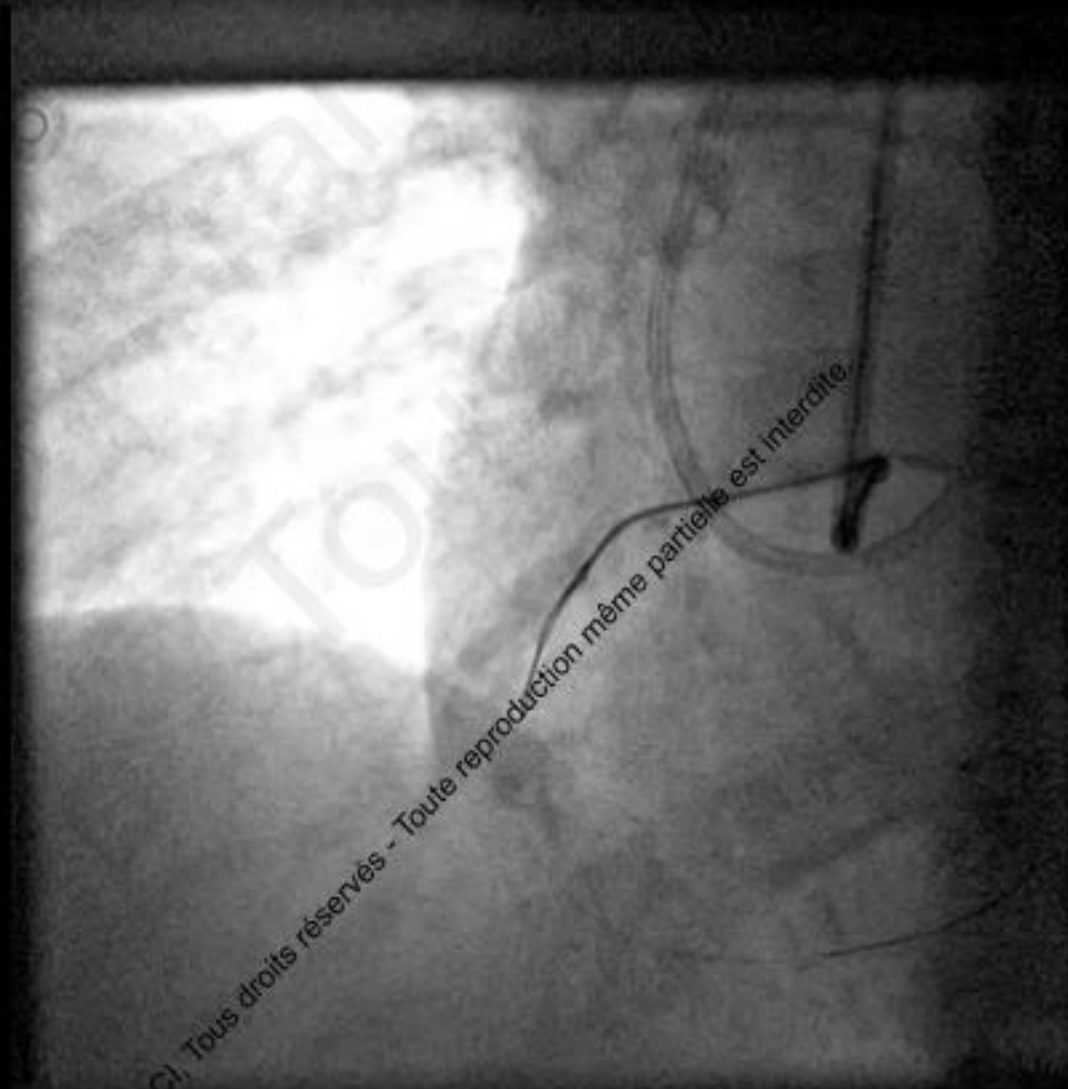
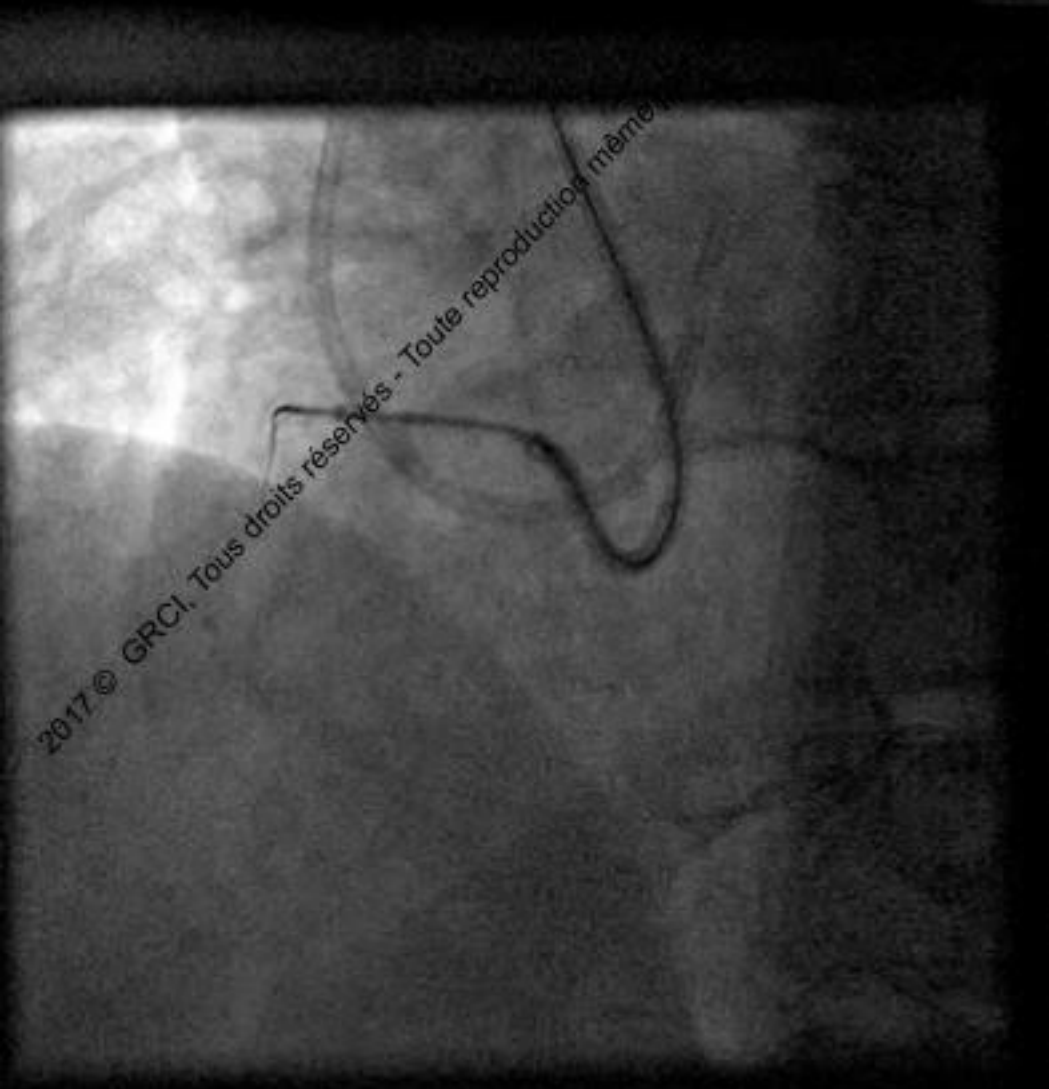
ation même partielle est inte



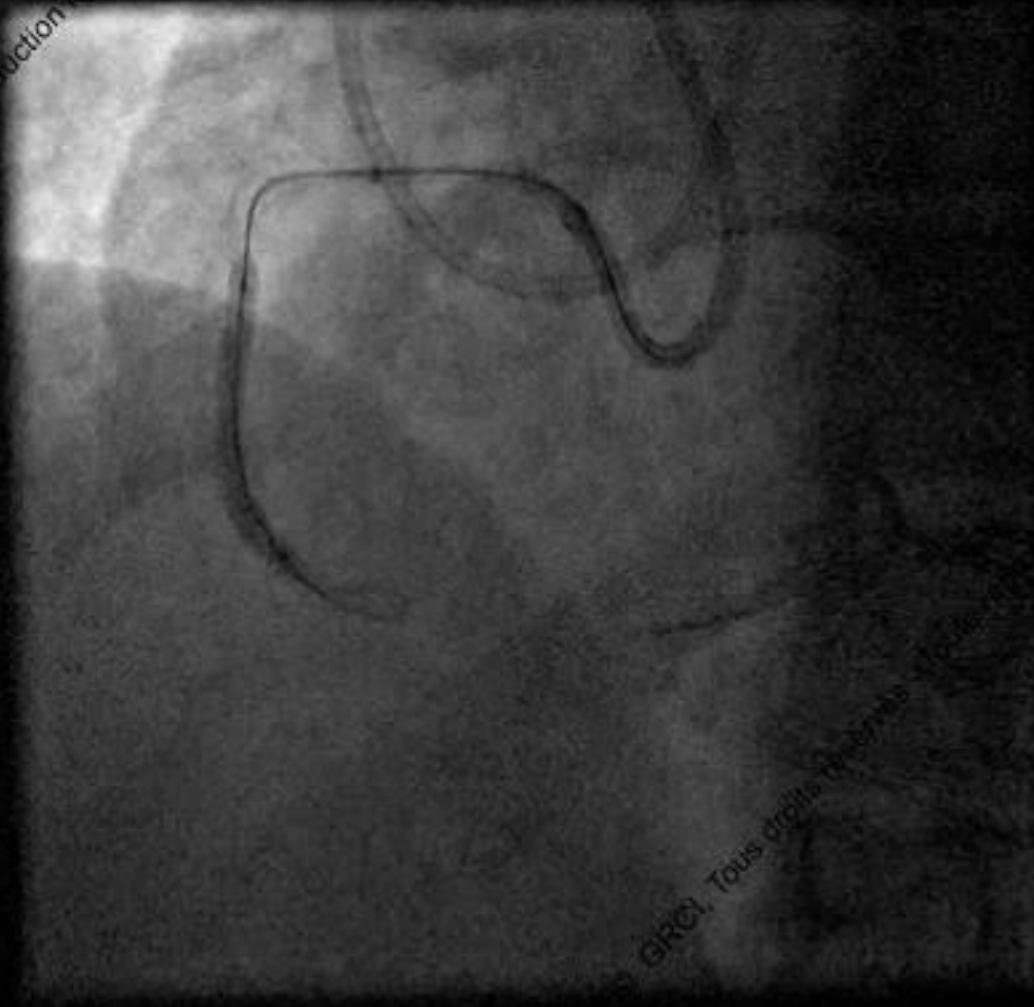
crés / Toule rep



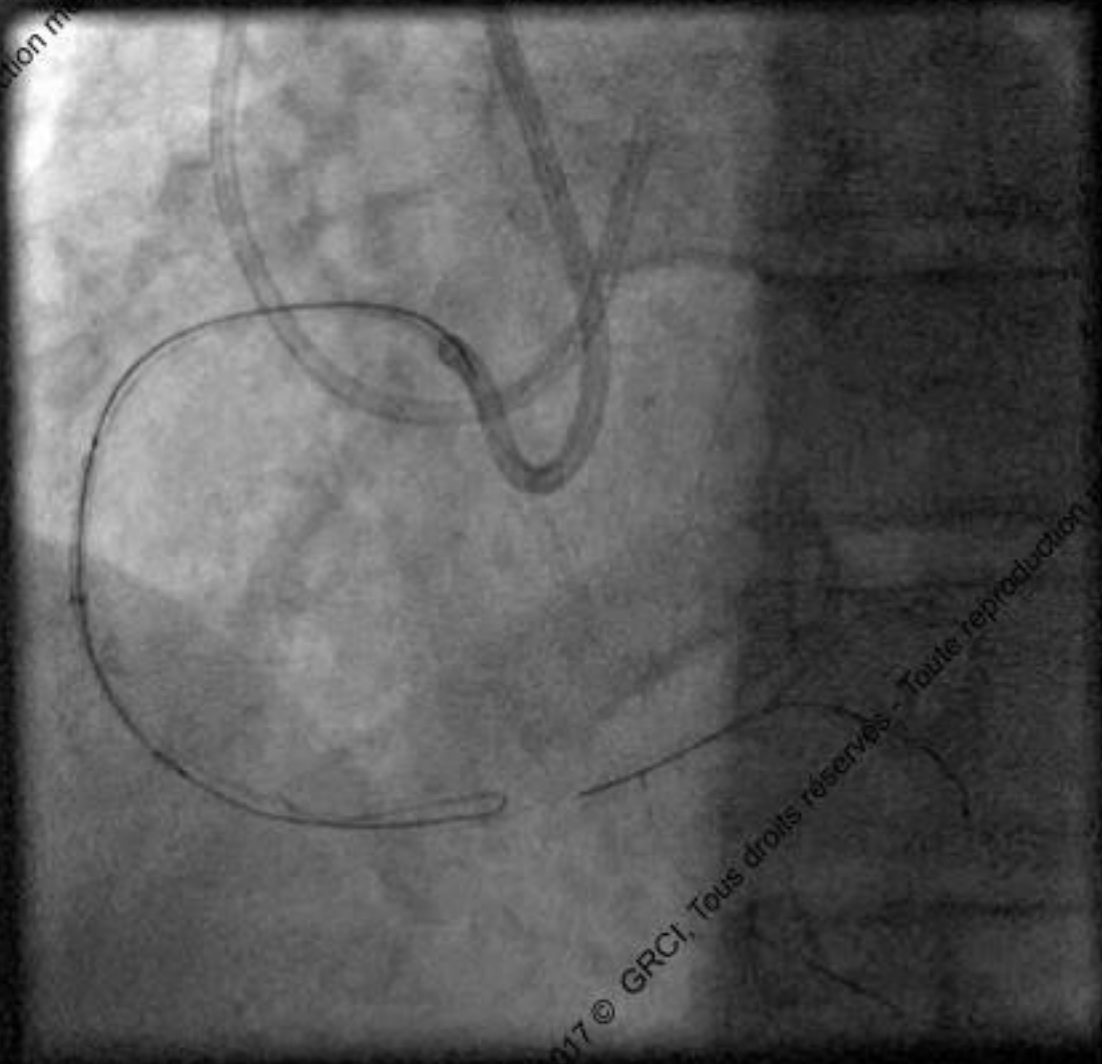
## AG knuckle in subintimal space



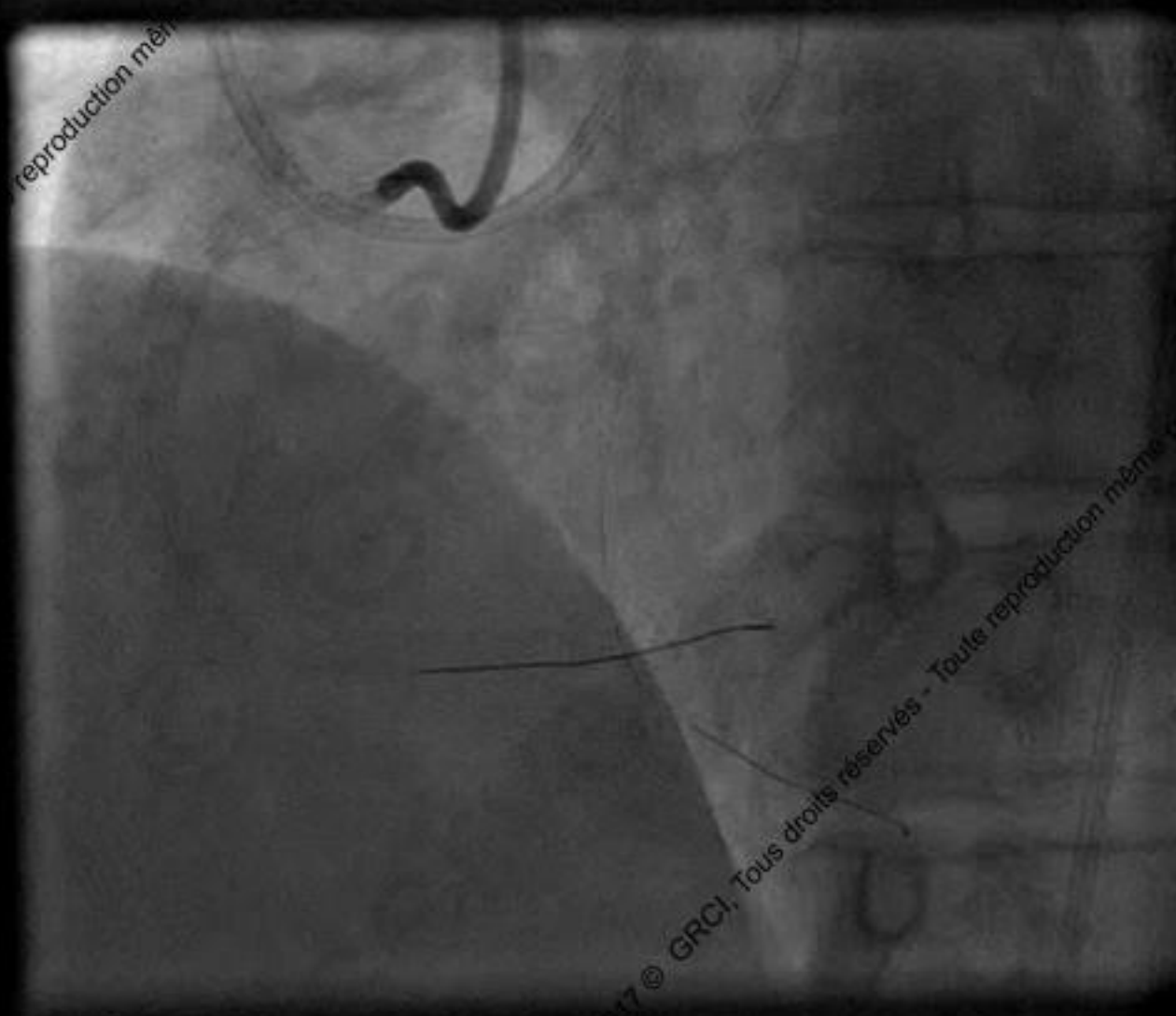
## Subintimal balloon angioplasty



## Stent advancement on « true to true Wire »



reproduction même



2017 © GRCI, Tous droits réservés - Toute reproduction même



# Conclusion

- Good Backup
  - Large GC
  - Active intubation
  - Guide Cath extension (Guideliner, M&Child, Guidezilla)
- Anchoring (antegrade, OTW, retrograde)
- Rotablator (if 0.009' wire cross)
- Lazer
- out of lumen (ADR, R-CART, balloon outside)