



TREATMENT OF COMPLEX PROXIMAL DESCENDING AORTIC ANEURYSM WITH FENESTRATED AND SCALLOPED TEVAR



THE INDONESIAN SOCIETY OF
INTERVENTIONAL CARDIOLOGY
PERHIMPUNAN INTERVENSI KARDIOLOGI INDONESIA

Suko Adiarto

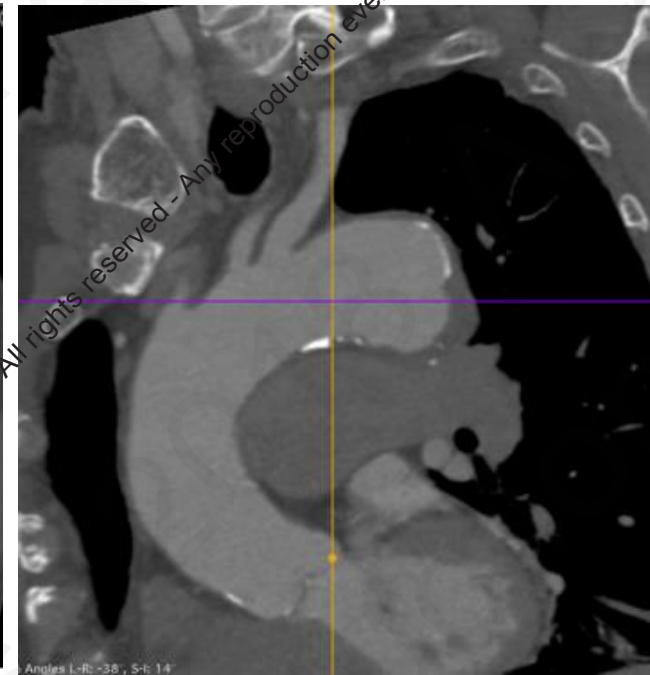
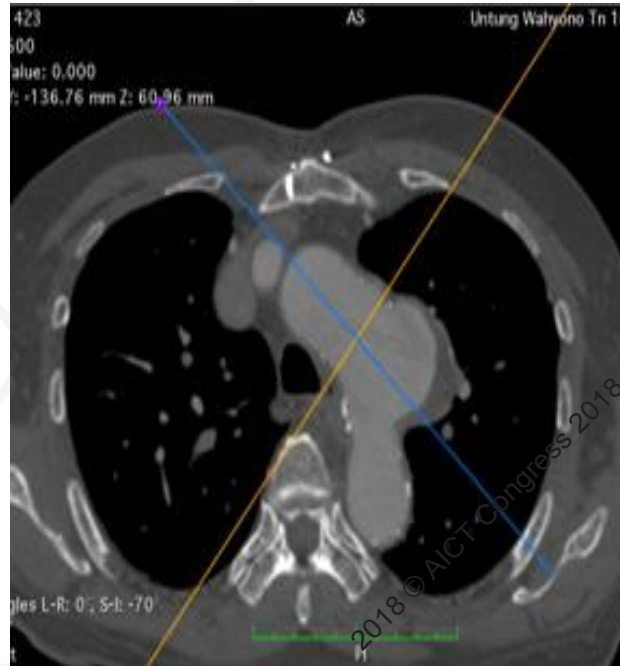
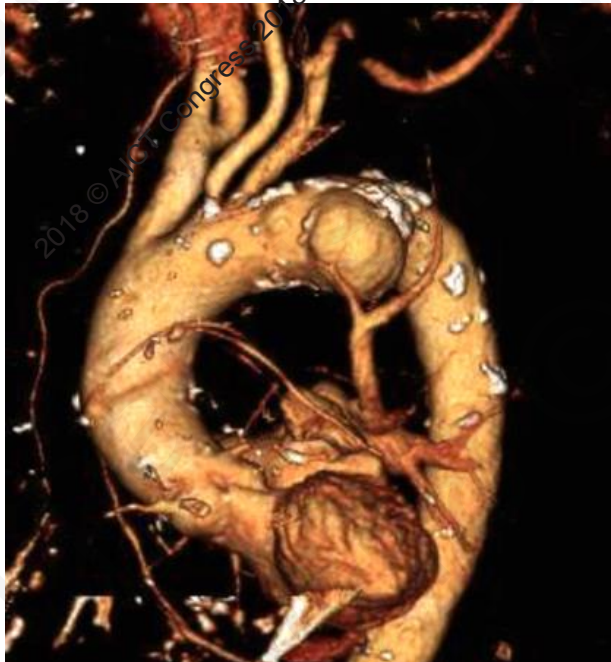Indonesian Society of Interventional Cardiology

CONFLICTS OF INTEREST

Speaker's name : Suko Adiarso

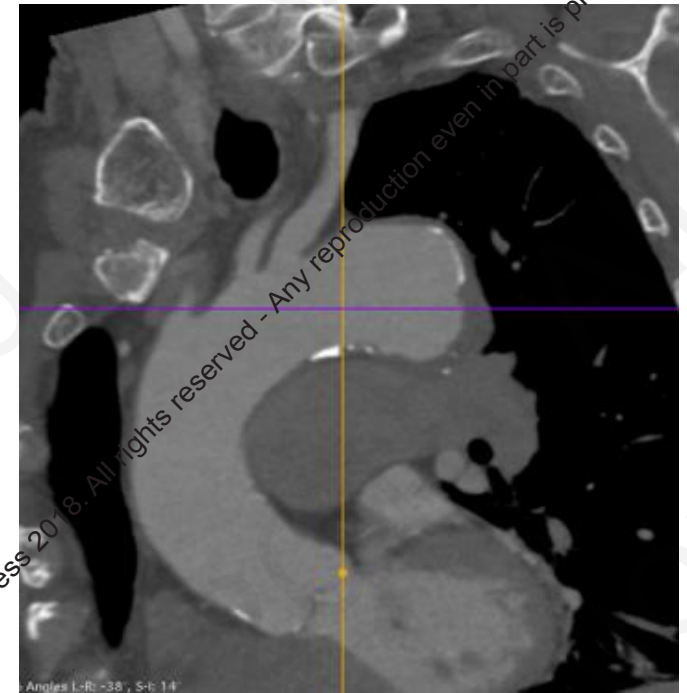
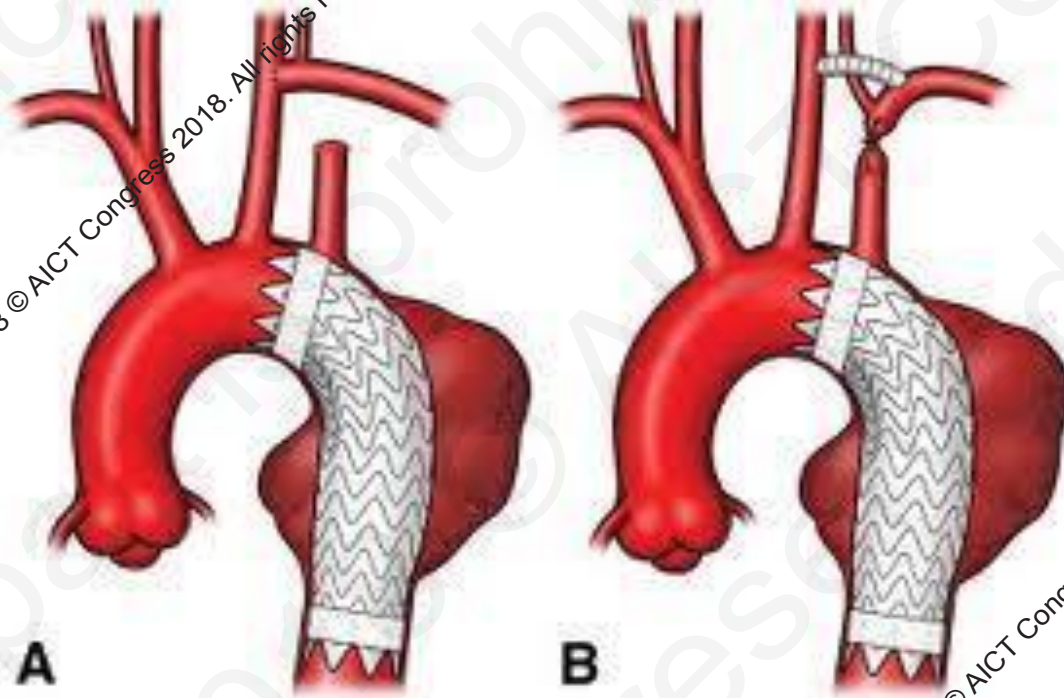
**I have no actual or potential conflict of interest
in relation to this program presentation**

73 YEAR OLD HYPERTENSIVE MALE



Any reproduction even in part is prohibited.

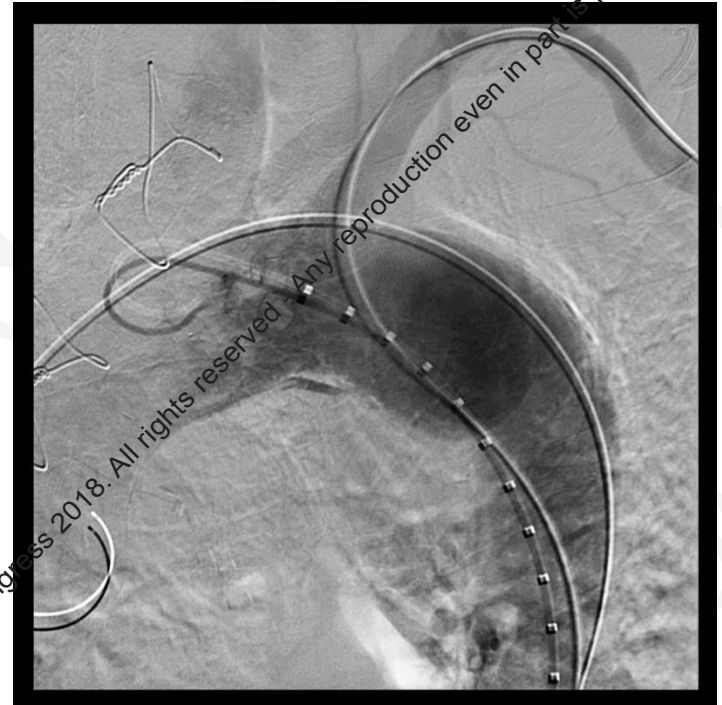
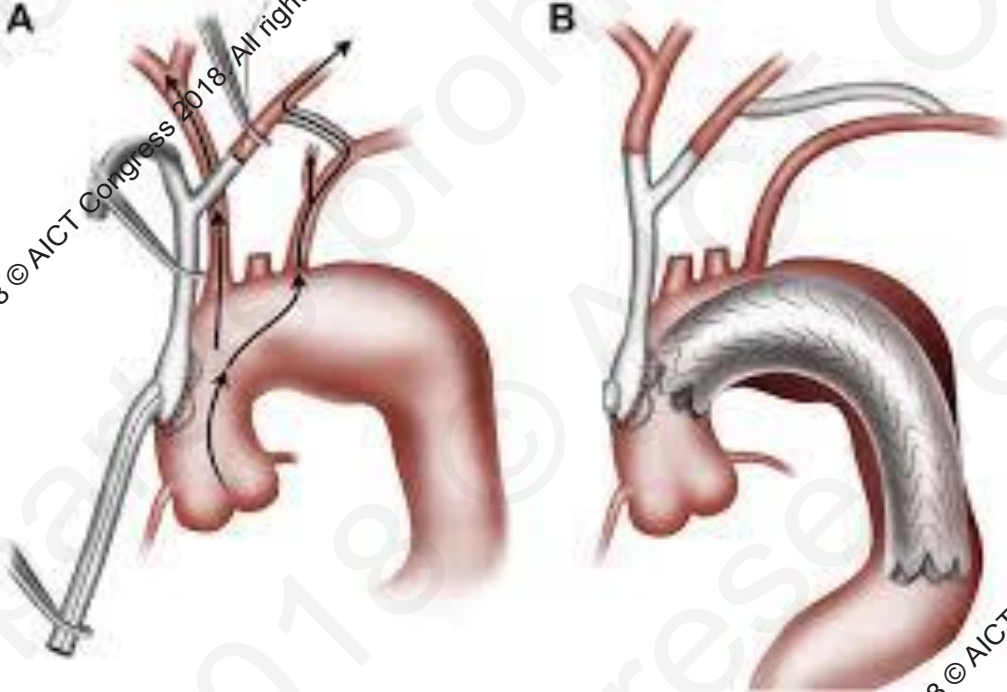
OPTION 1: CAROTID-SUBCLAVIAN BYPASS- TEVAR



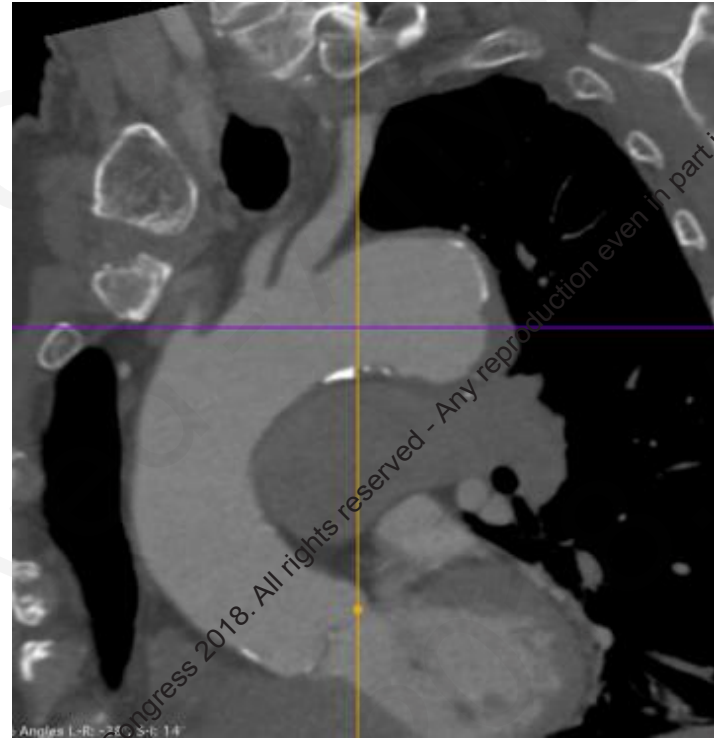
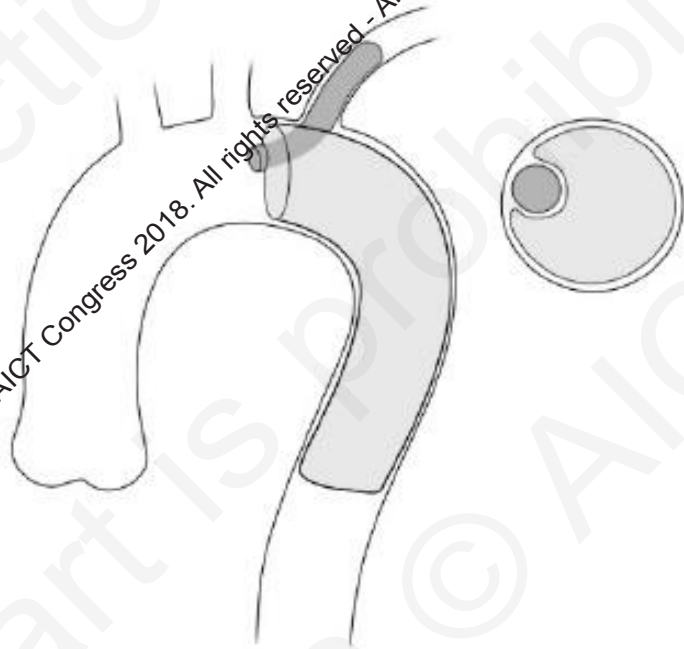
2018 © AICT Congress 2018. All rights reserved - Any reproduction even in part is prohibited.

2018 © AICT Congress 2018. All rights reserved - Any reproduction even in part is prohibited.

OPTION 2: DEBRANCHING-TEVAR



OPTION 3: TEVAR WITH CHIMNEY



2018 © AICT Congress 2018. All rights reserved - Any reproduction even in part is prohibited.

2018 © AICT Congress 2018. All rights reserved - Any reproduction even in part is prohibited.

- ✘ TEVAR with Multiple Chimneys
- ✘ TEVAR with Multiple Fenestration

2018 © AICT Congress 2018. All rights reserved - Any reproduction even in part is prohibited.

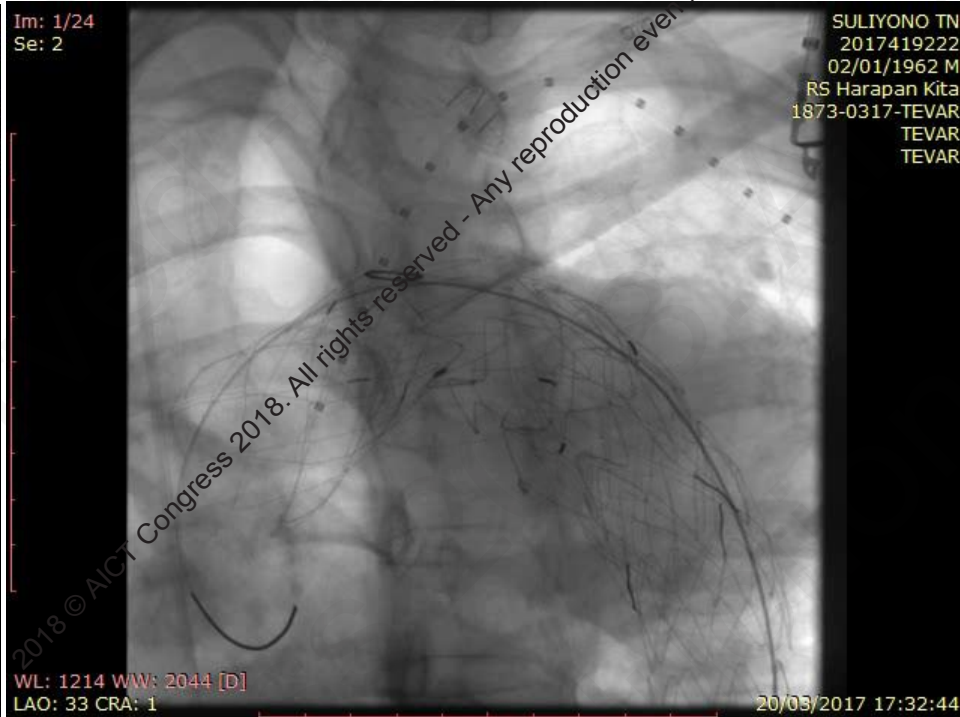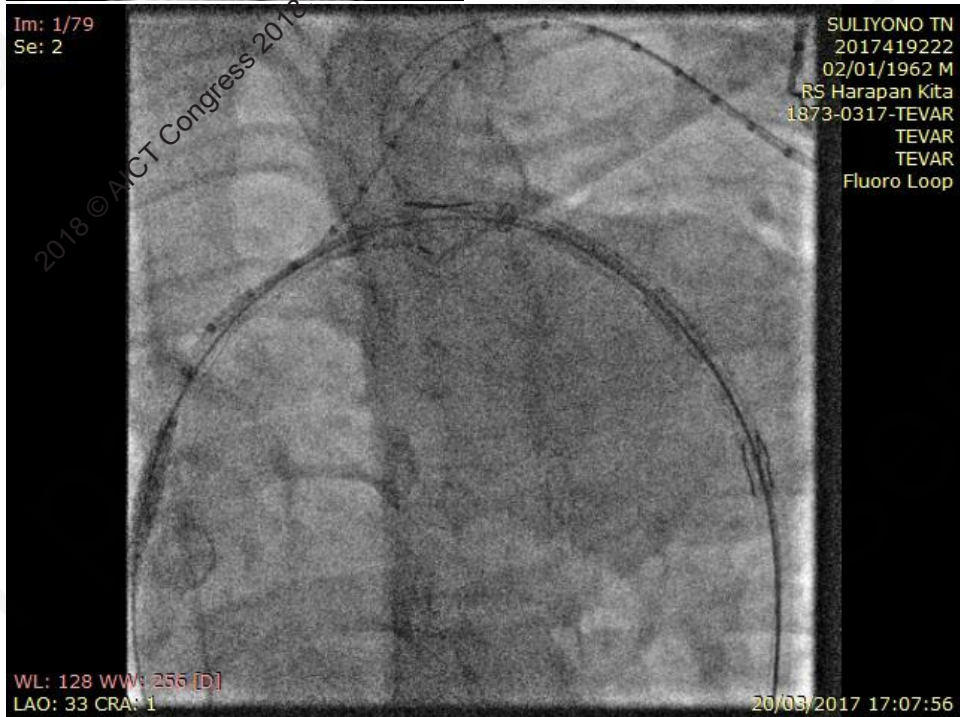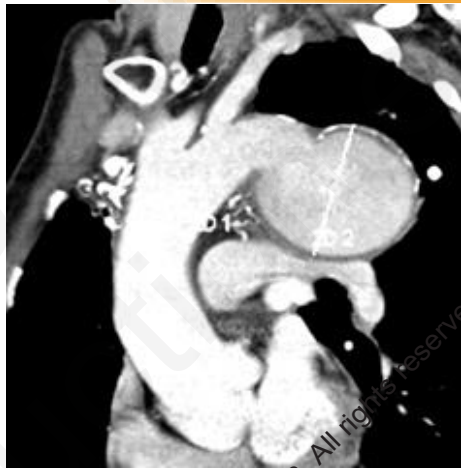
2018 © AICT Congress 2018. All rights reserved - Any reproduction even in part is prohibited.


- ✘ Single Fenestrated TEVAR (LSA)
- ✘ Scallop (LCA & Brachiocephalic)

2018 © AICT Congress 2018. All rights reserved - Any reproduction even in part is prohibited.

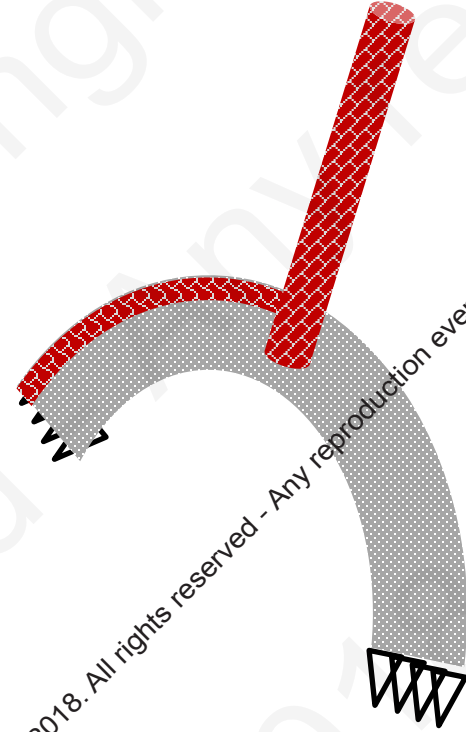
2018 © AICT Congress 2018. All rights reserved - Any reproduction even in part is prohibited.

FENESTRATED STENT GRAFT



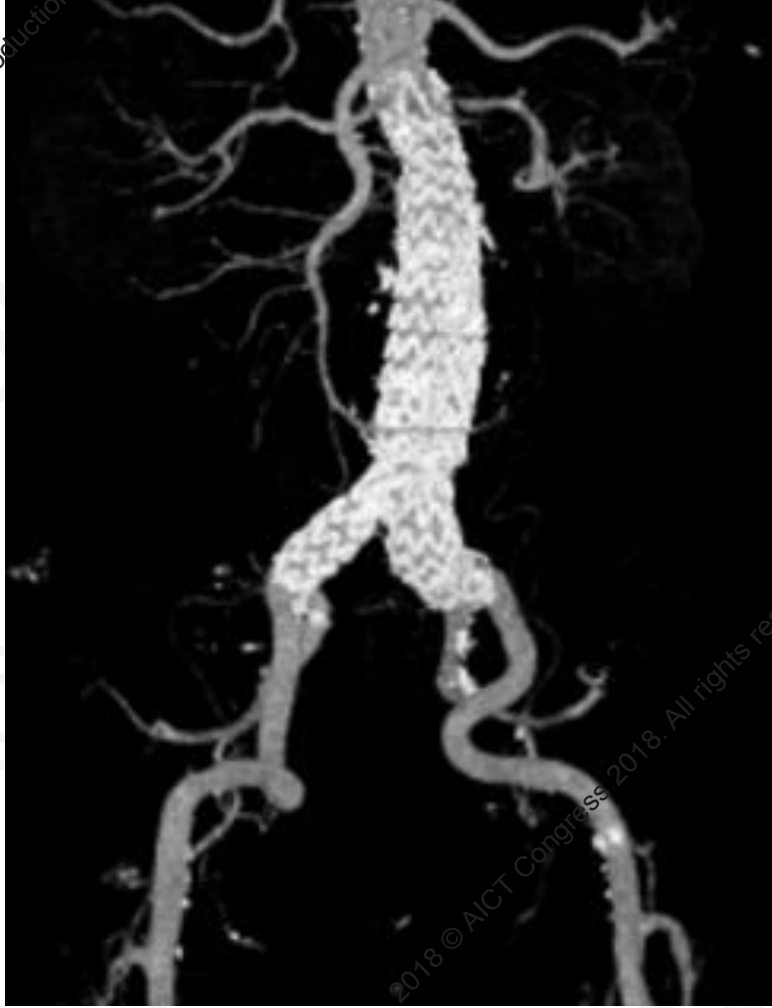

2018 © AICT Congress 2018. All rights reserved - Any reproduction even in part is prohibited.



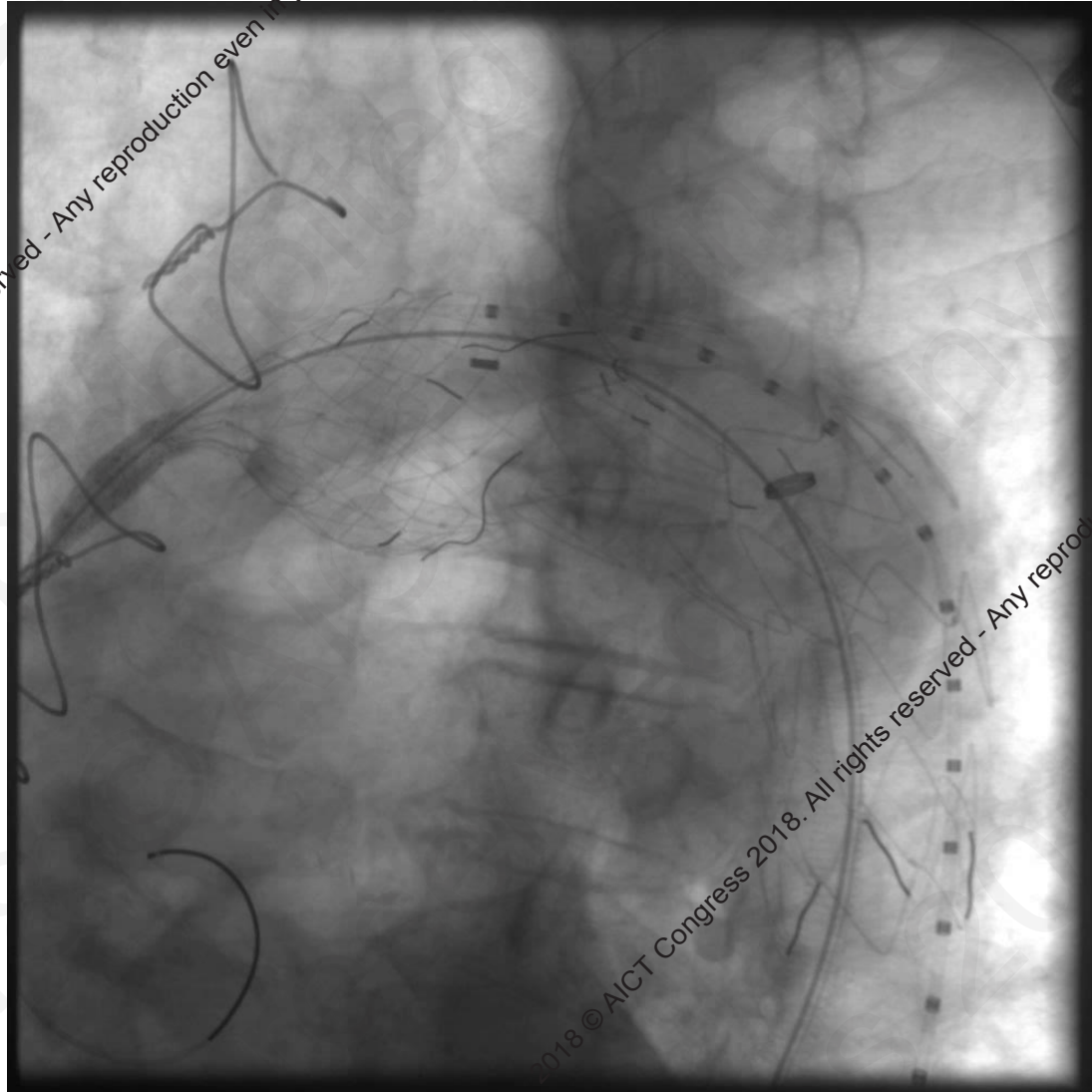
2018 © AICT Congress 2018. All rights reserved - Any reproduction even in part is prohibited.

2018 © AICT Congress 2018. All rights reserved - Any reproduction even in part is prohibited.



2018 © AICT Congress 2018. All rights reserved - Any reproduction even in part is prohibited.

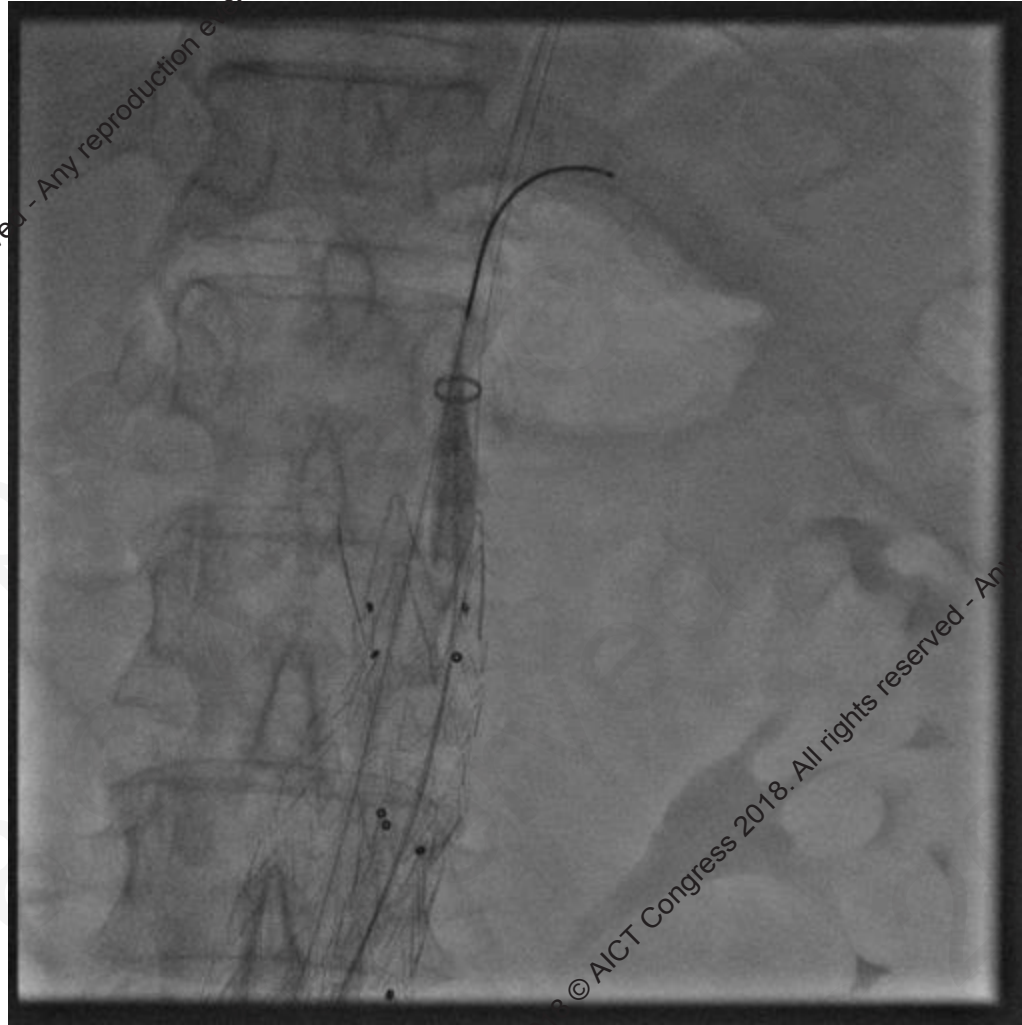
PARTIALLY OCCLUDED LCA



2018 © AICT Congress 2018. All rights reserved - Any reproduction even in part is prohibited.

2018 © AICT Congress 2018. All rights reserved - Any reproduction even in part is prohibited.

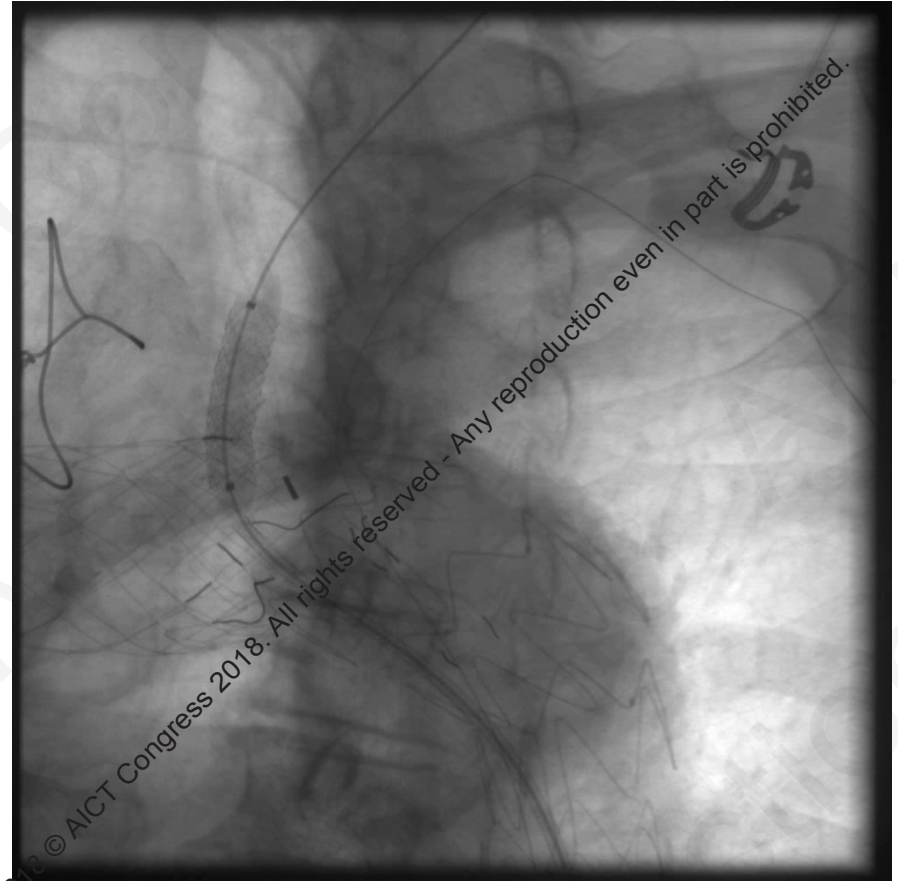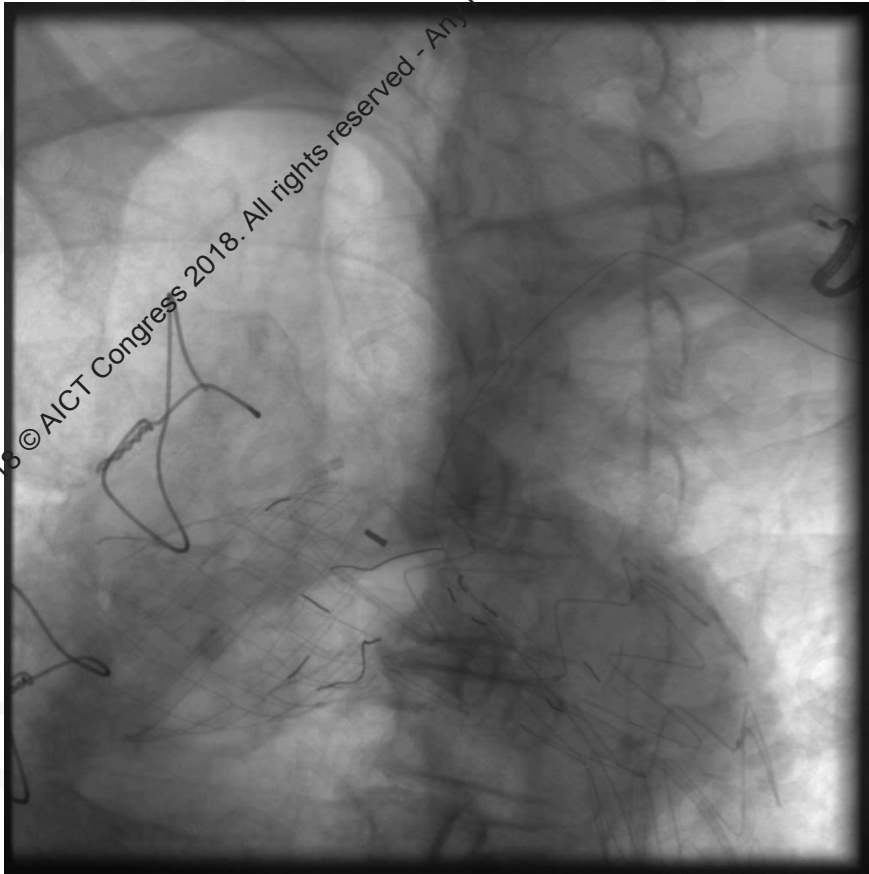
SECURING DETACHED OLIVE TIP



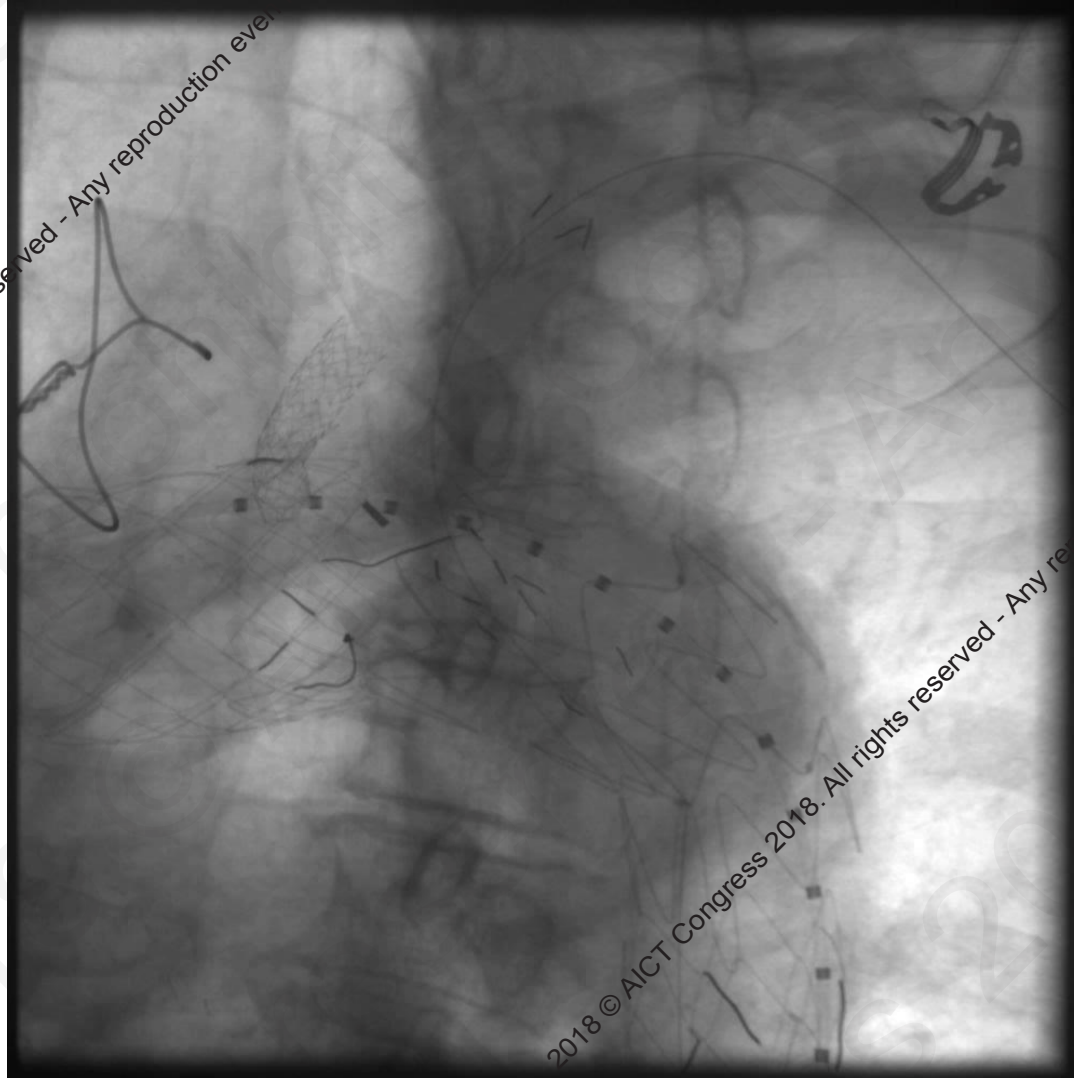
2018 © AICT Congress 2018. All rights reserved - Any reproduction even in part is prohibited.

2018 © AICT Congress 2018. All rights reserved - Any reproduction even in part is prohibited.

SECURING LCA



FINAL RESULT



- ✘ Scalloped and Fenestrated TEVAR can used to treat proximal descending aortic aneurysm with difficult anatomy

2018 © AICT Congress 2018. All rights reserved - Any reproduction even in part is prohibited.

2018 © AICT Congress 2018. All rights reserved - Any reproduction even in part is prohibited.

2018 © AICT Congress 2018. All rights reserved - Any reproduction even in part is prohibited.

THANK YOU

2018 © AICT Congress 2018. All rights reserved - Any reproduction even in part is prohibited.

14th

AICT

ASIAN INTERVENTIONAL CARDIOVASCULAR THERAPEUTICS
THE OFFICIAL CONGRESS OF APSIC

7 - 9th September 2018

Hong Kong

Convention and Exhibition Centre (HKCEC)

2018 © AICT Congress 2018. All rights reserved - Any reproduction even in part is prohibited.

2018 © AICT Congress 2018. All rights reserved - Any reproduction even in part is prohibited.