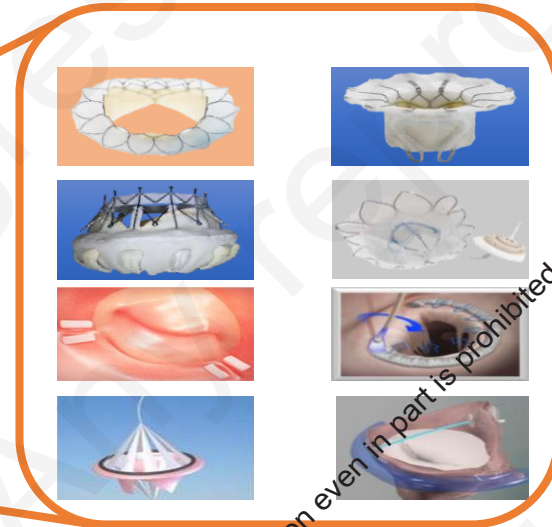
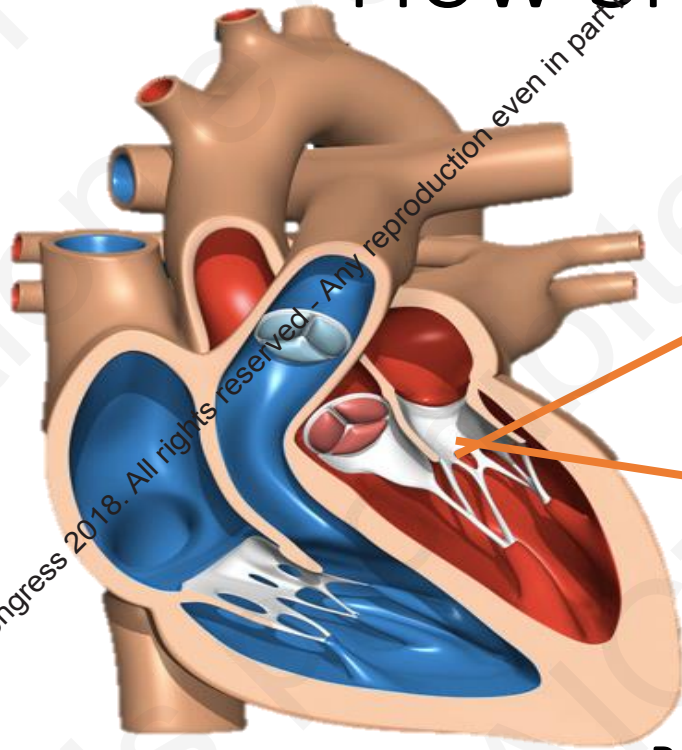


# How Should I Treat?



2018 © AICT Congress 2018. All rights reserved - Any reproduction even in part is prohibited.

Ravinay Bhindi  
Interventional Cardiologist  
Royal North Shore Hospital

Professor of Medicine  
University of Sydney

 @Ravmay



THE UNIVERSITY OF  
SYDNEY

2018 © AICT Congress 2018. All rights reserved - Any reproduction even in part is prohibited.

# Case History

- 80 year old male
- NYHA Class III symptoms
- 2month deterioration

## Background

- Non ischaemic cardiomyopathy ( 15 years)
- History of MVP ( moderate MR 6 months ago)
- HT
- CKD Cr 112 EGFR 49

## **Medications**

- Bumetanide 1mg daily
- Bisoprolol 5mg daily
- Aldactone 25mg daily

## **Allergies/Intolerance**

- Frusemide
- ACEi, ARB

## Clinical Examination

- 167cm/ 78.2kg
- SR 100bpm, RR 18 per minute, BP 128/78 mmHg
- Sa 95% RA
- JVP 5cm
- HS dual ,pansystolic murmur
- Lung fields: crepitations at bases

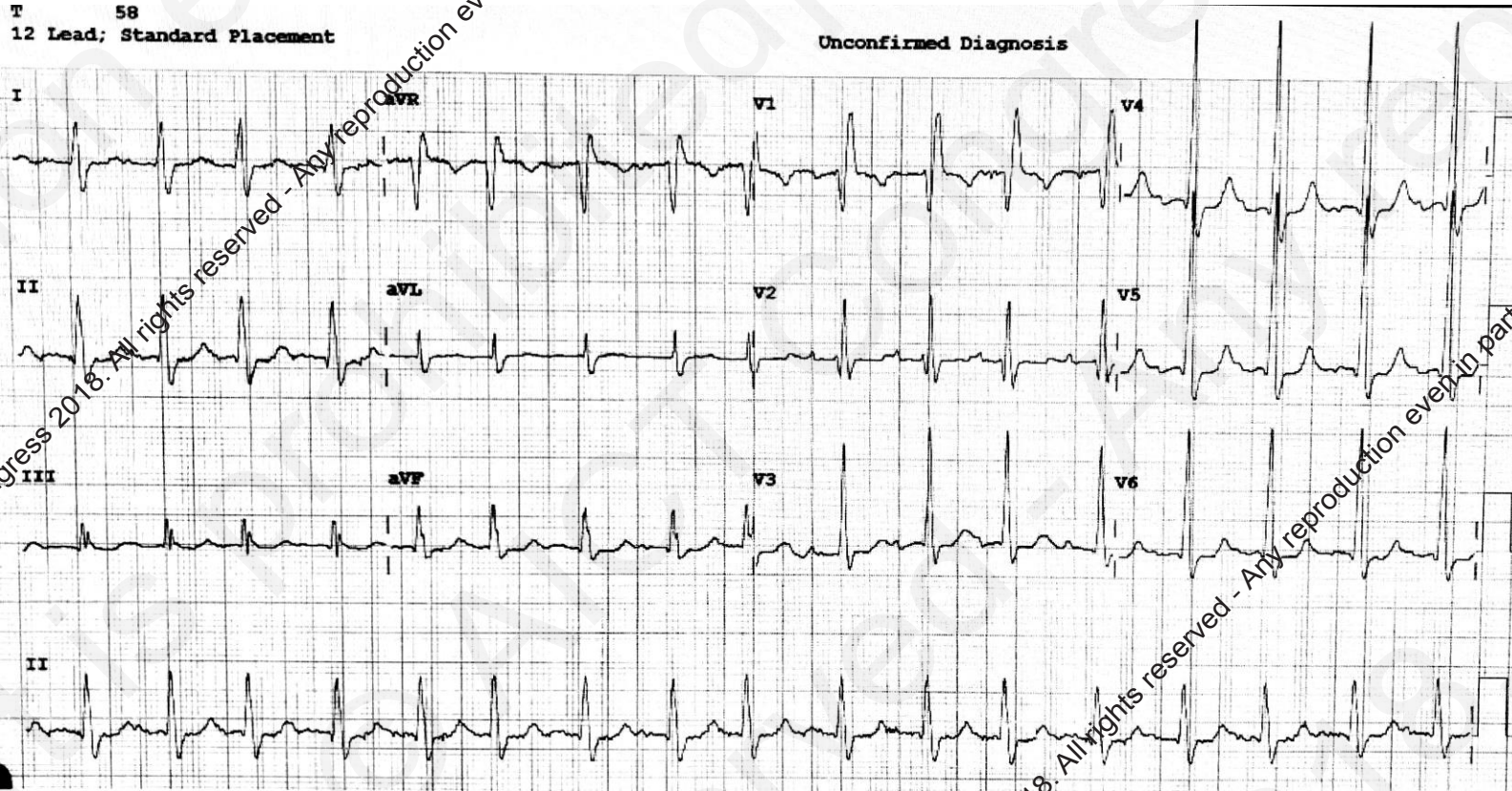
## **Bloods**

- Hb 150
- Platelets 130
- Cr 112 EGFR 49
- Bili 22, AST 29 ALT 28 ALP 112 GGT126

2018 © AICT Congress 2018. All rights reserved - Any reproduction even in part is prohibited.

2018 © AICT Congress 2018. All rights reserved - Any reproduction even in part is prohibited.

# ECG



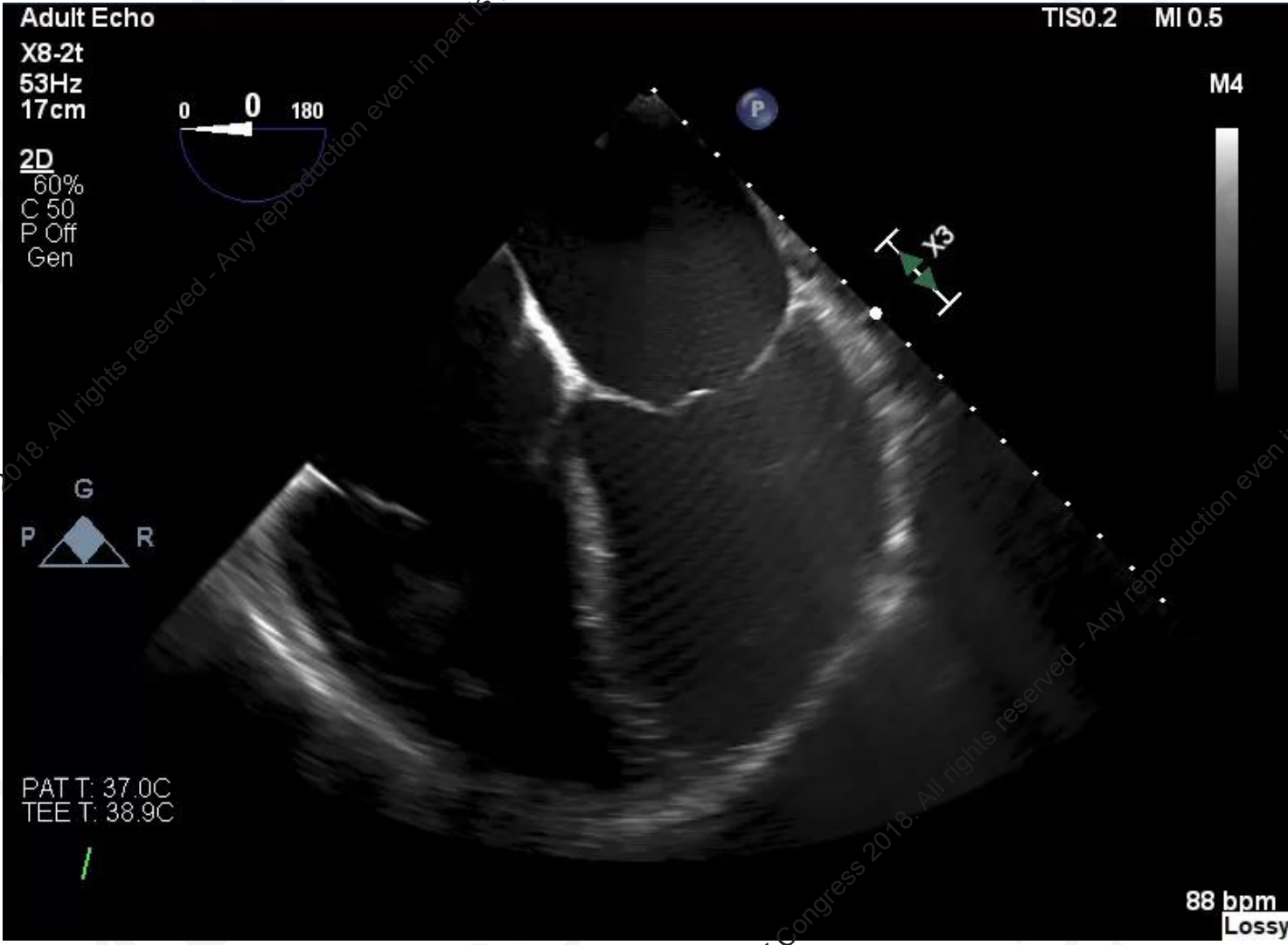
2018 © AICT Congress 2018. All rights reserved - Any reproduction even in part is prohibited.

2018 © AICT Congress 2018. All rights reserved - Any reproduction even in part is prohibited.

# Baseline Echocardiogram

EF	25%
LVEDD	62mm
LVESD	59mm
TAPSE	18mm
LAA	40cm <sup>2</sup>
RAA	33cm <sup>2</sup>
E/E'	14
PAP	65 mmHg

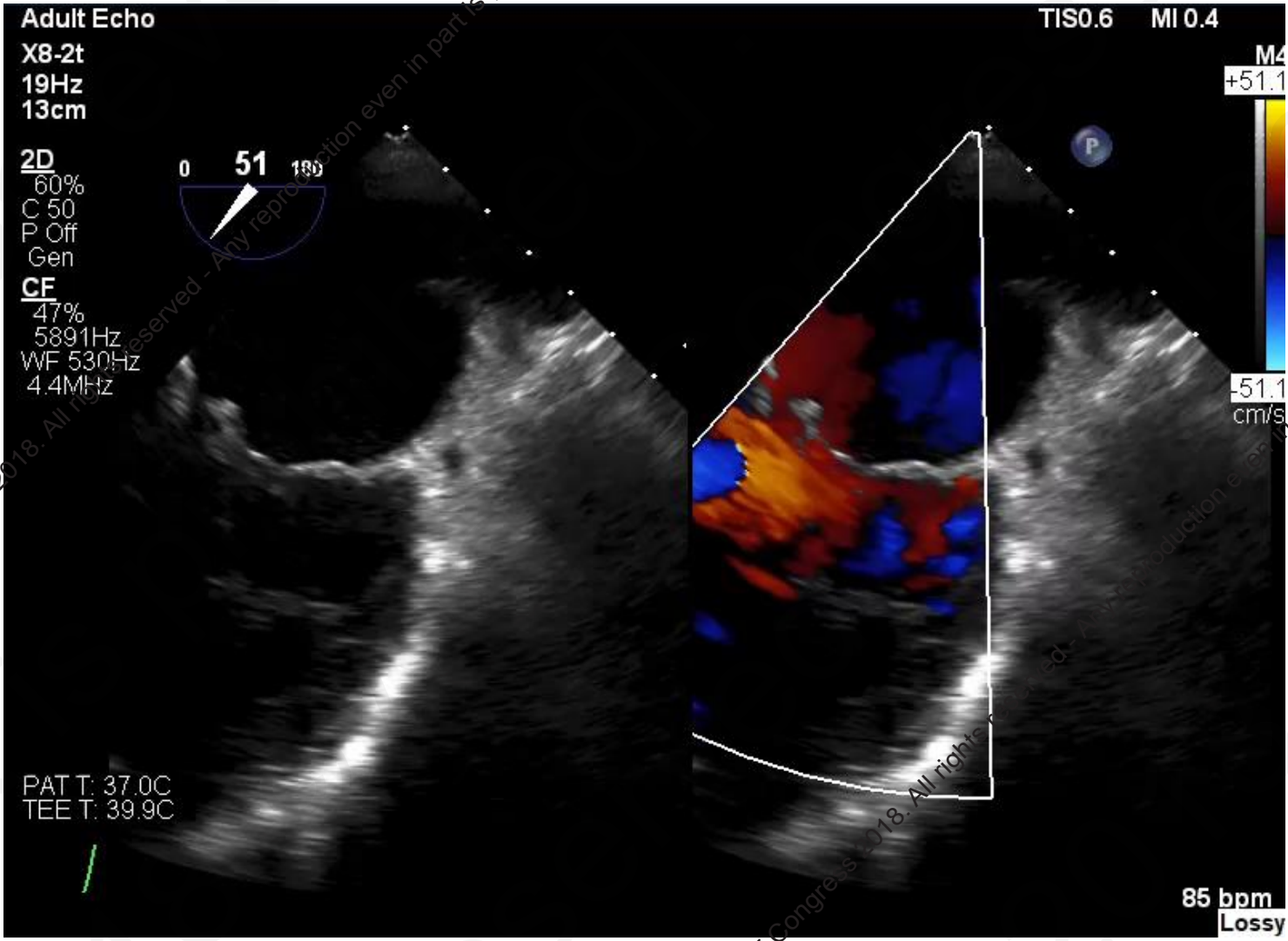
**Severe MR** ( mixed aetiology), abnormal thickening on anterior mitral valve leaflet tip  
**Mild-moderate AR**  
**Moderate TR**



2018 © AICT Congress 2018. All rights reserved - Any reproduction even in part is prohibited.

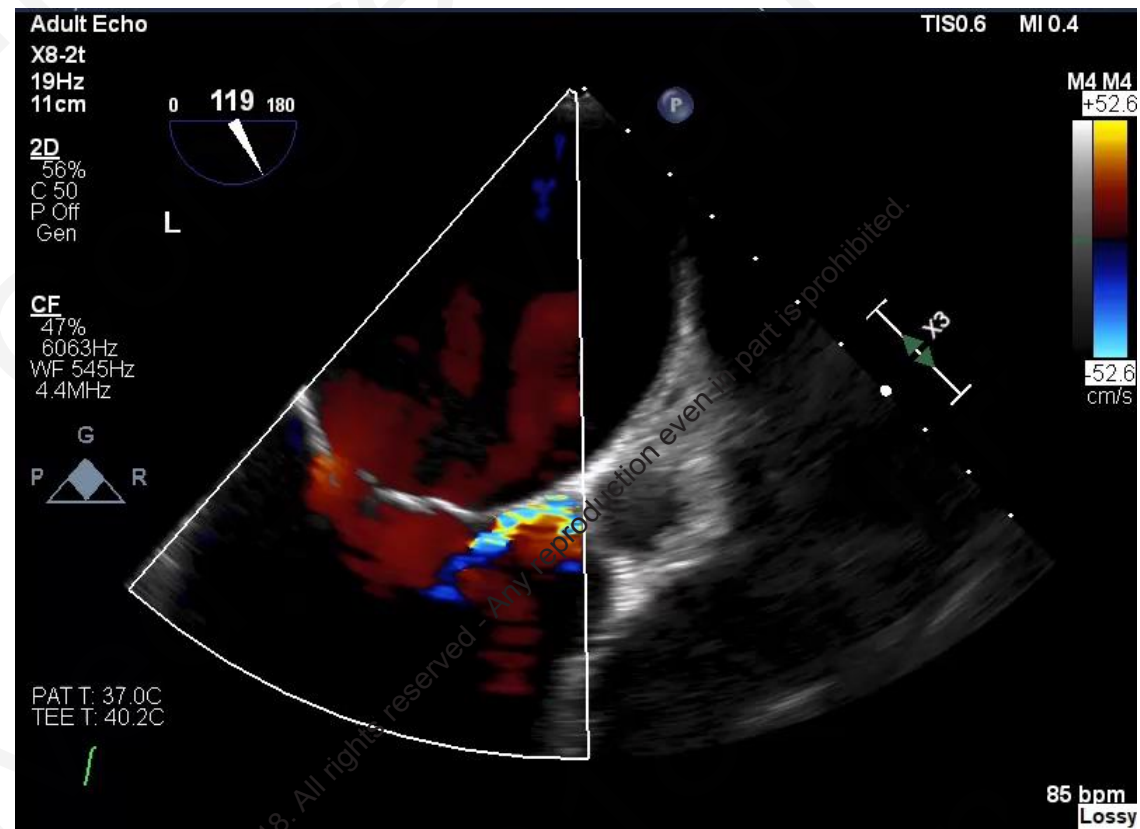
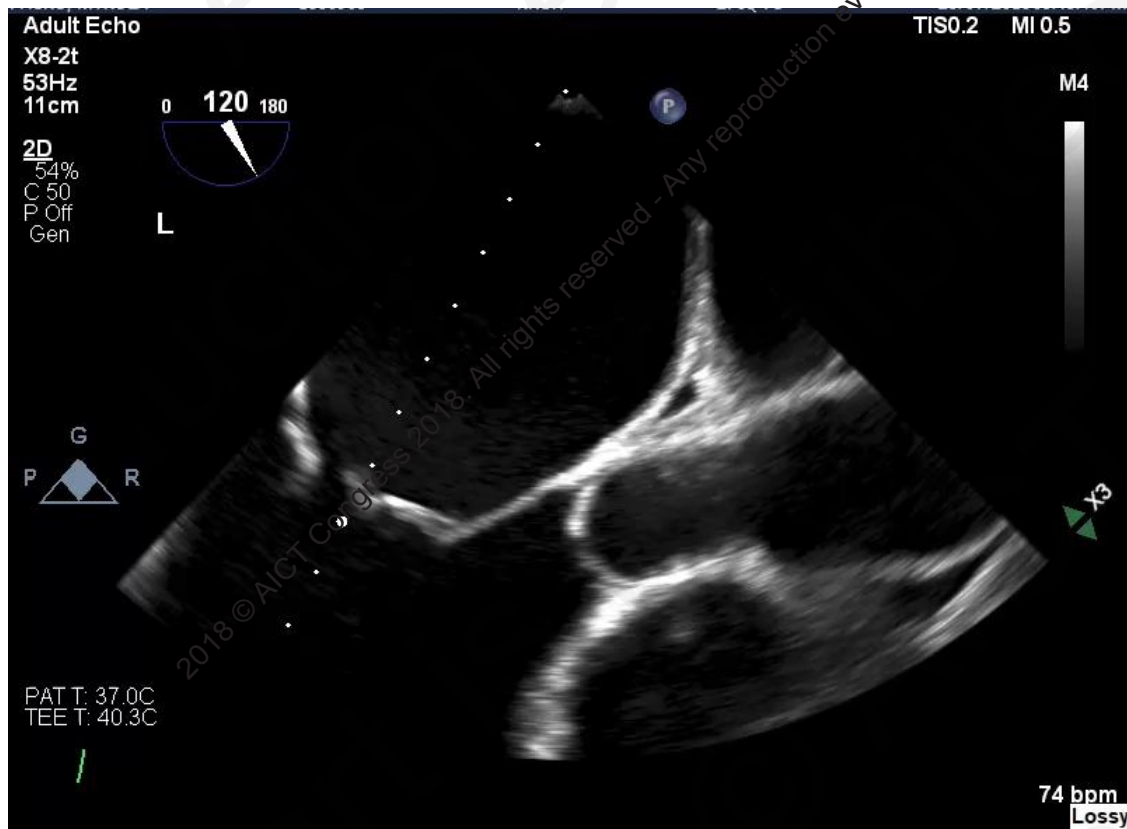2018 © AICT Congress 2018. All rights reserved - Any reproduction even in part is prohibited.





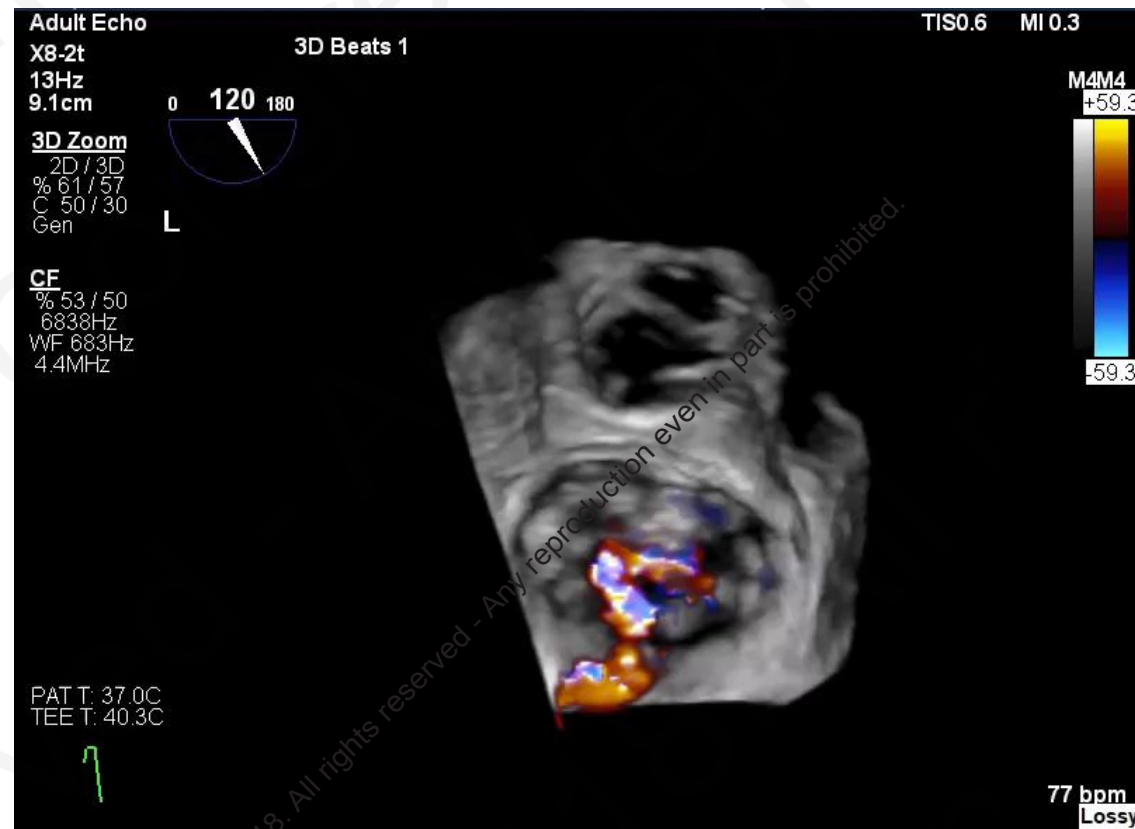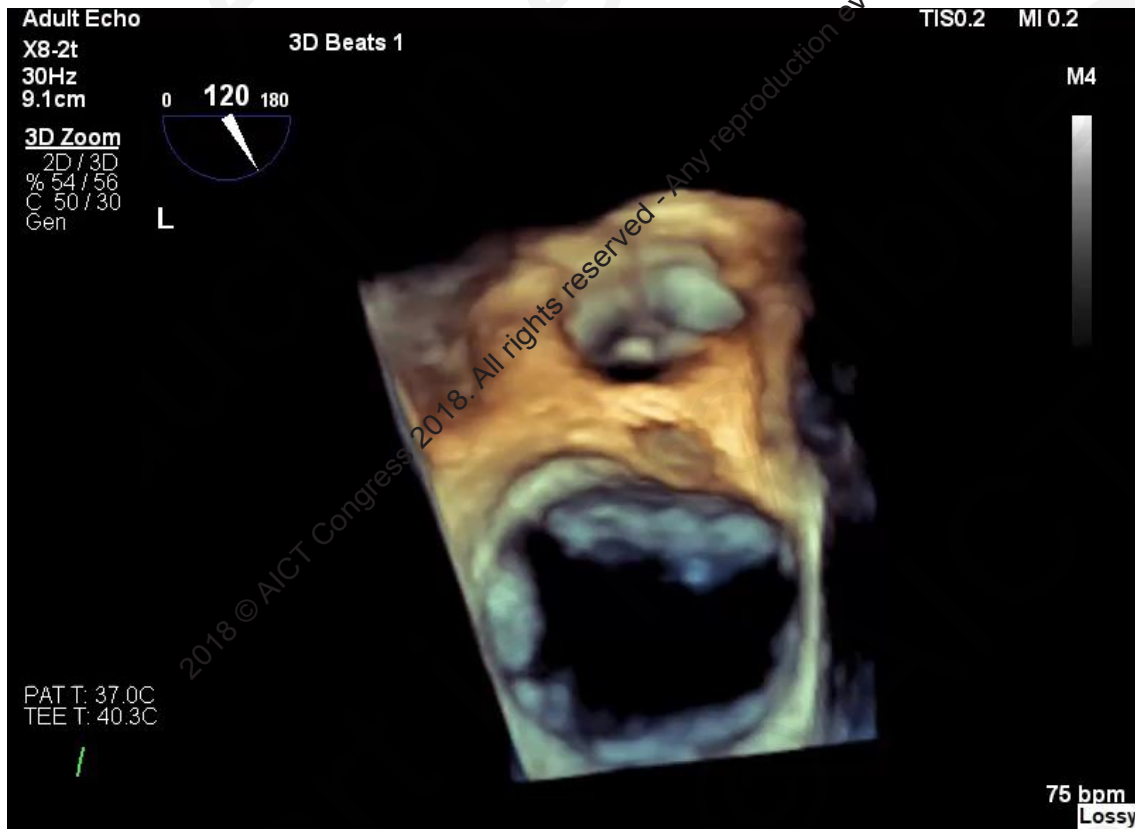
2018 © AICT Congress 2018. All rights reserved - Any reproduction even in part is prohibited.

2018 © AICT Congress 2018. All rights reserved - Any reproduction even in part is prohibited.



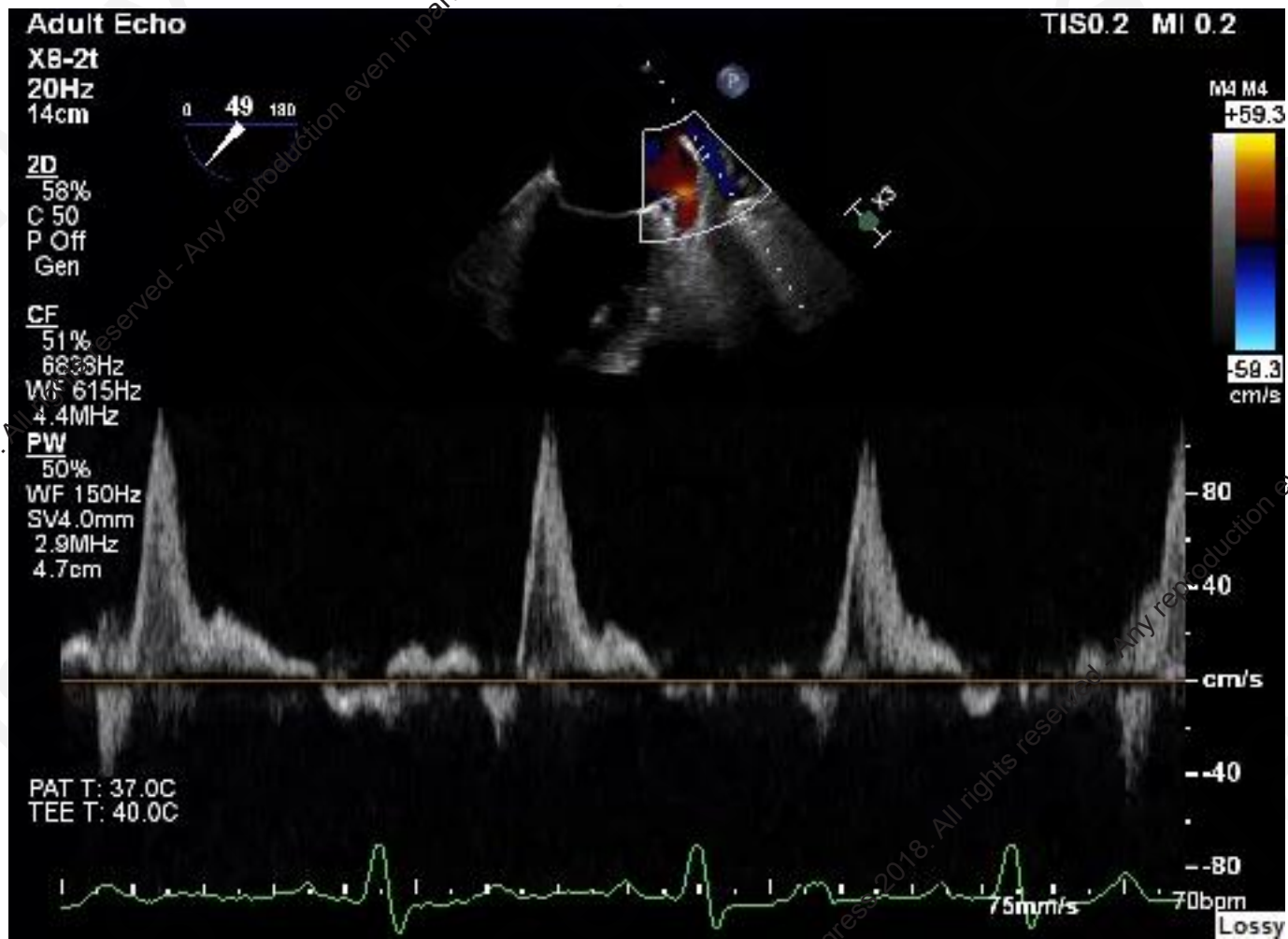
All rights reserved - Any reproduction even in part is prohibited.

All rights reserved - Any reproduction even in part is prohibited.



All rights reserved - Any reproduction even in part is prohibited.

All rights reserved - Any reproduction even in part is prohibited.



2018 © AICT Congress 2018. All rights reserved. Any reproduction even in part is prohibited.

2018 © AICT Congress 2018. All rights reserved. Any reproduction even in part is prohibited.

# Summary

- 80year old male with worsening Heart failure
- Maximal tolerated medical therapy
- Severe MR ( mixed aetiology)
- Severe LV dysfunction
- Severe Pulmonary HT
- Moderate TR

14<sup>th</sup>

# AICT

ASIAN INTERVENTIONAL CARDIOVASCULAR THERAPEUTICS  
THE OFFICIAL CONGRESS OF APSIC



2018 © AICT Congress 2018. All rights reserved - Any reproduction even in part is prohibited.

2018 © AICT Congress 2018. All rights reserved - Any reproduction even in part is prohibited.

**7 - 9th September 2018**

**Hong Kong**

Convention and Exhibition Centre (HKCEC)