

14th

AICT

ASIAN INTERVENTIONAL CARDIOVASCULAR THERAPEUTICS
THE OFFICIAL CONGRESS OF APSIC

Acute coronary syndrome Insight from OCT

Dr Chan Ka Chun Alan
Department of Medicine
Queen Elizabeth Hospital

2018 © AICT Congress 2018. All rights reserved - Any reproduction even in part is prohibited.

2018 © AICT Congress 2018. All rights reserved - Any reproduction even in part is prohibited.



Conflicts of Interest

Speaker's name : Chan ka Chun Alan, Queen Elizabeth Hospital
I do not have any potential conflict of interest

2018 © AICT Congress 2018. All rights reserved - Any reproduction even in part is prohibited.

2018 © AICT Congress 2018. All rights reserved - Any reproduction even in part is prohibited.

- Acute coronary syndrome
 - De novo lesion
 - Late stent failure

Causes of Coronary Thrombosis or Sudden Death

Rupture

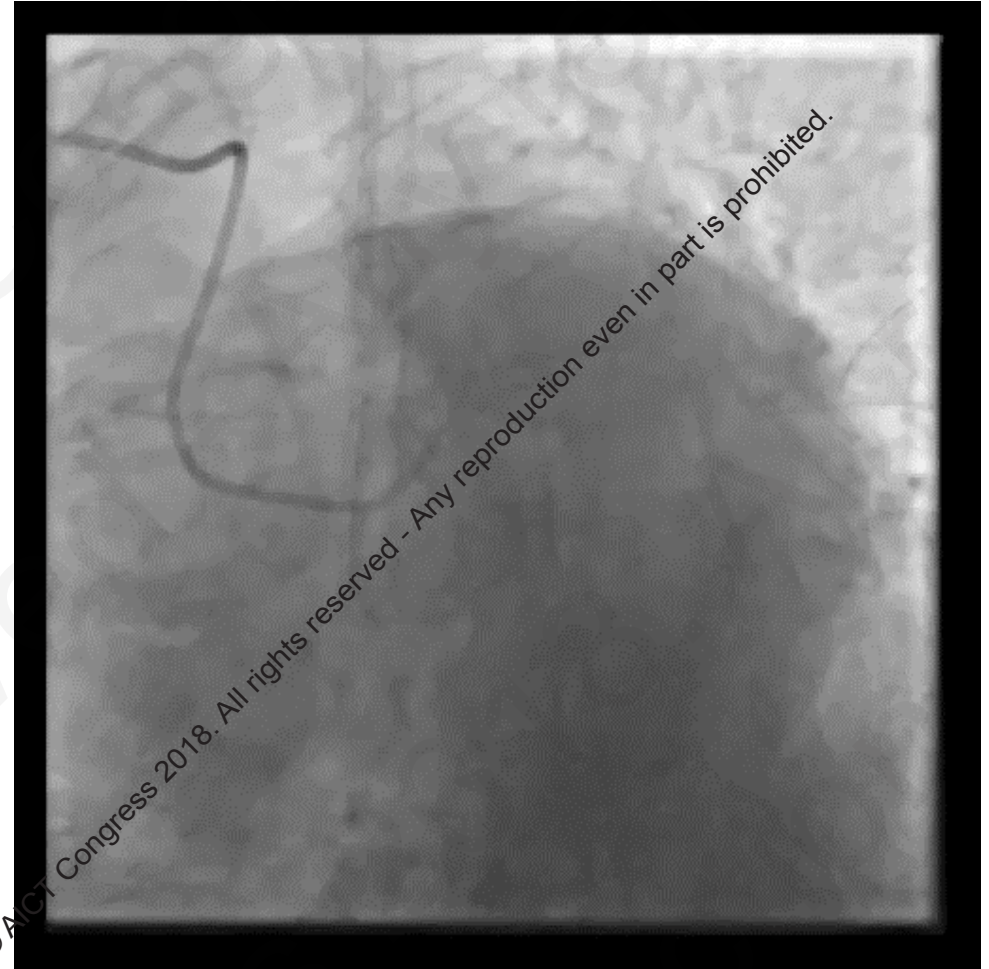
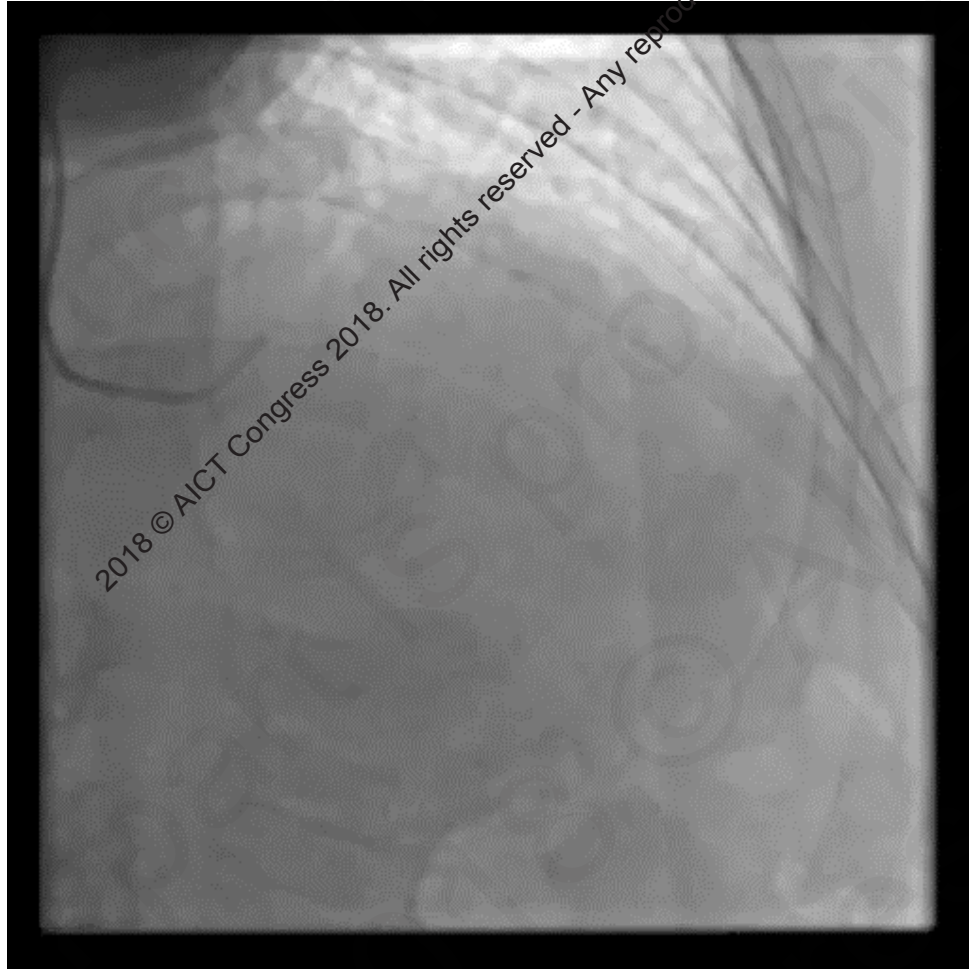
Erosion

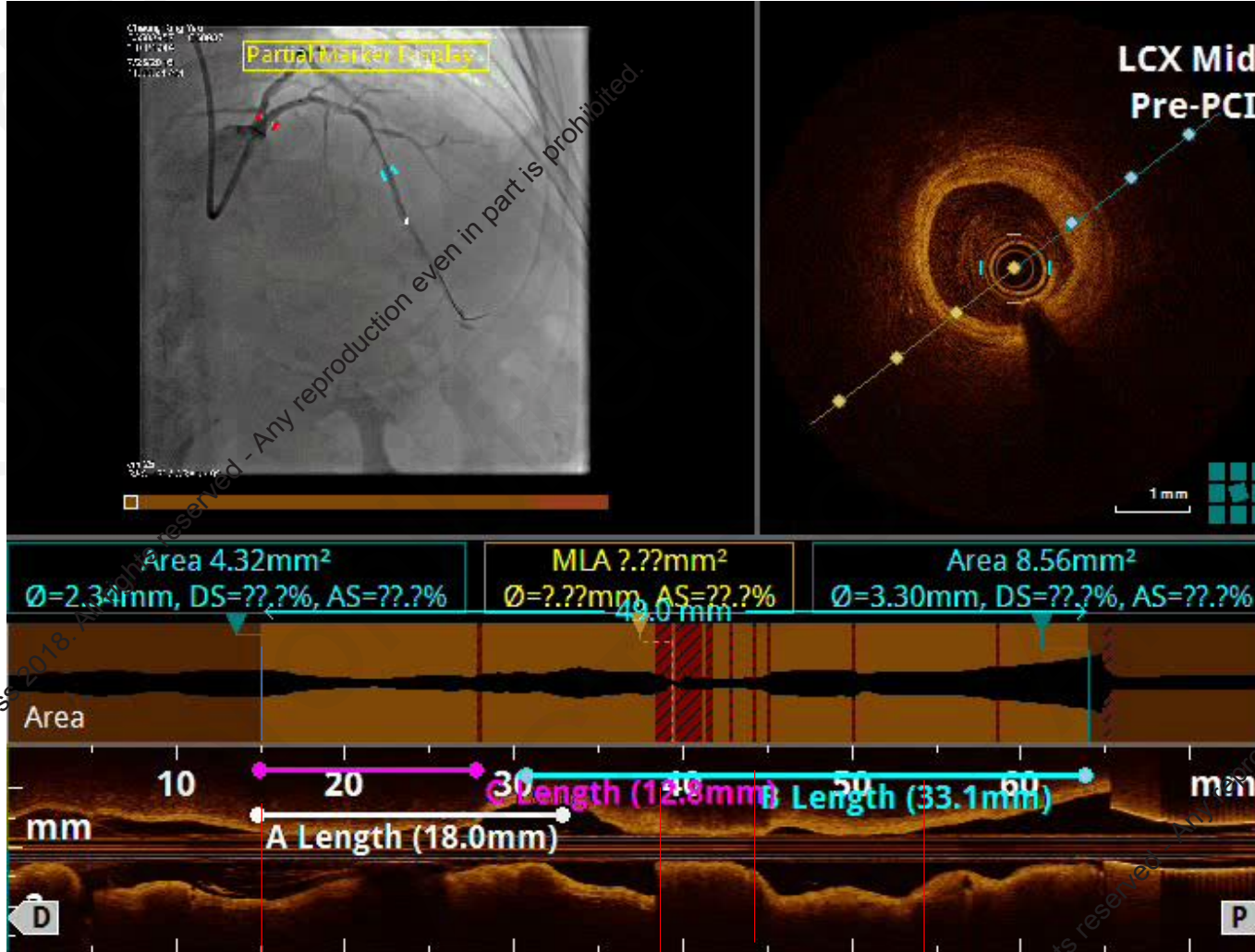
Calcified nodule

2018 © AICT Congress 2018. All rights reserved - Any reproduction even in part is prohibited.

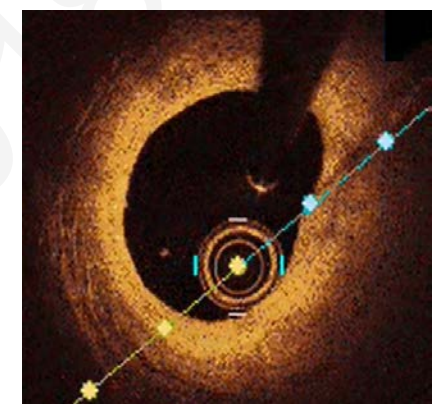
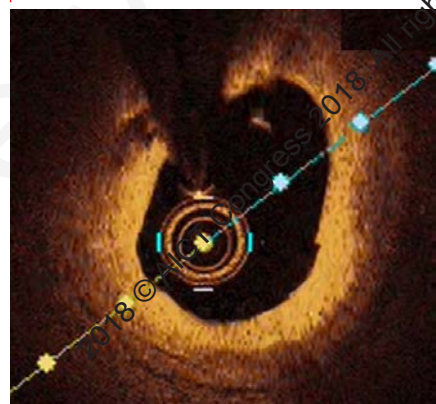
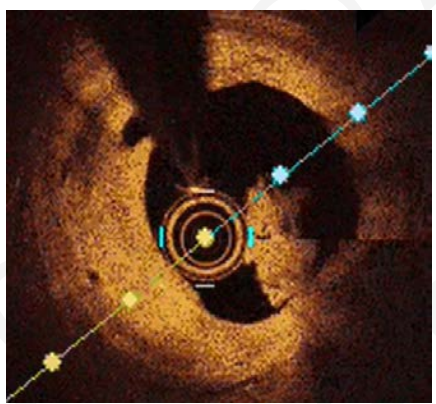
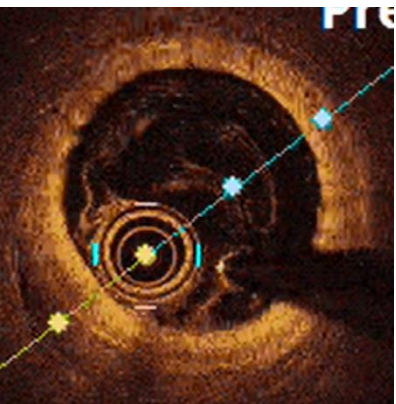
Virmani R, et al. Arterioscler Thromb Vasc Biol 2000;20:1262

Case 1. Anterior MI



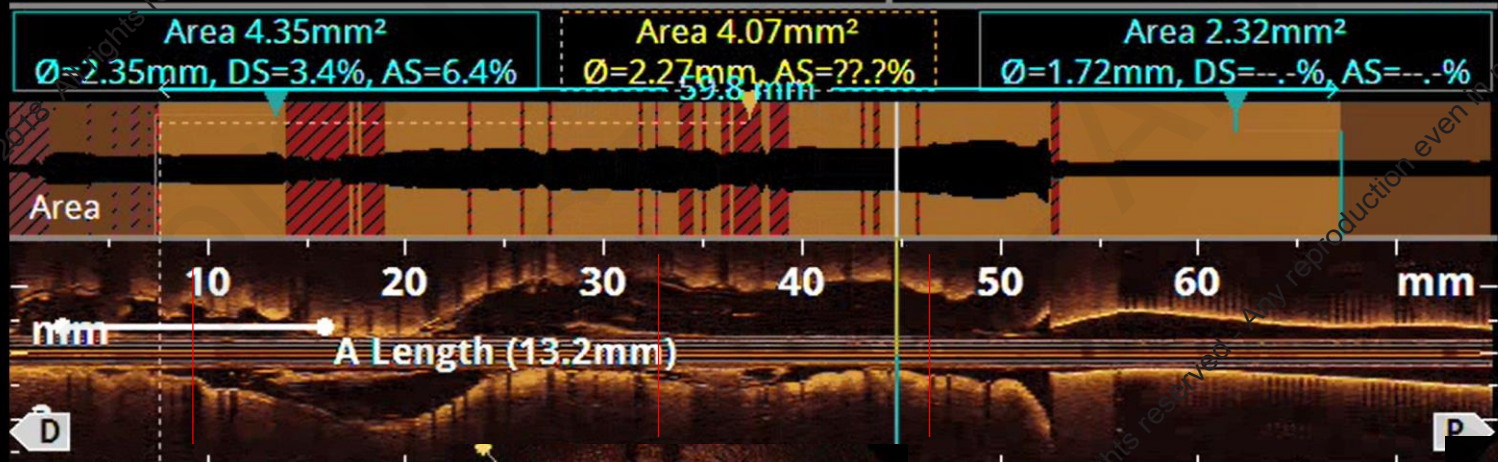
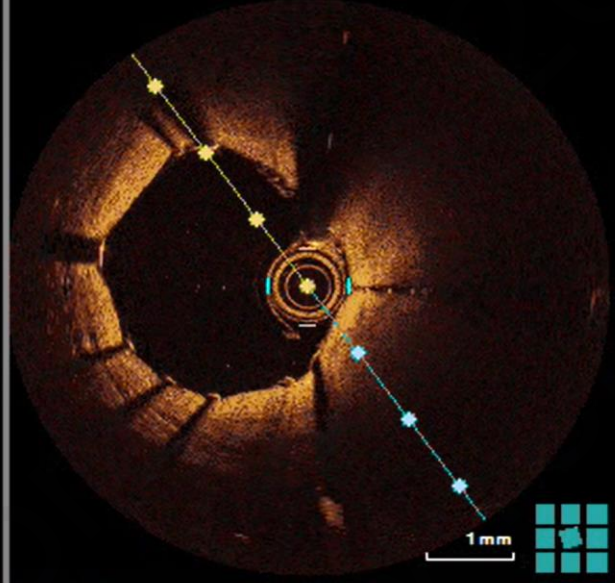
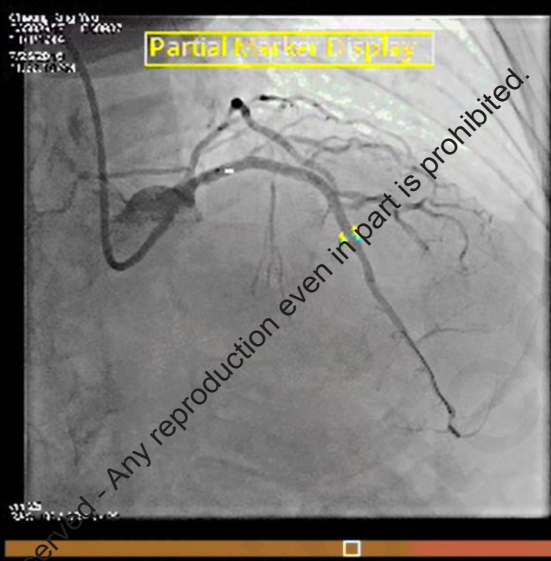


LAD pre-intervention OCT

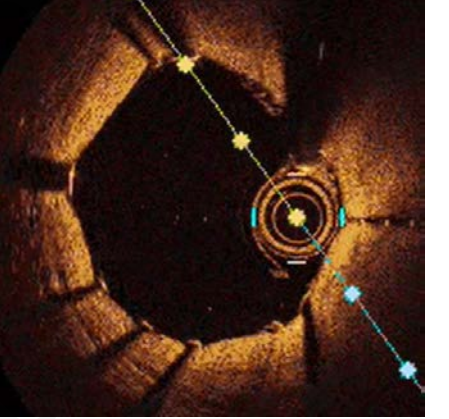

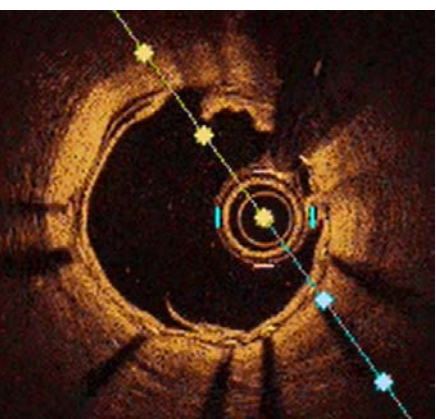


2018 © AICT Congress 2018. All rights reserved. Any reproduction even in part is prohibited.

2018 © AICT Congress 2018. All rights reserved. Any reproduction even in part is prohibited.

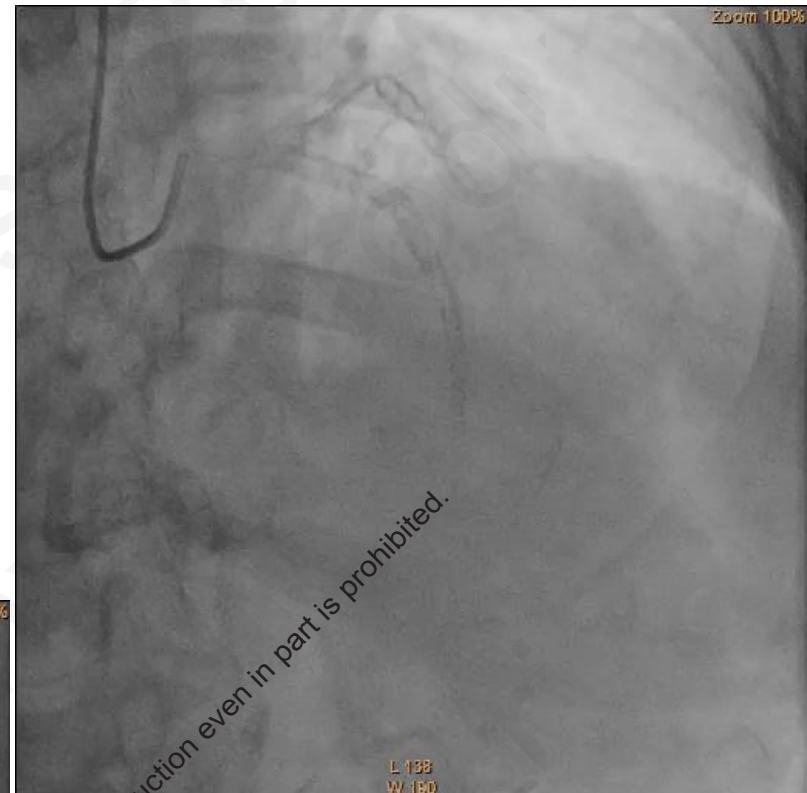
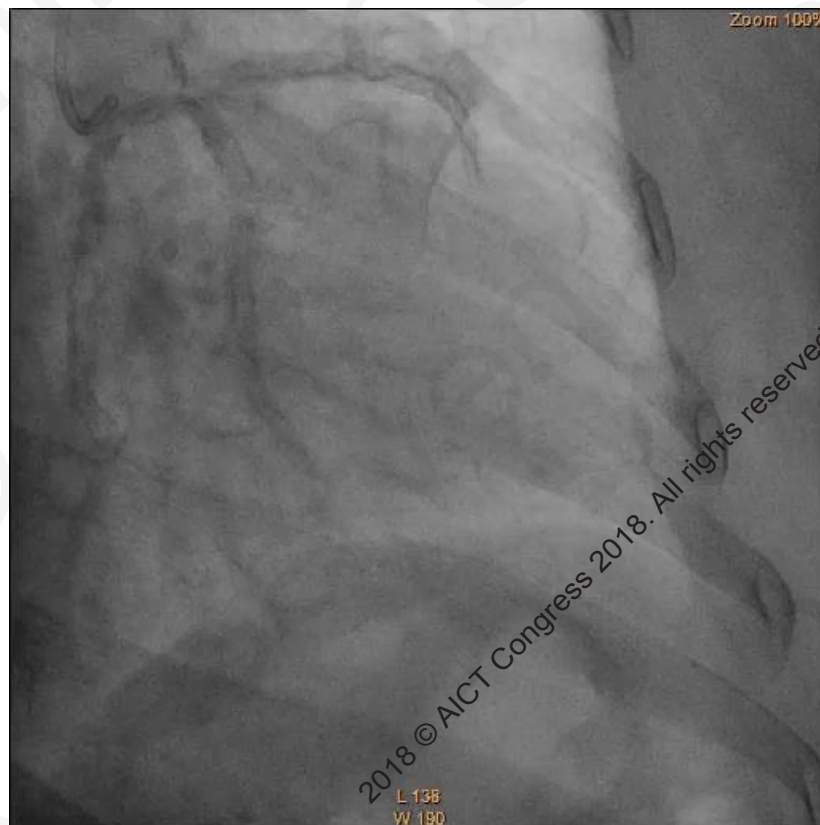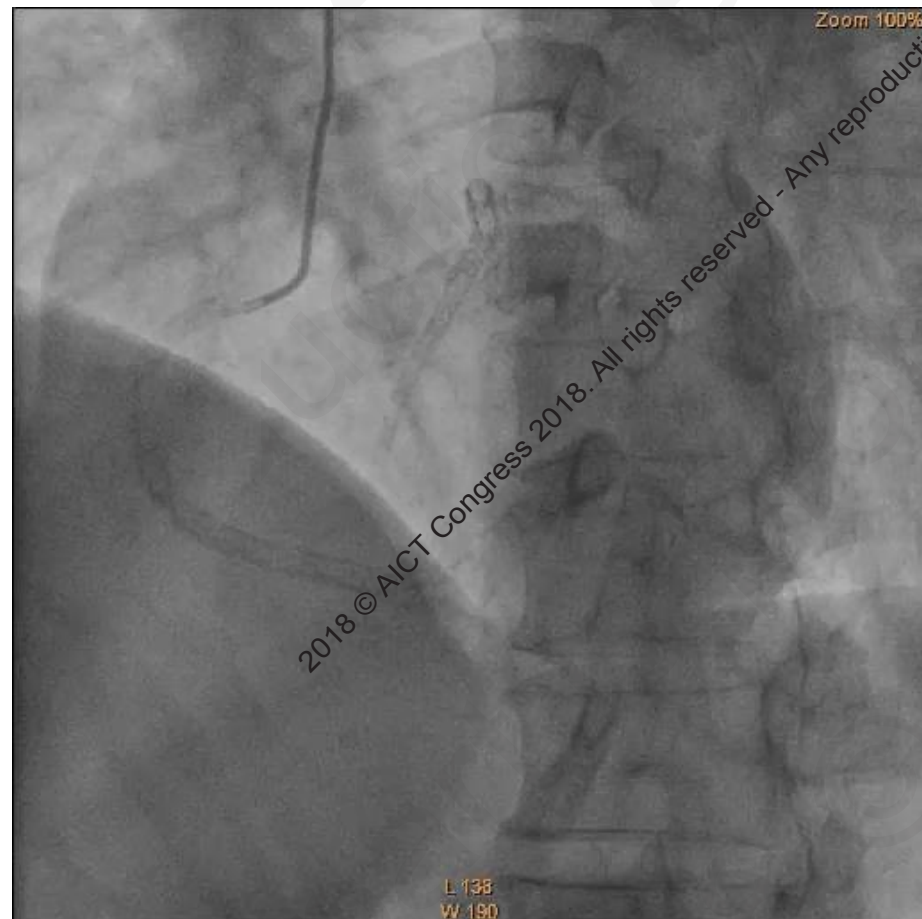


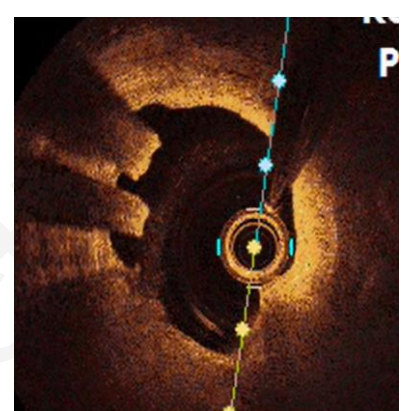
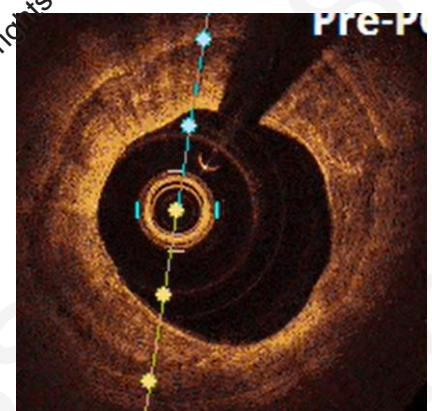
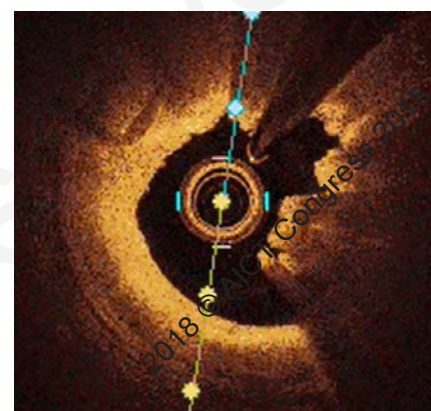
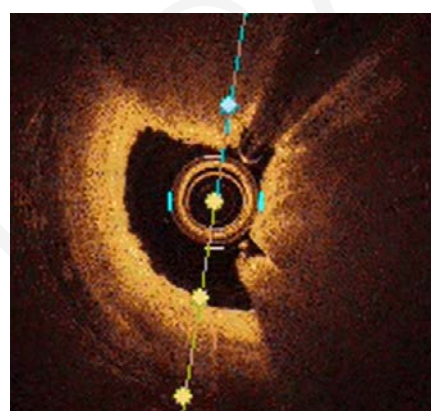
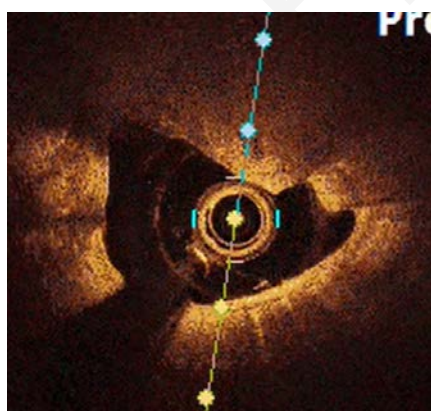
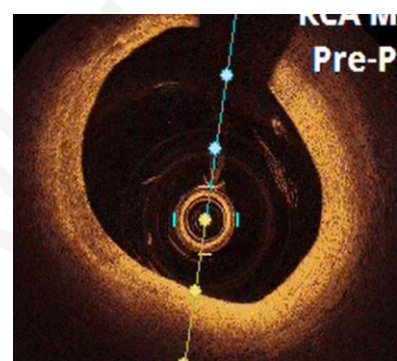
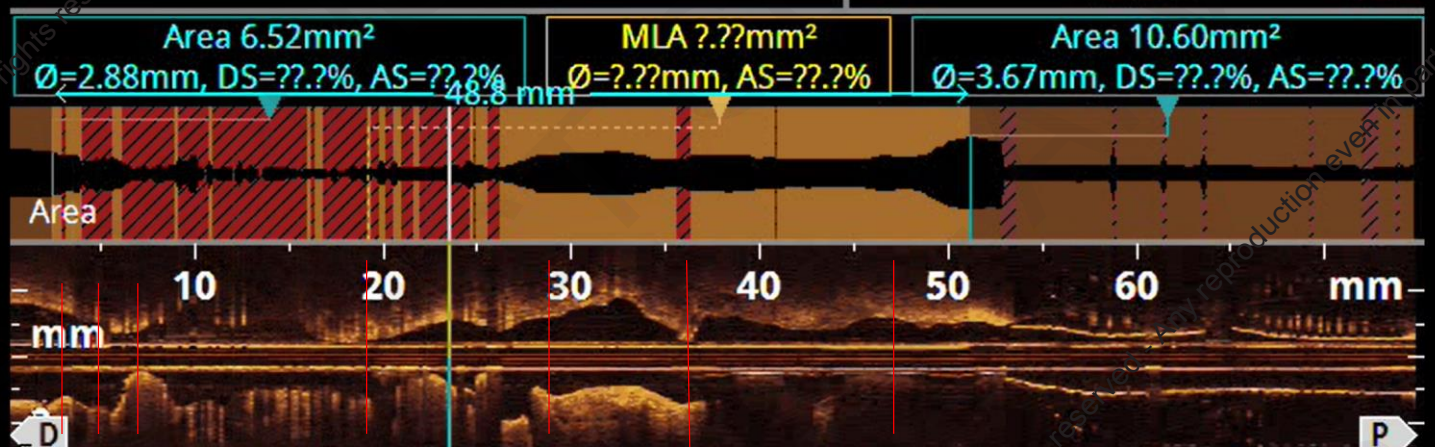
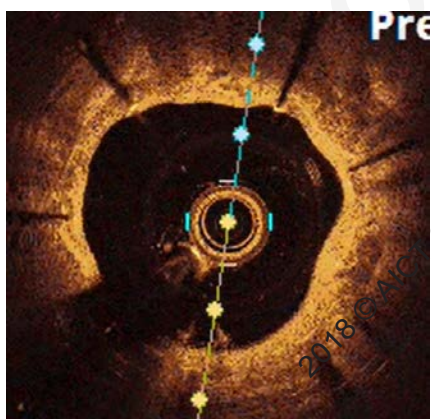
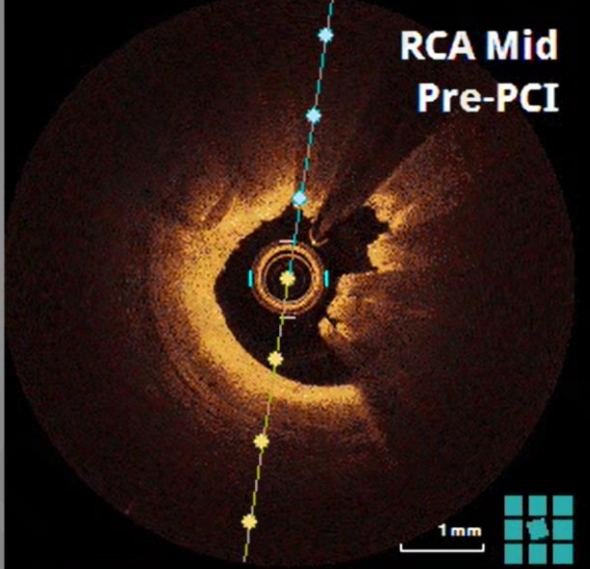
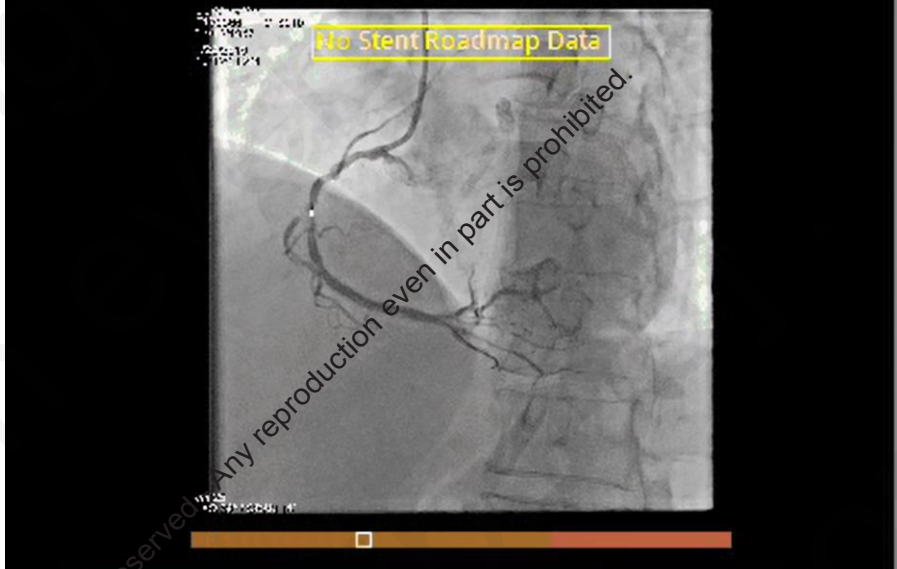
LAD post intervention OCT

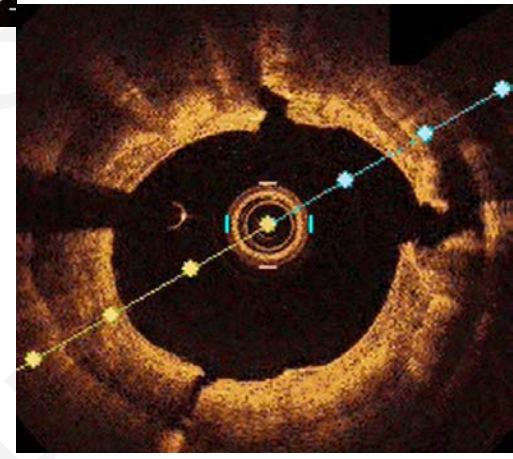
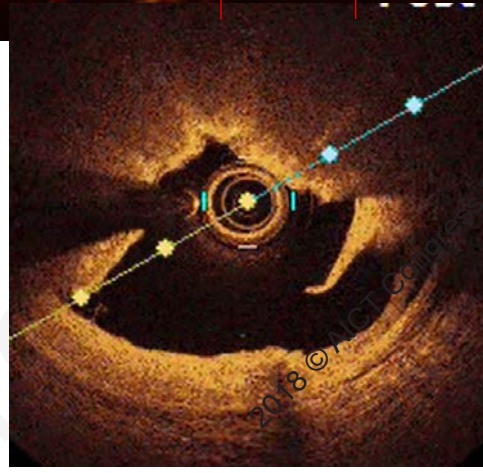
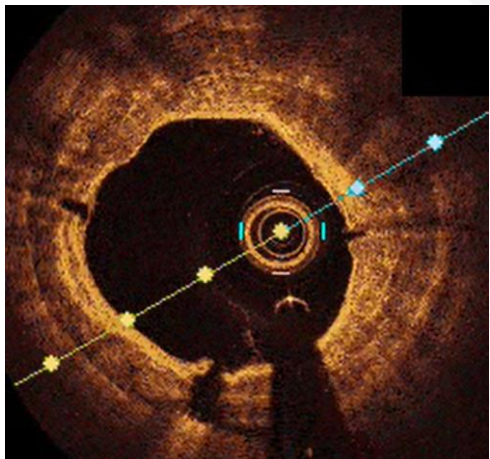
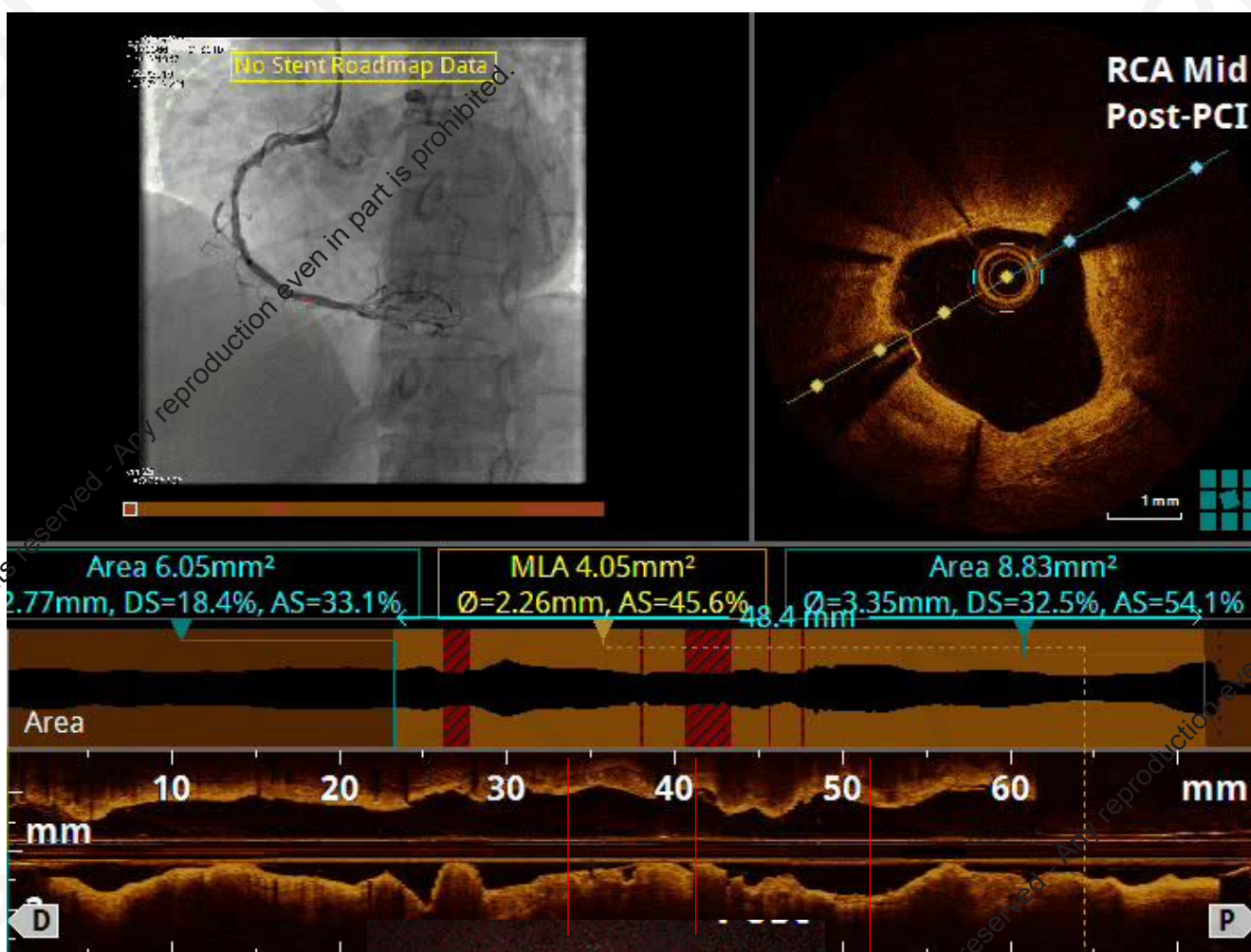


2018 © AICT Congress 2018. All rights reserved. Any reproduction even in part is prohibited.

Case 2. Inferior MI



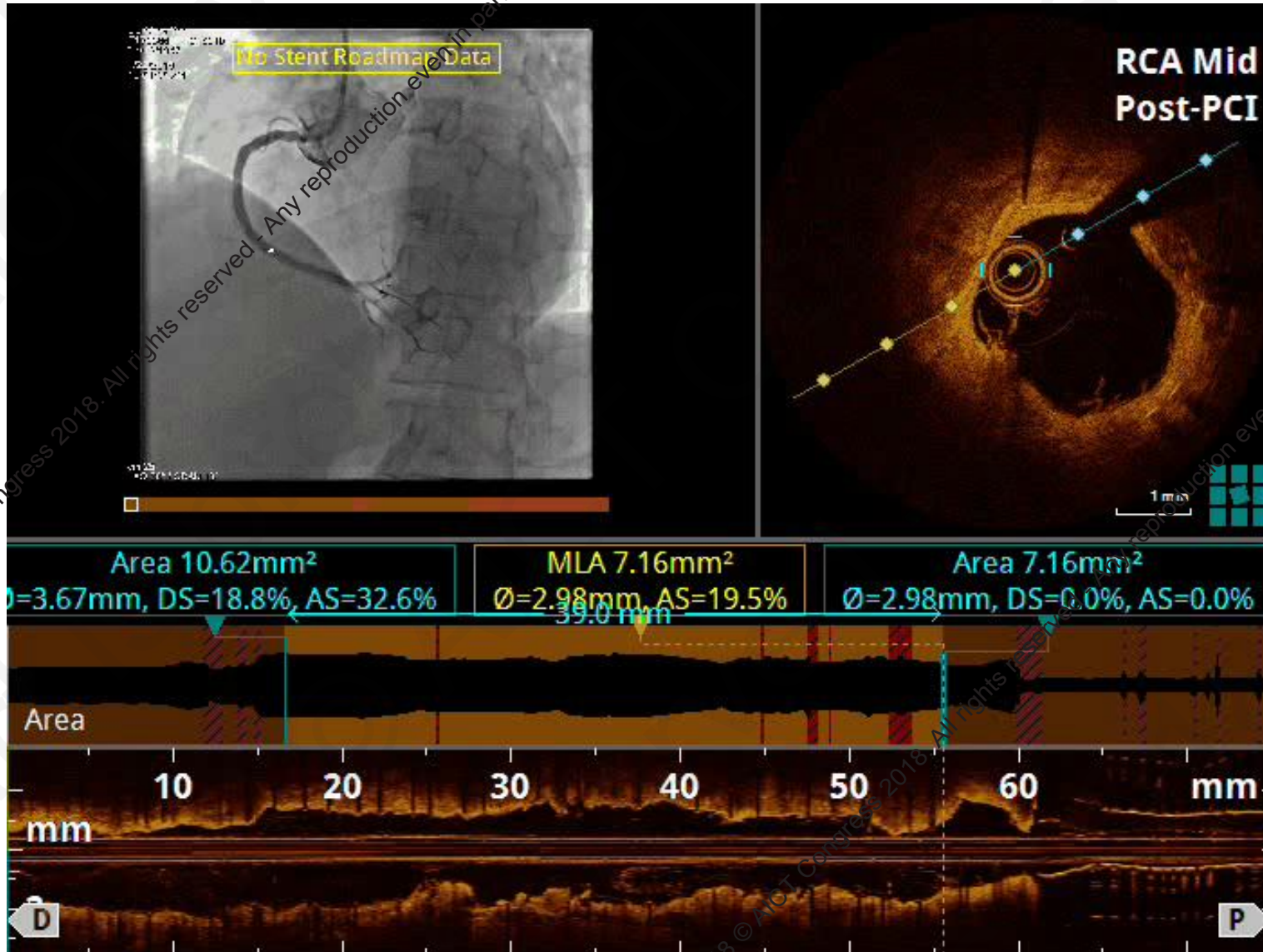




2018 © AICT Congress 2018. All rights reserved - Any reproduction even in part is prohibited.

2018 © AICT Congress 2018. All rights reserved - Any reproduction even in part is prohibited.

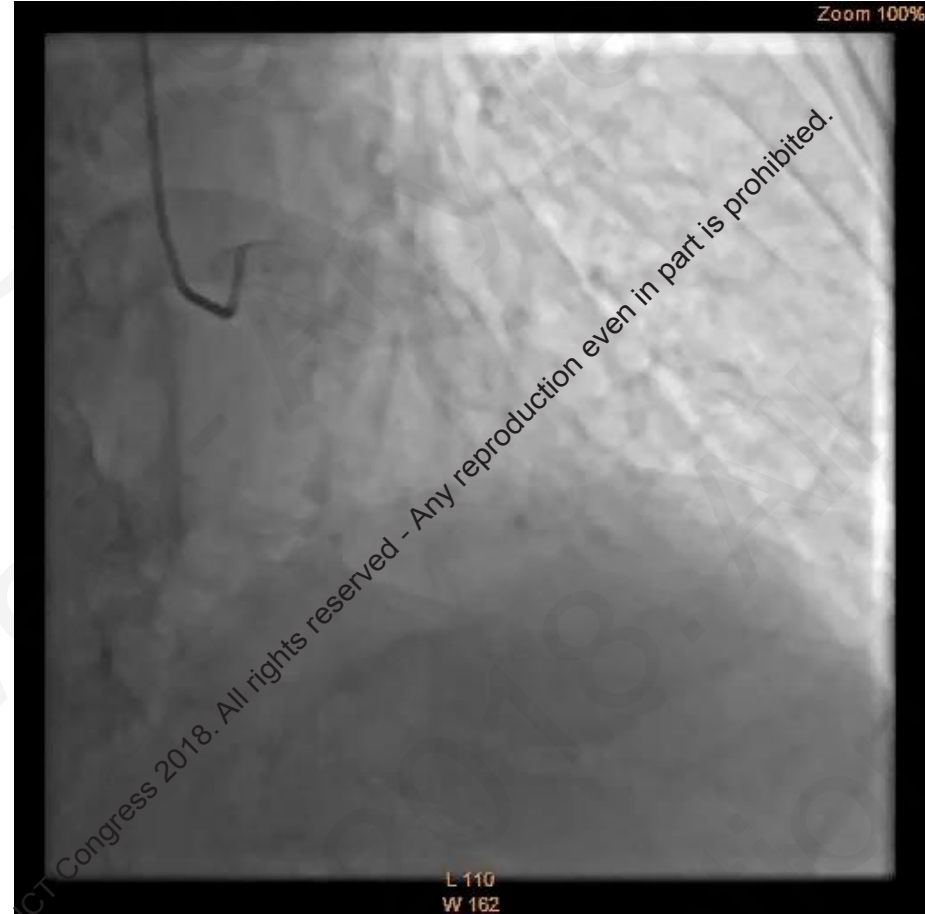POST Intervention OCT



2018 © AICT Congress 2018. All rights reserved. Any reproduction even in part is prohibited.

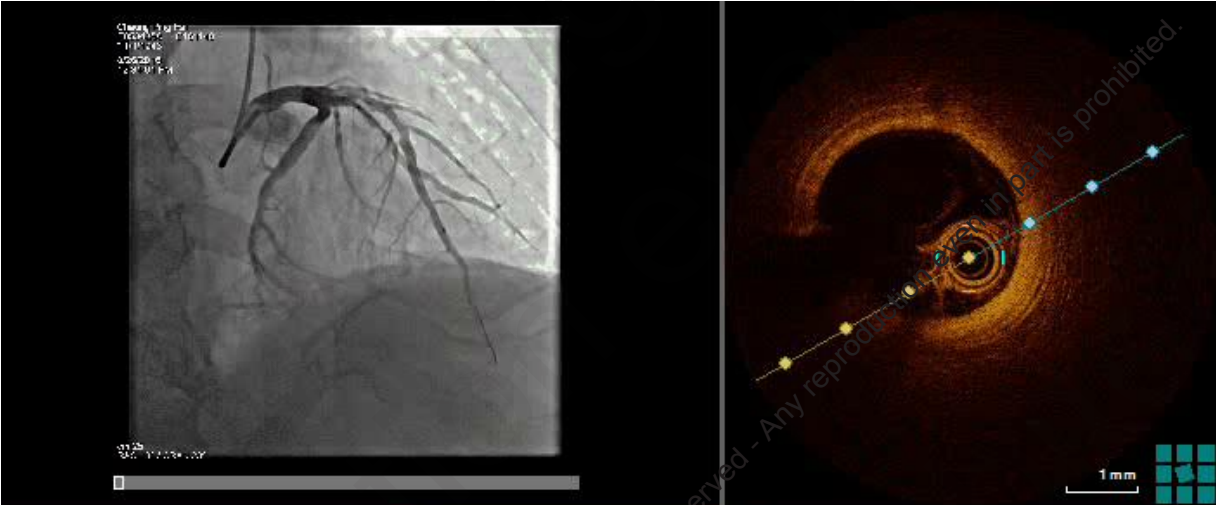
2018 © AICT Congress 2018. All rights reserved. Any reproduction even in part is prohibited.

Case 3 anterior MI

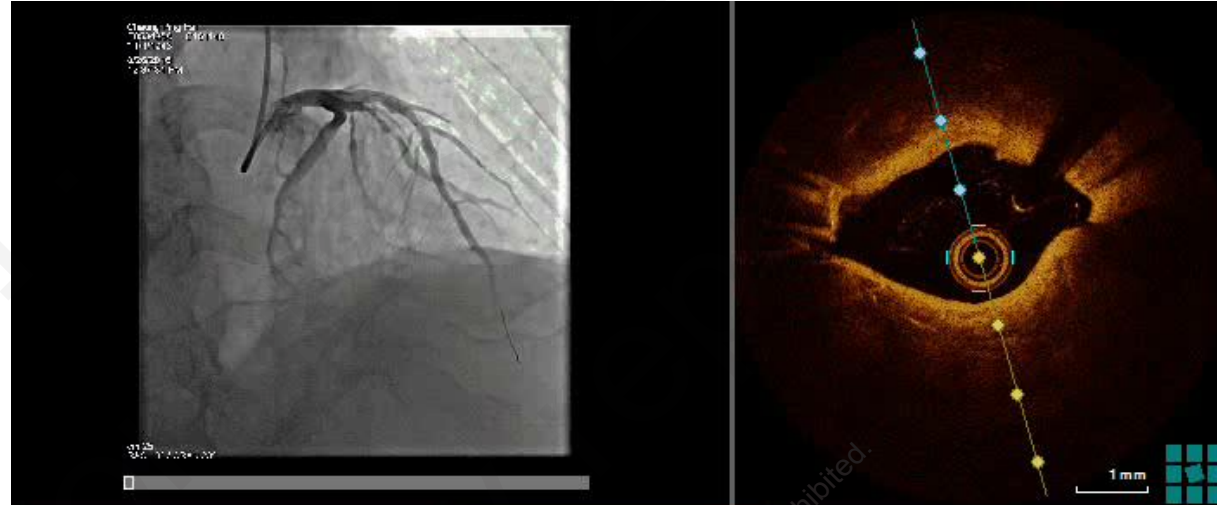
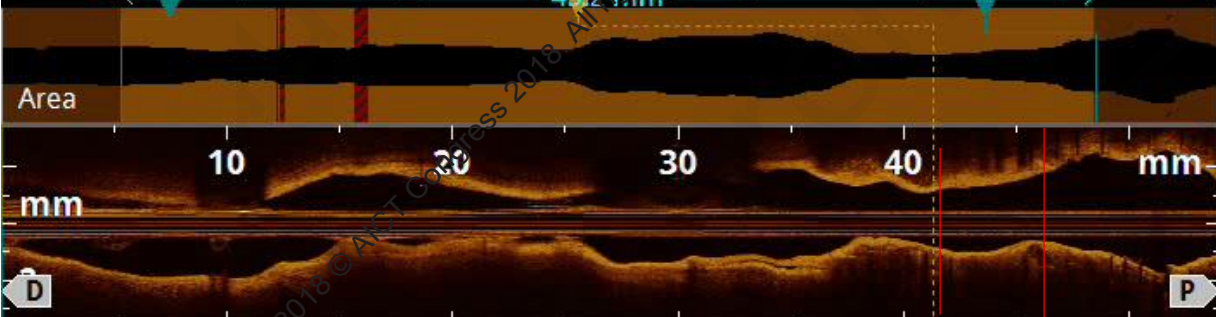


All rights reserved - Any reproduction even in part is prohibited.

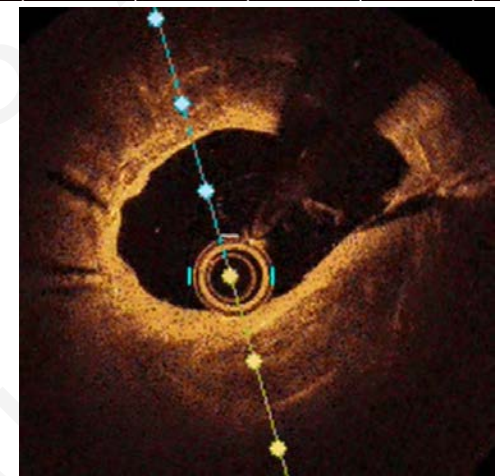
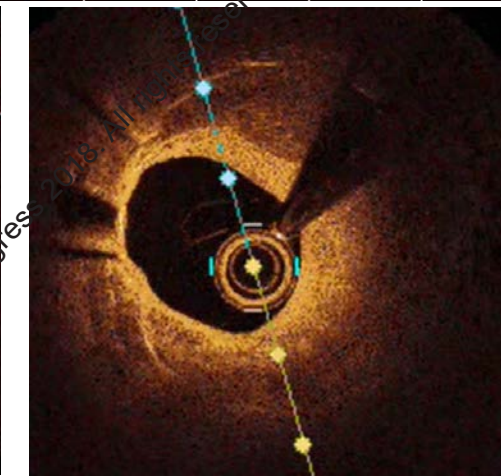
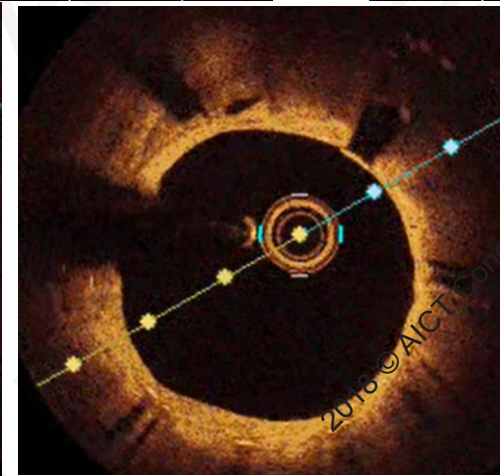
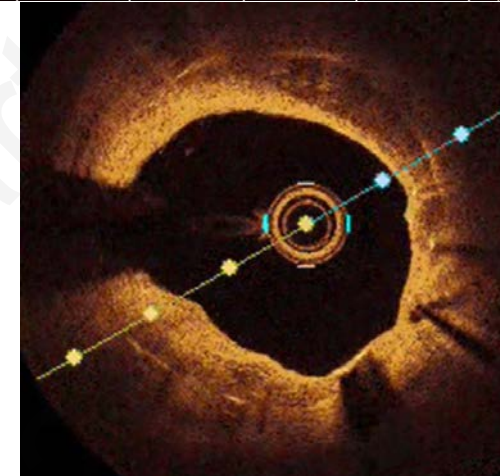
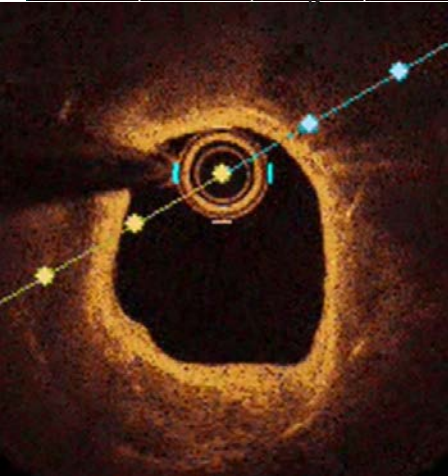
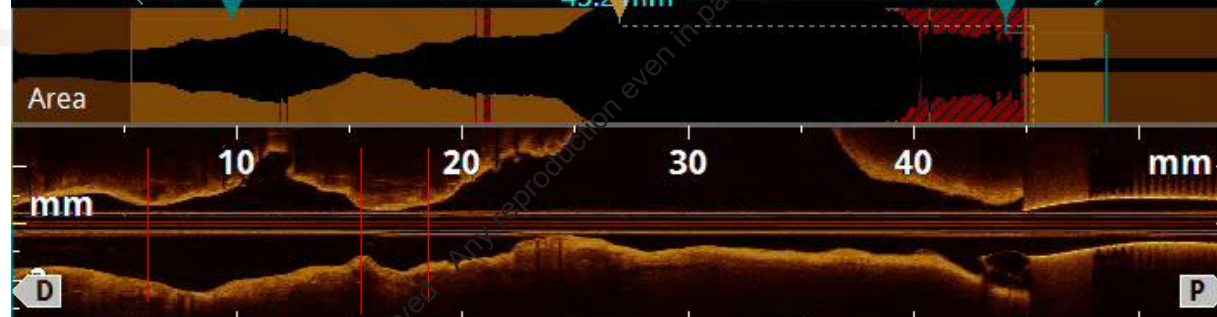All rights reserved - Any reproduction even in part is prohibited.

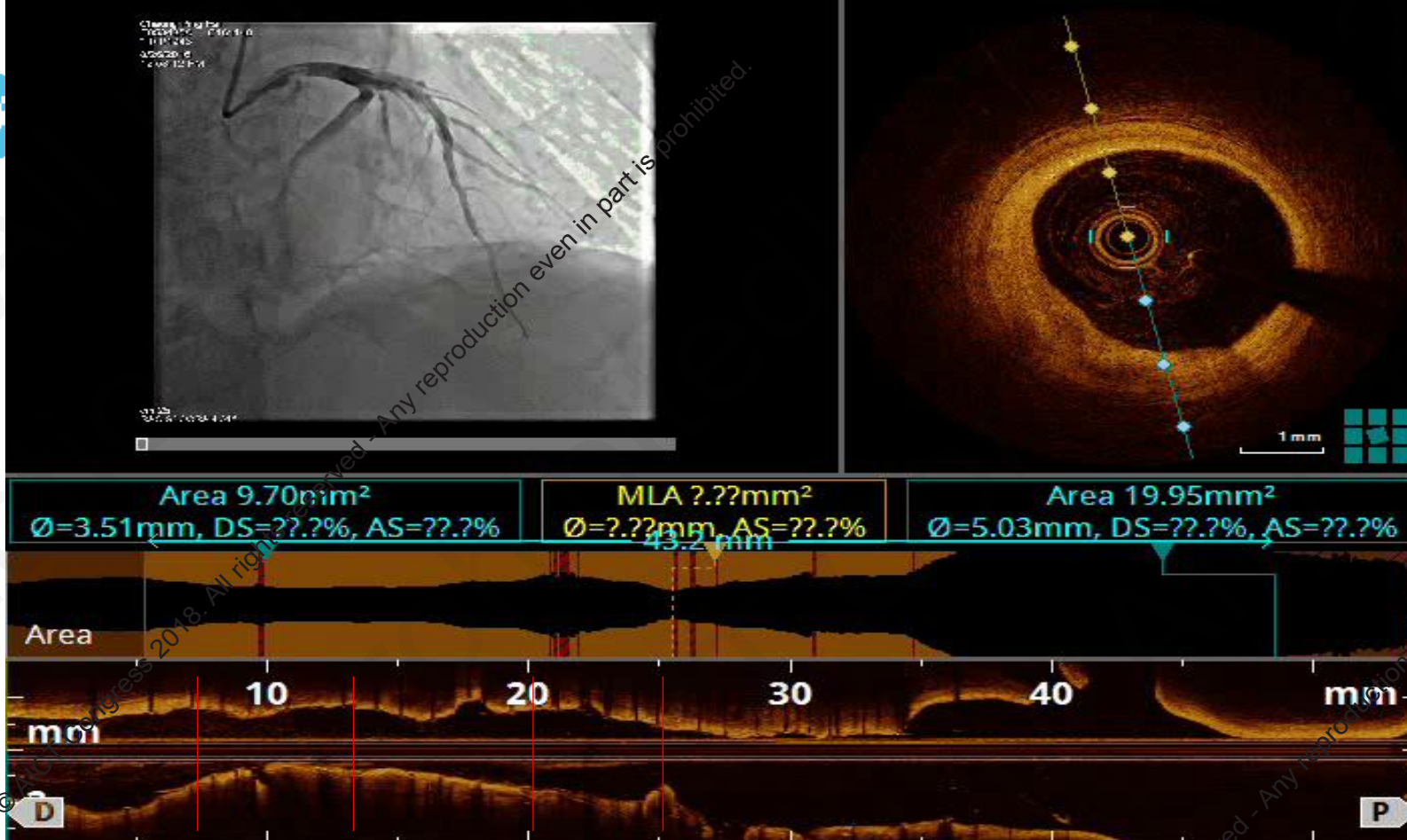


Area 6.74mm ² Ø=2.93mm, DS=26.6%, AS=45.8%	MLA 3.65mm ² Ø=2.15mm, AS=53.7%	Area 9.02mm ² Ø=3.38mm, DS=36.4%, AS=59.5%
--	---	--

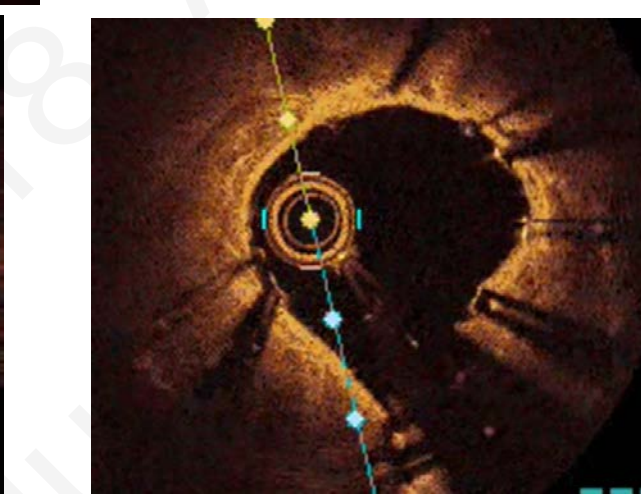
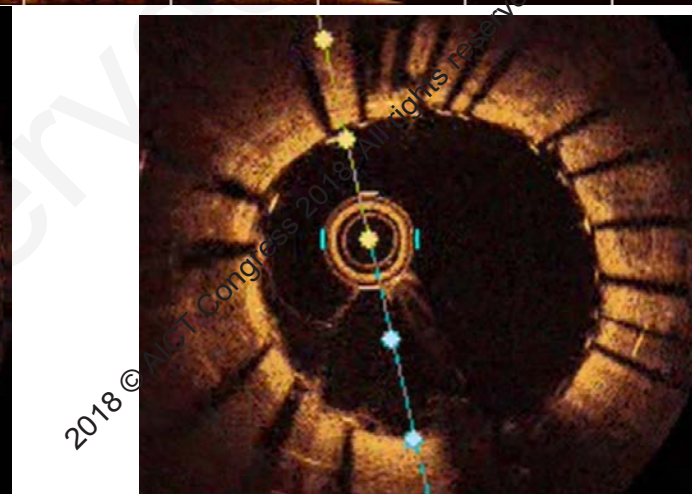
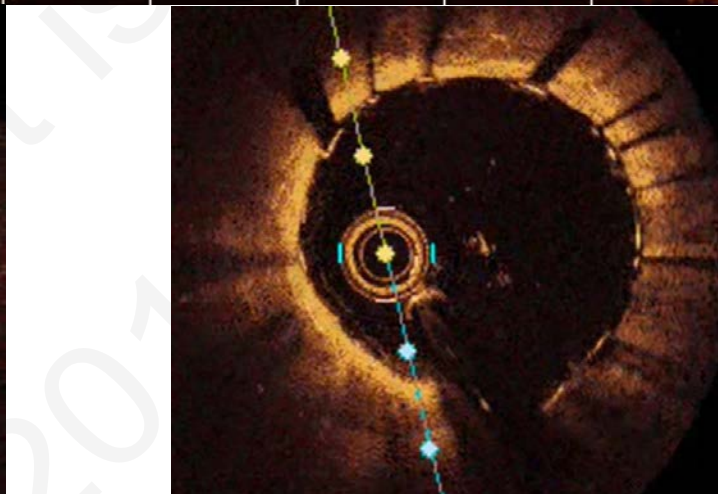
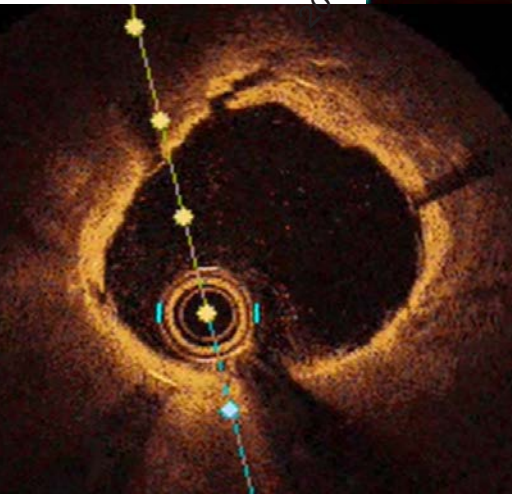


Area 5.41mm ² Ø=2.62mm, DS=???.%, AS=???.%	MLA ???mm ² Ø=???.mm, AS=???.%	Area 2.34mm ² Ø=1.72mm, DS=???.%, AS=???.%
--	--	--





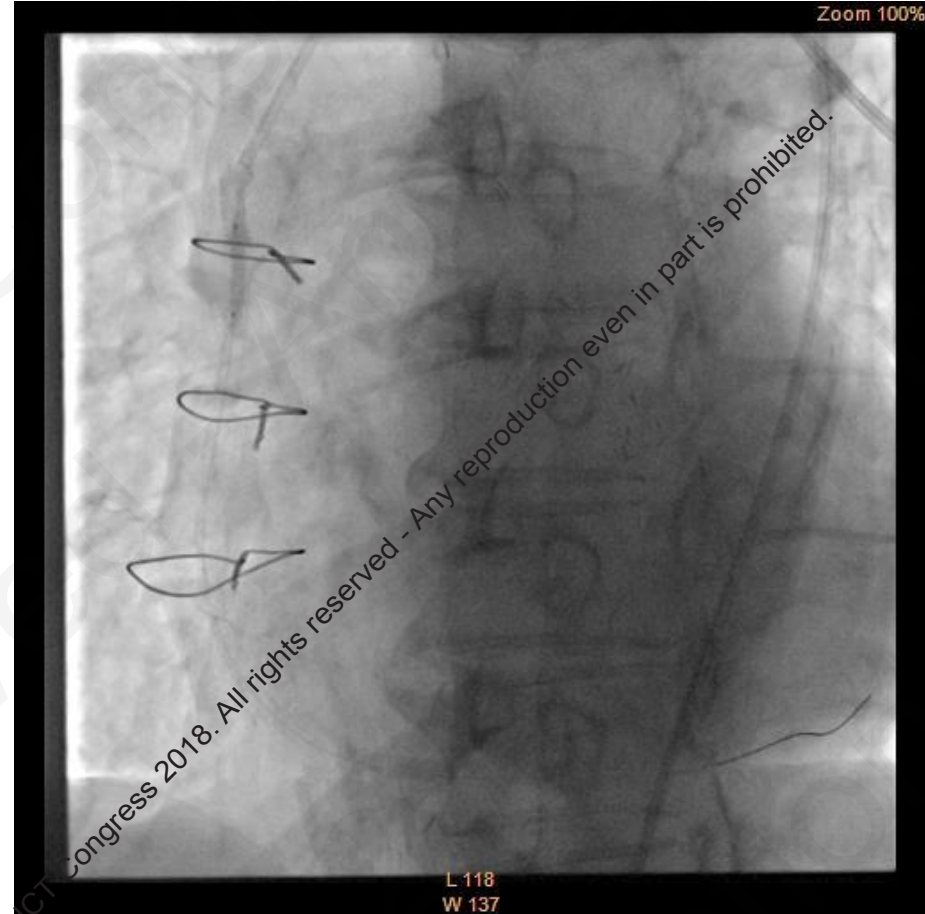
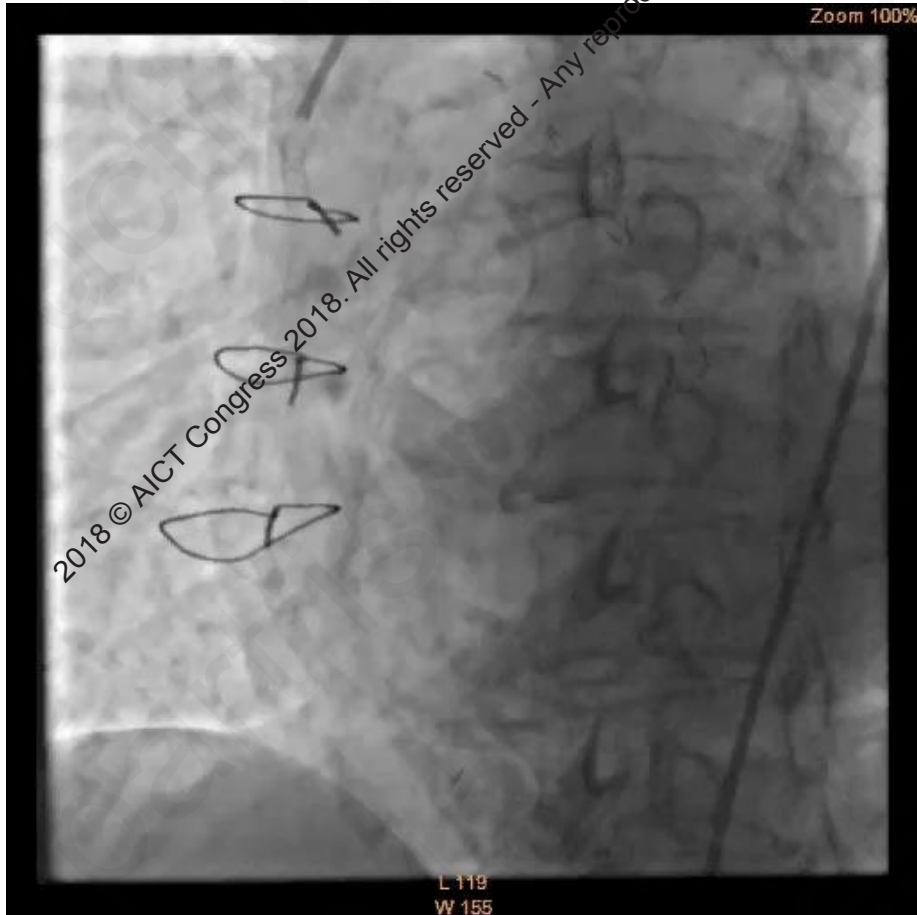
Post stenting OCT



Any reproduction even in part is prohibited.

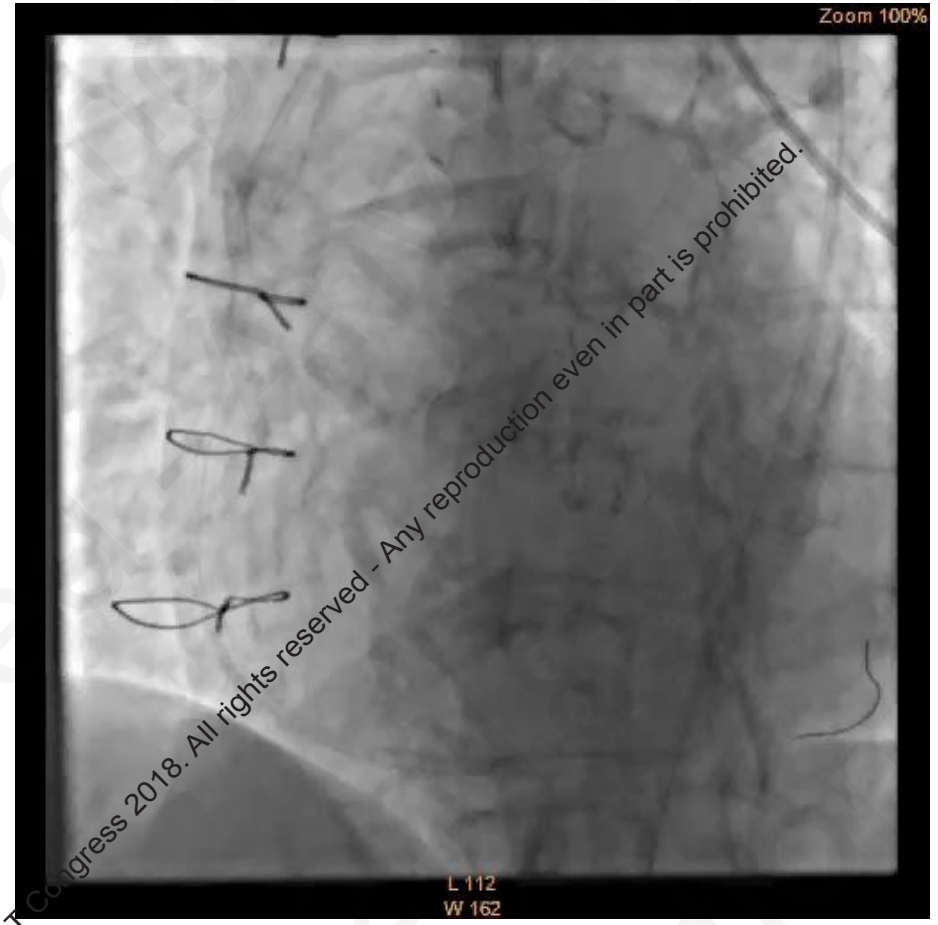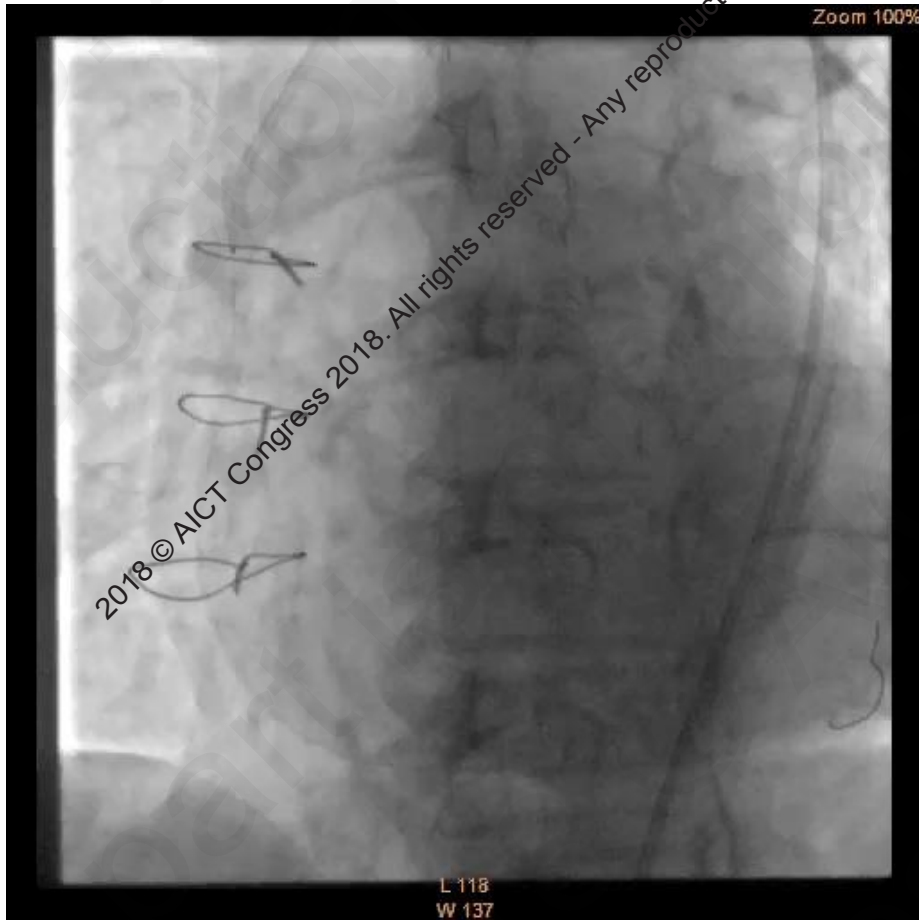Any reproduction even in part is prohibited.

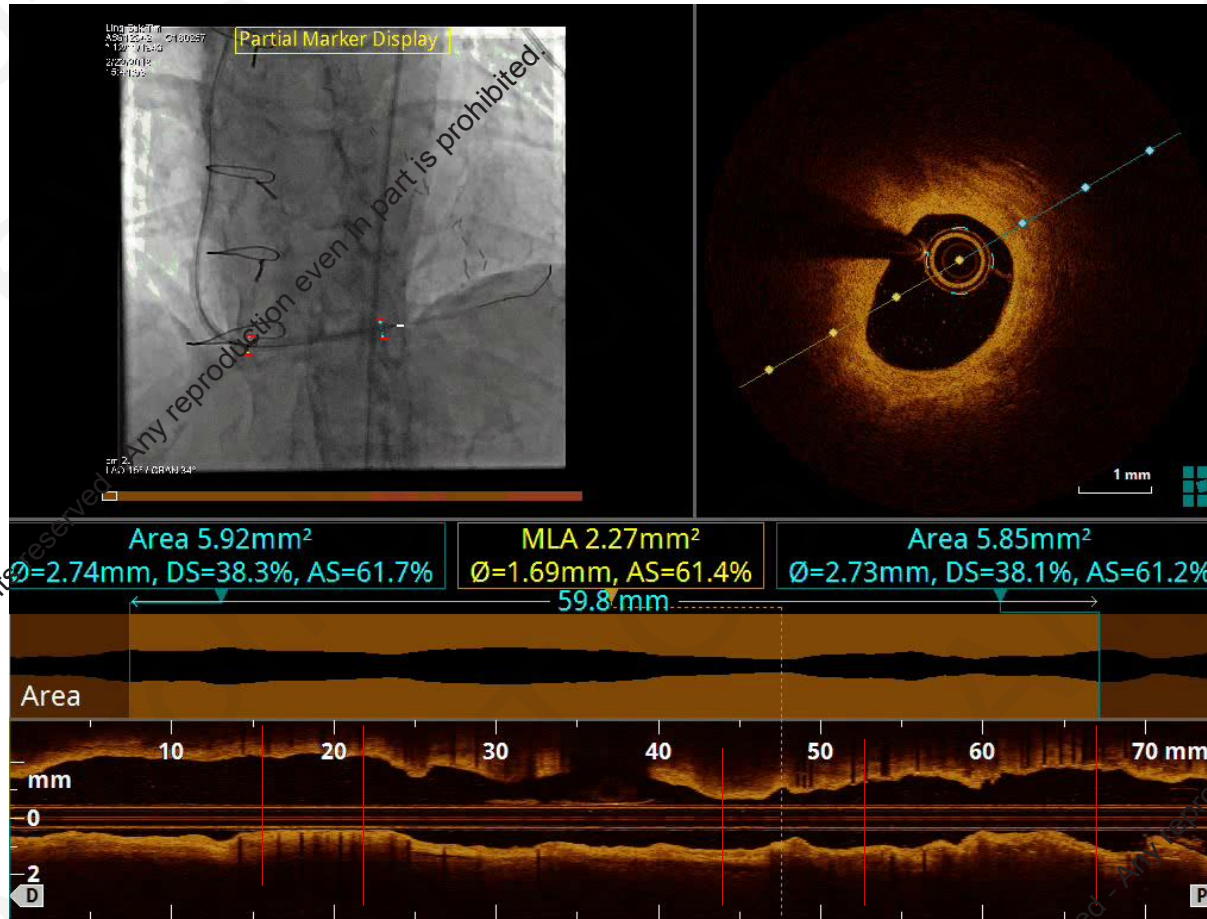
Case 4 inferior STEMI , very late stent thrombosis in SVG-PDA



2018 © AICT Congress 2018. All rights reserved - Any reproduction even in part is prohibited.

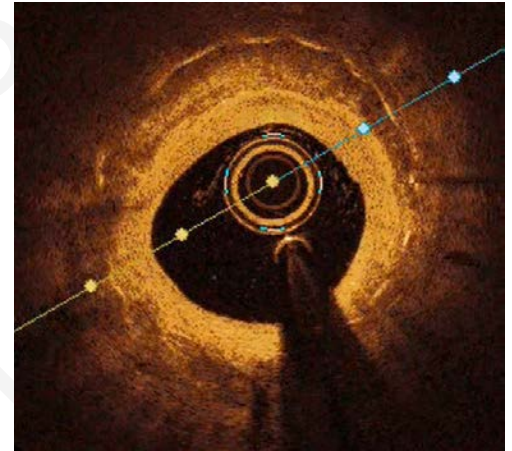
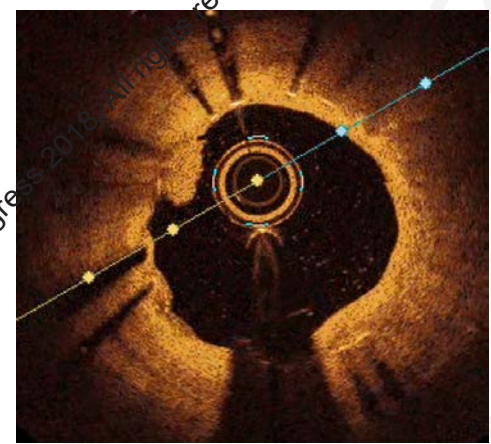
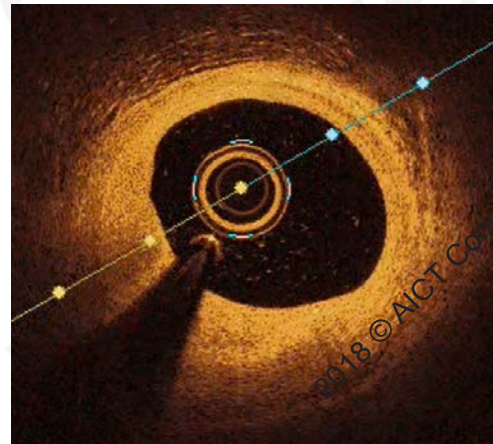
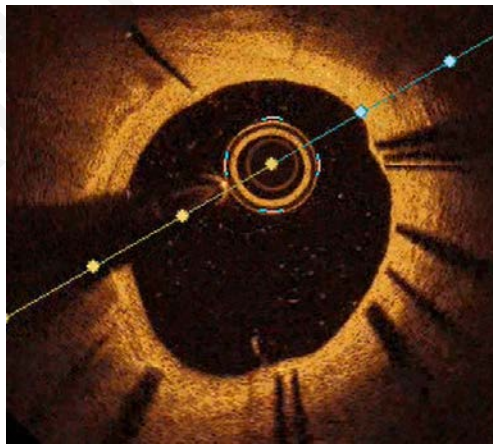
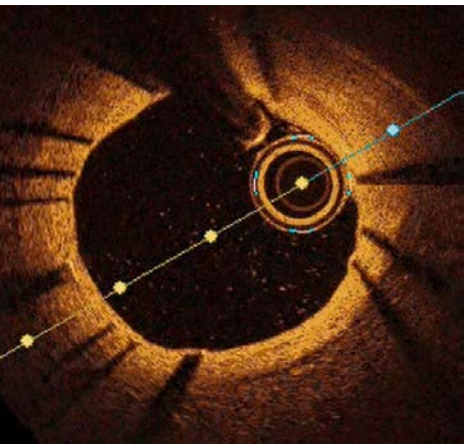
Thrombectomy



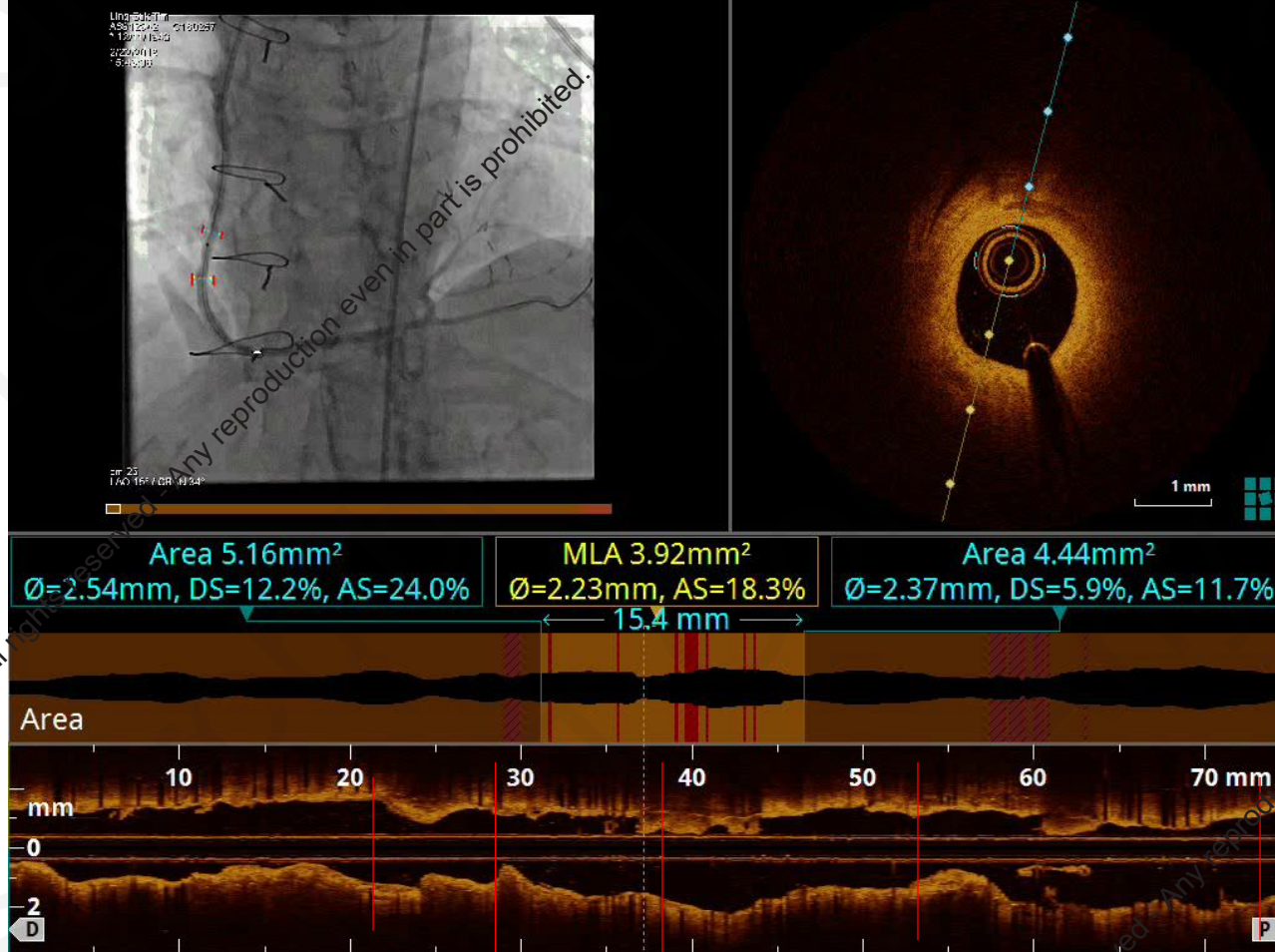


2018 © AICT Congress 2018. All rights reserved. Any reproduction even in part is prohibited.

2018 © AICT Congress 2018. All rights reserved. Any reproduction even in part is prohibited.

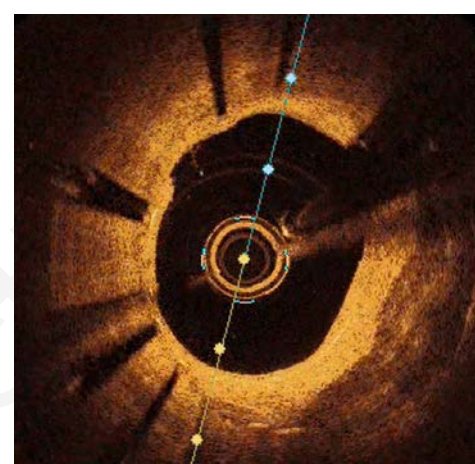
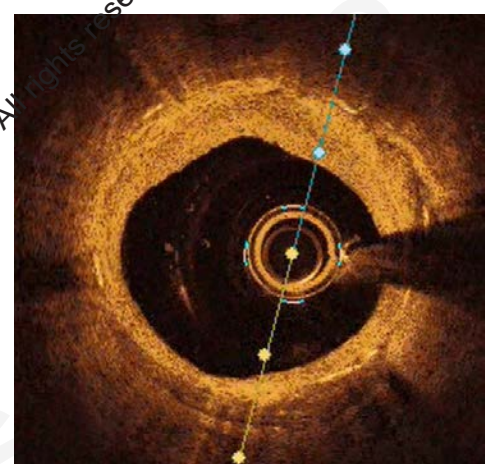

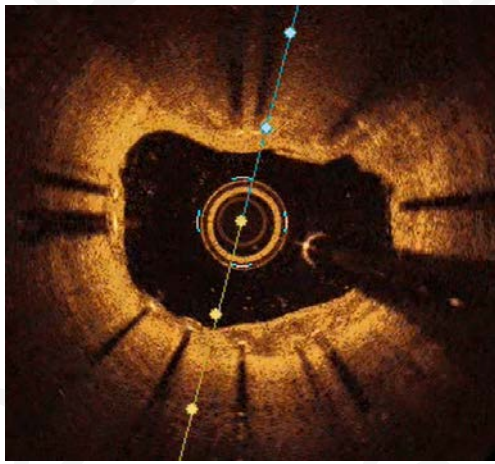
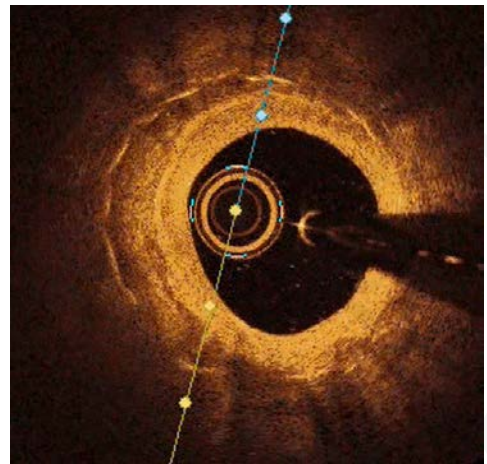


2018 © AICT Congress 2018. All rights reserved. Any reproduction even in part is prohibited.

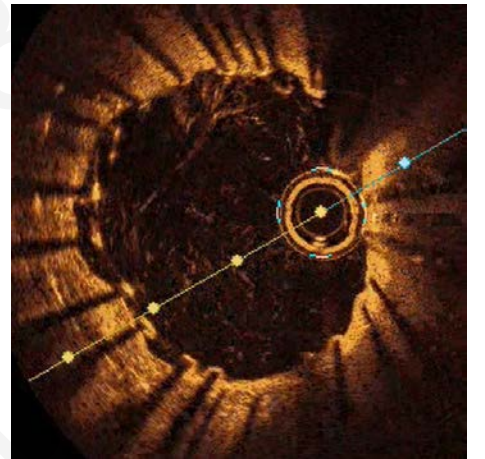
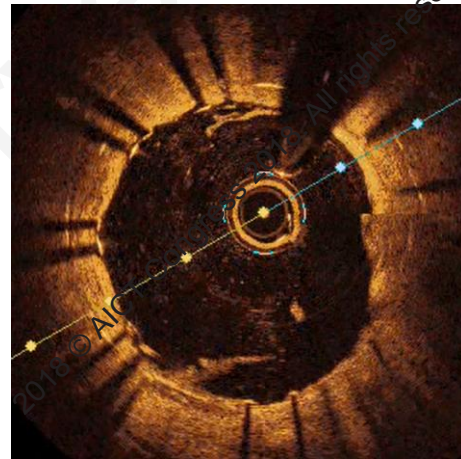
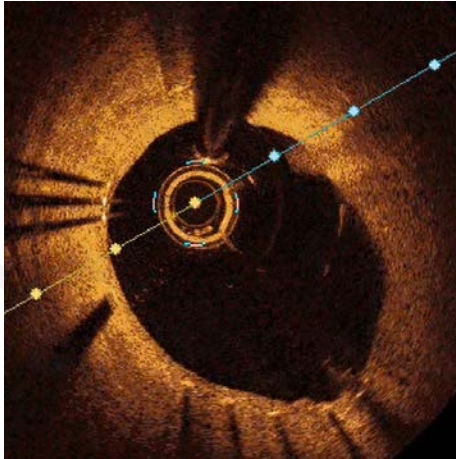
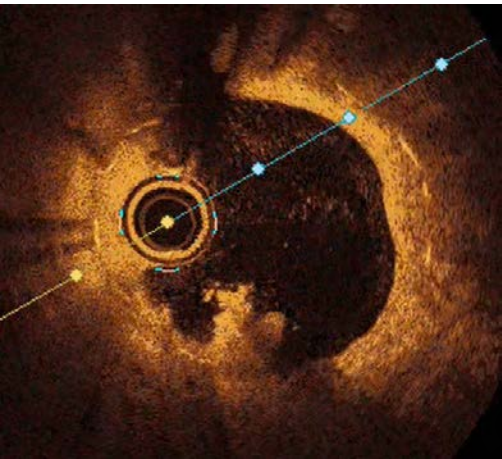
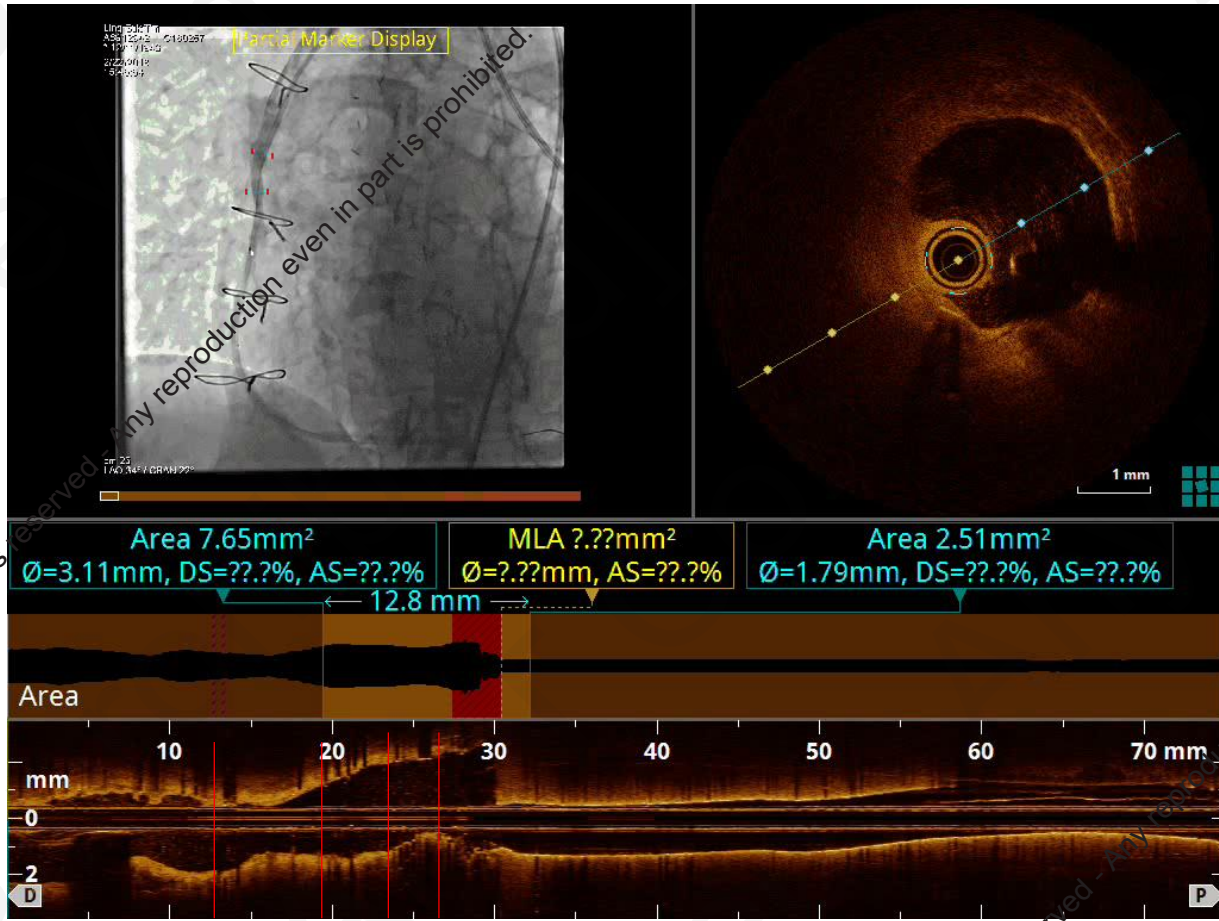


2018 © AICT Congress 2018. All rights reserved. Any reproduction even in part is prohibited.

2018 © AICT Congress 2018. All rights reserved. Any reproduction even in part is prohibited.



2018 © AICT Congress 2018. All rights reserved. Any reproduction even in part is prohibited.



2018 © AICT Congress 2018. All rights reserved. Any reproduction even in part is prohibited.

2018 © AICT Congress 2018. All rights reserved. Any reproduction even in part is prohibited.



- Multiple PCI to SVG-PDA in other hospital
- Last PCI more than 1 yr ago
- Further questioning revealed patient had stopped aspirin in recent 1/52 for dental procedure..

2018 © AICT Congress 2018. All rights reserved - Any reproduction even in part is prohibited.

2018 © AICT Congress 2018. All rights reserved - Any reproduction even in part is prohibited.

Take home message

- Plaque rupture most common cause of ACS
- OCT help to definite best landing zone to avoid placement of stent in lipid rich segment
- Aggressive lesion preparation in calcified lesion is important for better post stenting result
- Understand different mechanism in late stent failure is essential to guide effective treatment strategy

2018 © AICT Congress 2018. All rights reserved - Any reproduction even in part is prohibited.

Mark Your Calendar!

www.hkstent.org

For updates, please visit www.hkstent.org

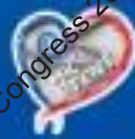HKSTENT - CICF 2019

Cardiovascular Intervention
Complication Forum 2019

8 – 10 MARCH 2019
HONG KONG

*A Complication Case Based Meeting
& the First Dedicated
Complication Forum in Asia*

Organized by:



Hong Kong Society of Transcatheter
Endo-cardiovascular Therapeutics
(HKSTENT)

2018 © AICT Congress 2018. All rights reserved - Any reproduction even in part is prohibited.

14th

AICT

ASIAN INTERVENTIONAL CARDIOVASCULAR THERAPEUTICS
THE OFFICIAL CONGRESS OF APSIC



2018 © AICT Congress 2018. All rights reserved - Any reproduction even in part is prohibited.

2018 © AICT Congress 2018. All rights reserved - Any reproduction even in part is prohibited.

7 - 9th September 2018

Hong Kong

Convention and Exhibition Centre (HKCEC)