

14<sup>th</sup>

**AICT**

ASIAN INTERVENTIONAL CARDIOVASCULAR THERAPEUTICS  
THE OFFICIAL CONGRESS OF APCC

# A Case of trifurcated LM lesions with LCX CTO

CHAO GAO

DEP. OF CARDIOLOGY XIJING HOSPITAL



西京医院  
XIJING HOSPITAL



西京医院  
心血管内科

14<sup>th</sup>

AICT

ASIAN INTERVENTIONAL CARDIOVASCULAR THERAPEUTICS  
THE OFFICIAL CONGRESS OF APSIC

Conflicts of Interest: None

2018 © AICT Congress 2018. All rights reserved - Any reproduction even in part is prohibited.

2018 © AICT Congress 2018. All rights reserved - Any reproduction even in part is prohibited.



西京医院  
心血管内科



西京医院  
XIJING HOSPITAL

# Medical History

---

81yrs , Male

CC : Chest Pain for 7 years

Past History : Gastrointestinal bleeding for 5 years, Hypertension for 2 years , TIA for 7 years

PCI history : **Stent implantation 6 years ago ; Previously failed attempt to open LCX in local hospital 2 months ago**

Lab Tests : Cre 134umol/L ; NT-proBNP 7267pg/ml ; cTnI 0.05ng/ml

Echo: **EF43%**; OMI in anterior wall



西京医院  
心血管内科

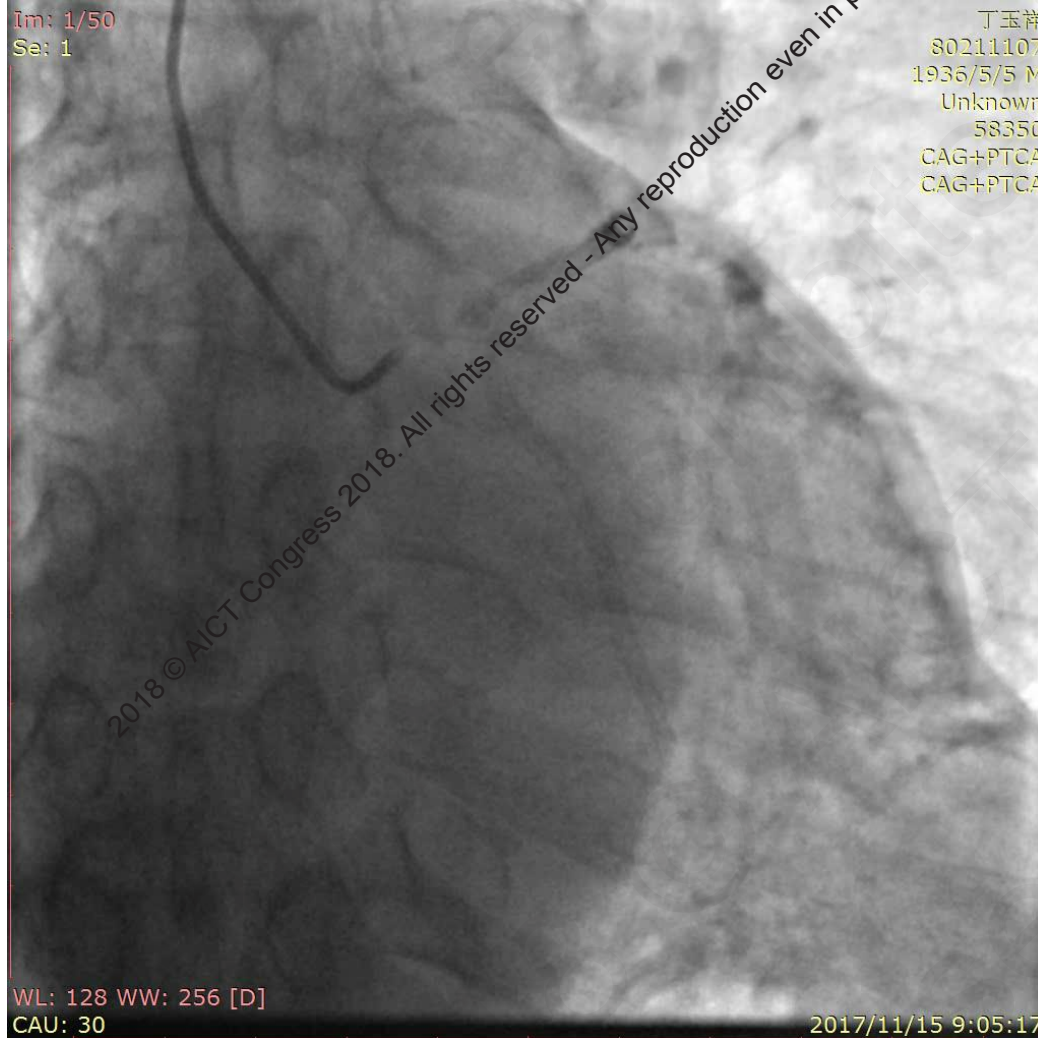


西京医院  
XIJING HOSPITAL

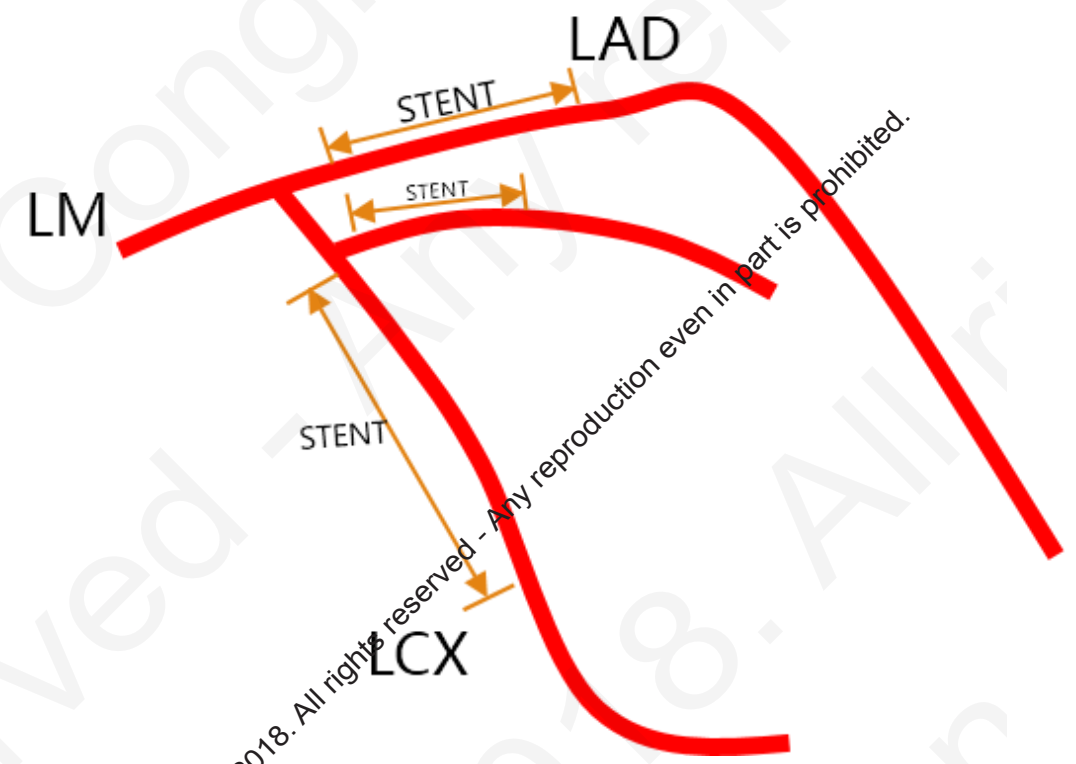
2018 © AICT Congress 2018. All rights reserved - Any reproduction even in part is prohibited.

# CAG

Im: 1/50  
Se: 1



丁玉祥  
80211107  
1936/5/5 M  
Unknown  
58350  
CAG+PTCA  
CAG+PTCA



西京医院  
心血管内科

西京医院  
XIJING HOSPITAL

# CAG

Im: 1/49  
Se: 1

丁玉祥  
80211107  
1936/5/5 M  
Unknown  
58350  
CAG+PTCA  
CAG+PTCA

WL: 128 WW: 256 [D]  
LAO: 36 CAU: 36

2017/11/15 9:05:47

Im: 1/61  
Se: 1

丁玉祥  
80211107  
1936/5/5 M  
Unknown  
58350  
CAG+PTCA  
CAG+PTCA

WL: 128 WW: 256 [D]  
LAO: 1 CRA: 37

2017/11/15 9:07:23

西京医院  
心血管内科



西京医院  
XIJING HOSPITAL

# CAG

Im: 1/95  
Sa: 1

丁玉祥  
80211107  
1936/5/5 M  
Unknown  
58350  
CAG+PTCA  
CAG+PTCA

WL: 128 WW: 256 [D]  
LAO: 32 CRA: 3

2017/11/15 9:11:47

Im: 1/143  
Sa: 1

丁玉祥  
80211107  
1936/5/5 M  
Unknown  
58350  
CAG+PTCA  
CAG+PTCA

WL: 128 WW: 256 [D]  
LAO: 2 CRA: 24

2017/11/15 9:13:51

西京医院  
心血管内科

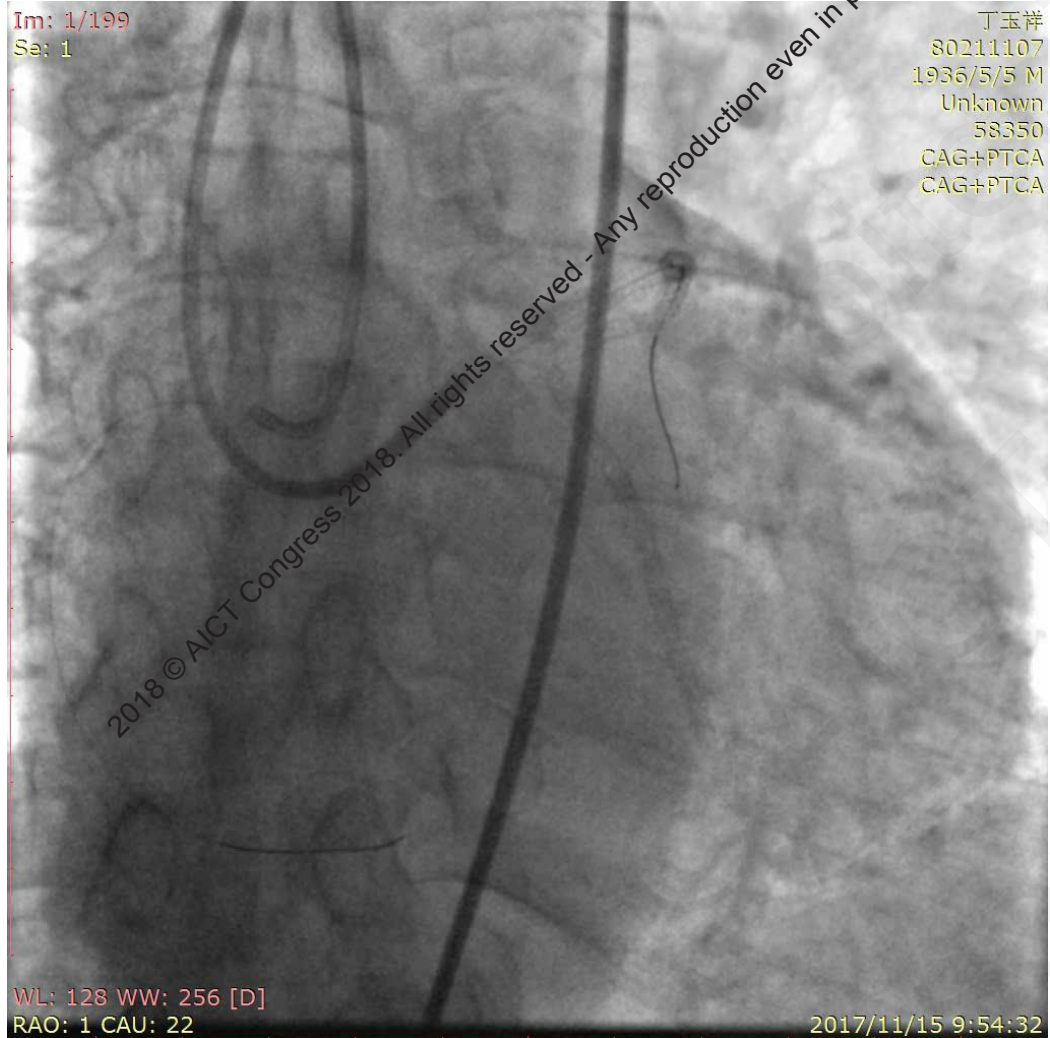


西京医院  
XIJING HOSPITAL

# TRA 6F JR4 TFA 7F EBU3.5

Im: 1/199  
Se: 1

丁玉祥  
80211107  
1936/5/5 M  
Unknown  
58350  
CAG+PTCA  
CAG+PTCA

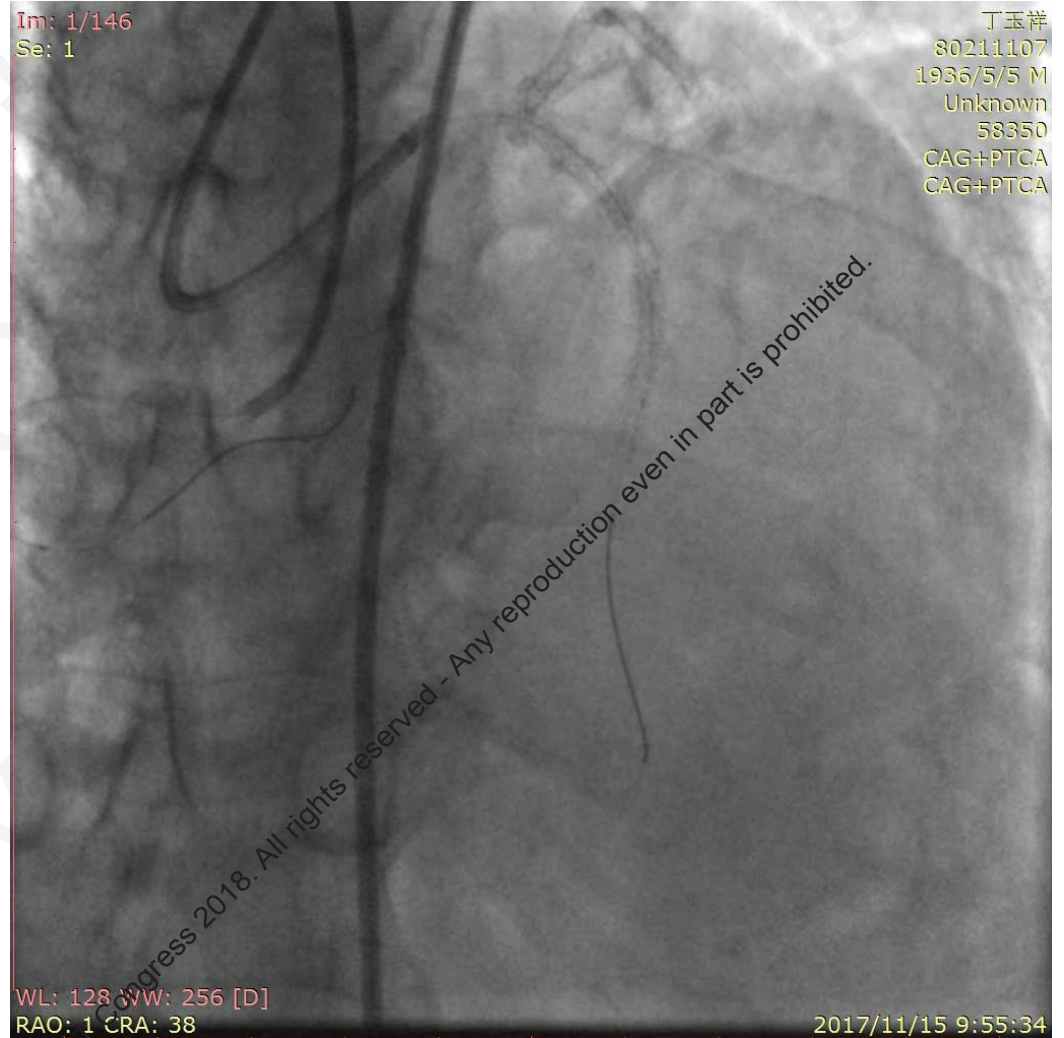


WL: 128 WW: 256 [D]  
RAO: 1 CAU: 22

2017/11/15 9:54:32

Im: 1/146  
Se: 1

丁玉祥  
80211107  
1936/5/5 M  
Unknown  
58350  
CAG+PTCA  
CAG+PTCA



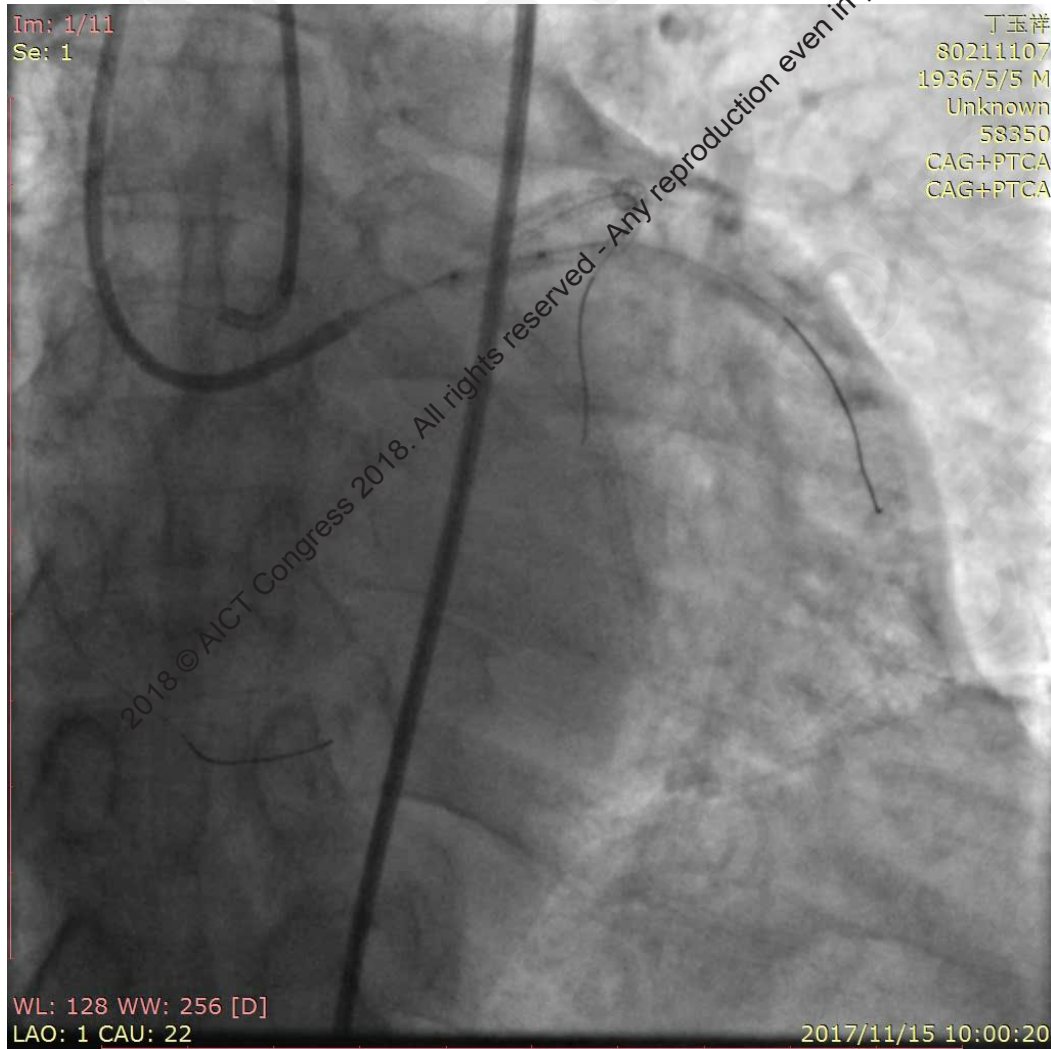
WL: 128 WW: 256 [D]  
RAO: 1 CRA: 38

2017/11/15 9:55:34

西京医院  
心血管内科




# Runthrough 1.5mm balloon---CB 2.75mm\*10mm



**BAPE**

(Balloon assisted plaque entry)



西京医院  
心血管内科

西京医院  
XIJING HOSPITAL



# KDL+ Conquest Pro

Im: 1/75  
Se: 1

丁玉祥  
80211107  
1936/5/5 M  
Unknown  
58350  
CAG+PTCA  
CAG+PTCA

WL: 128 WW: 256 [D]  
LAO: 1 CAU: 22

2017/11/15 10:01:42

Im: 1/29  
Se: 1

丁玉祥  
80211107  
1936/5/5 M  
Unknown  
58350  
CAG+PTCA  
CAG+PTCA

WL: 128 WW: 256 [D]  
RAO: 1 CAU: 29

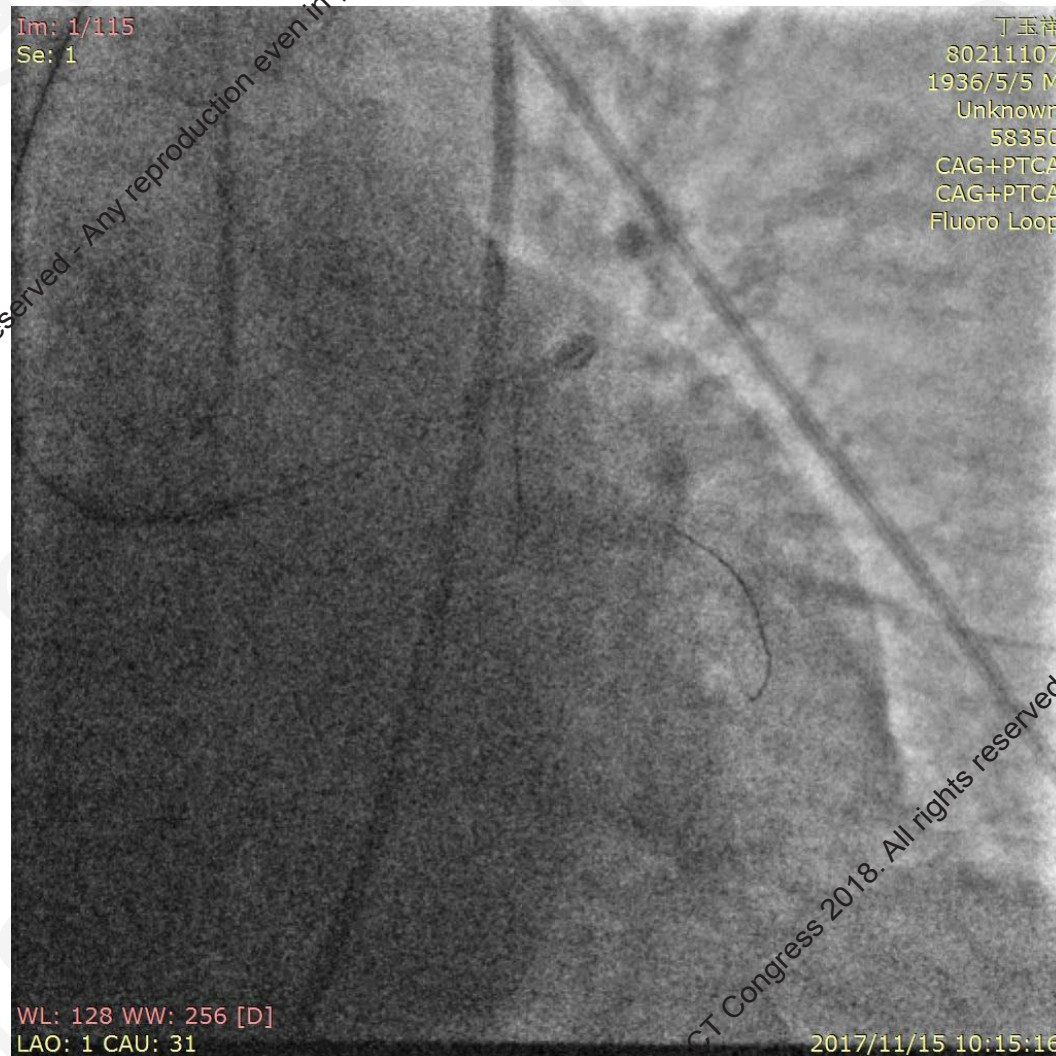2017/11/15 10:14:24

西京医院  
心血管内科



西京医院  
XIJING HOSPITAL

# KDL+ Conquest Pro

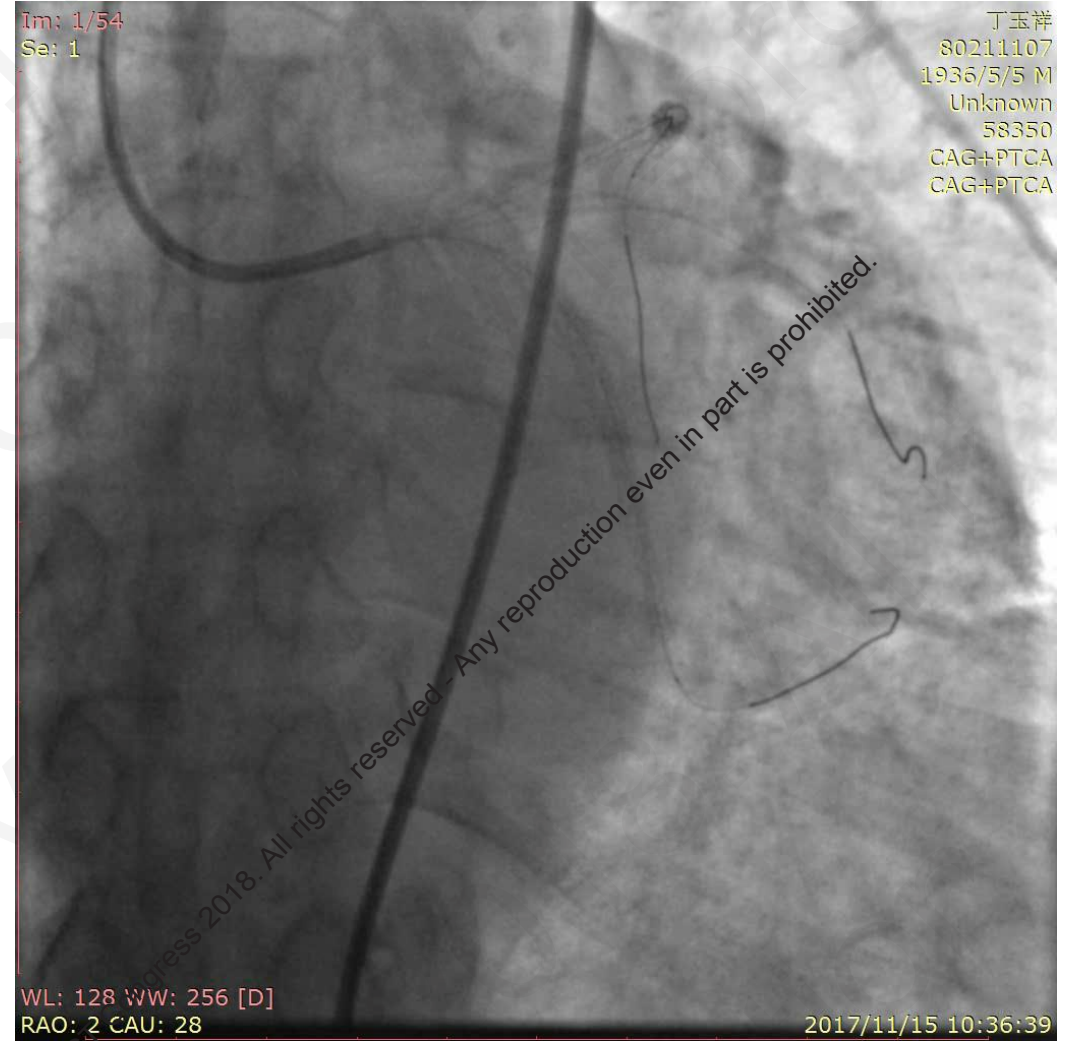
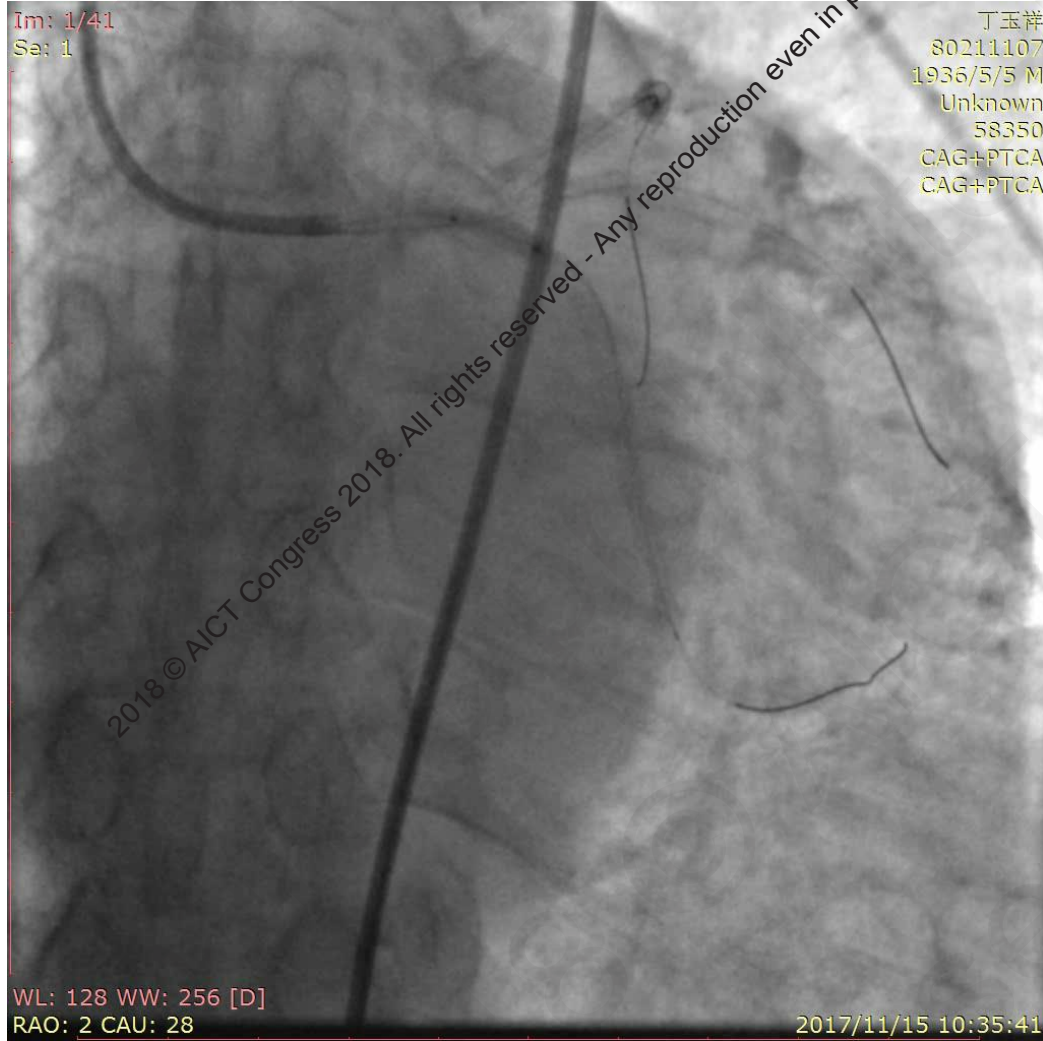


西京医院  
心血管内科



西京医院  
XIJING HOSPITAL

# 1.5mm\*20mm balloon—CB 2.75mm\*10mm



# Stenting Strategy ?

---

- Duo-stent for LCX-OM1? And another T stenting for LM-LAD?
- Duo-stent for LCX-LAD? OM1 with DCB?
- All three vessels with DCB?

2018 © AICT Congress 2018. All rights reserved - Any reproduction even in part is prohibited.

2018 © AICT Congress 2018. All rights reserved - Any reproduction even in part is prohibited.

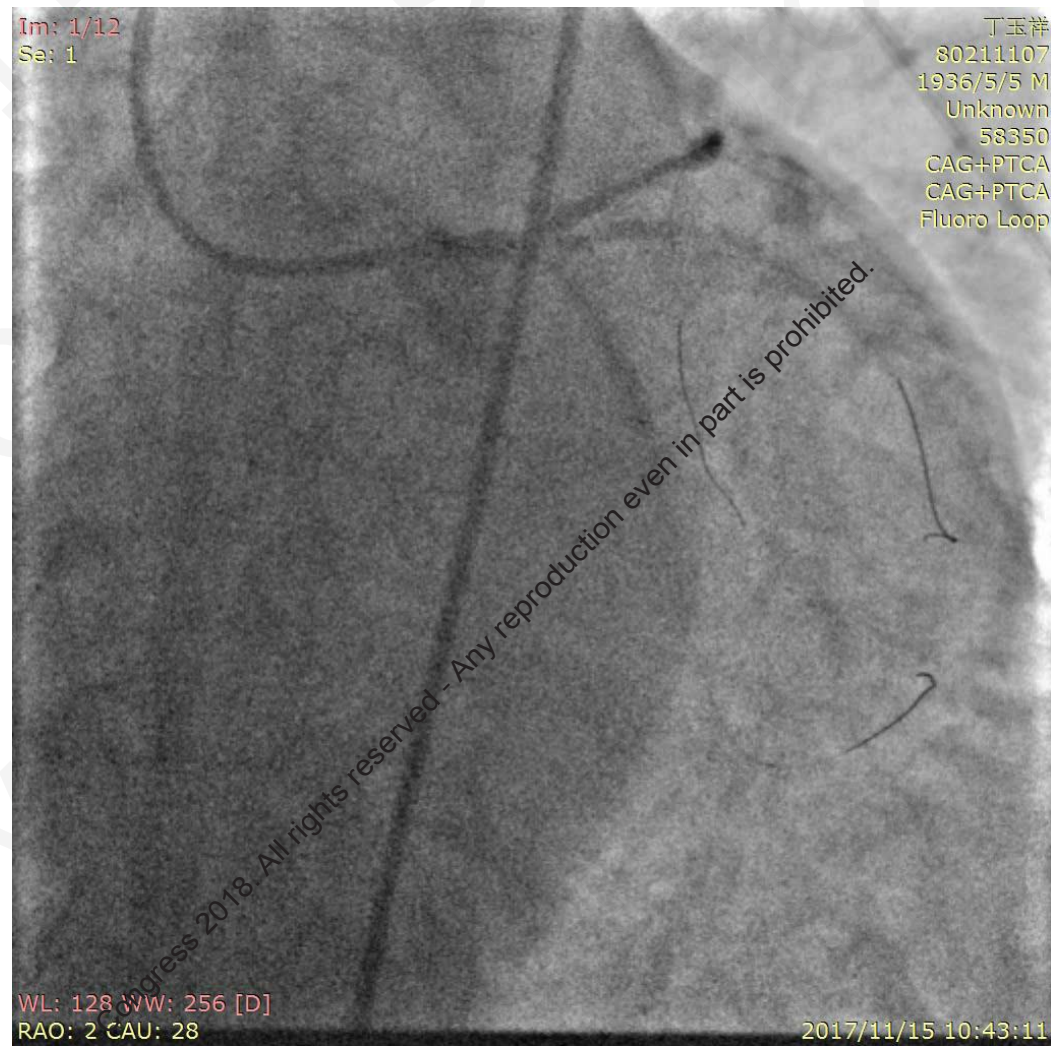
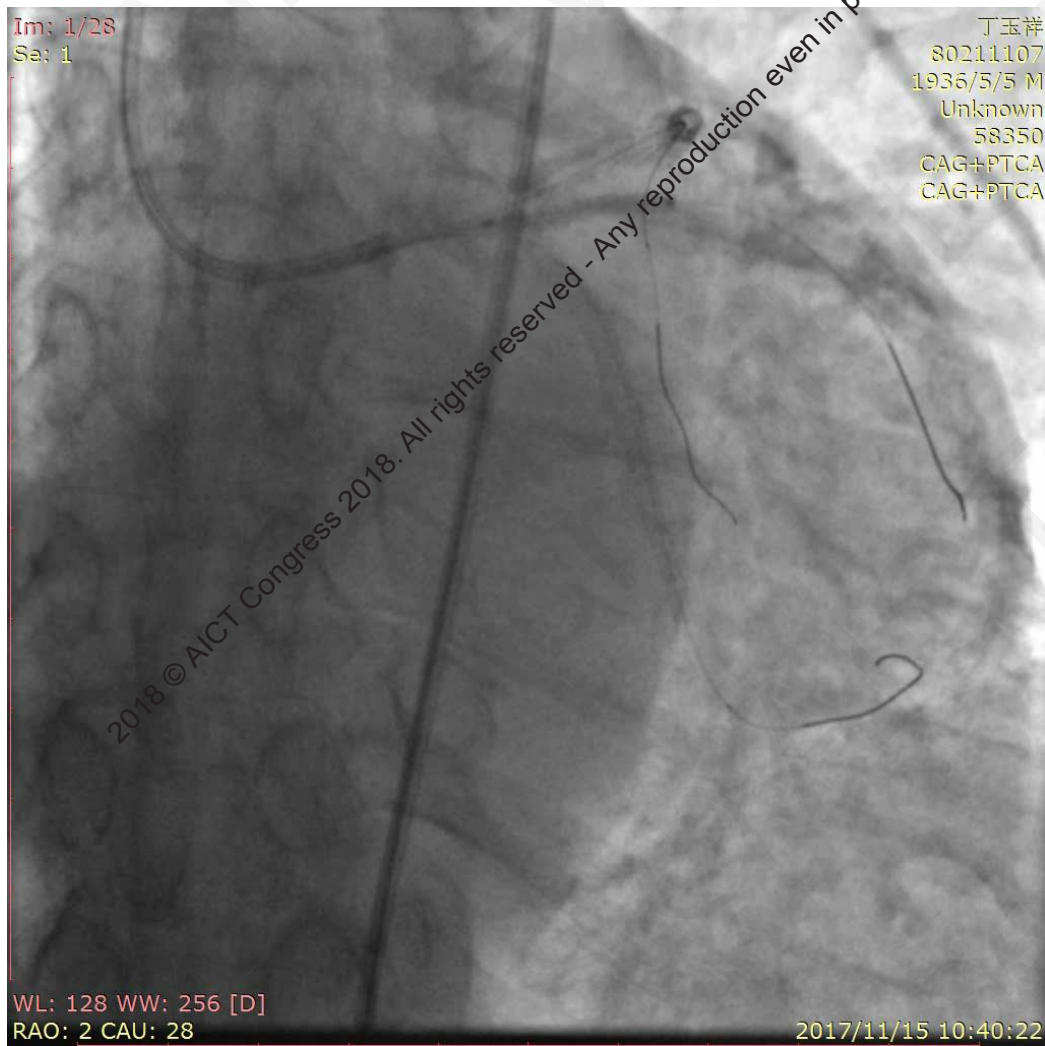


西京医院  
心血管内科



西京医院  
XIJING HOSPITAL

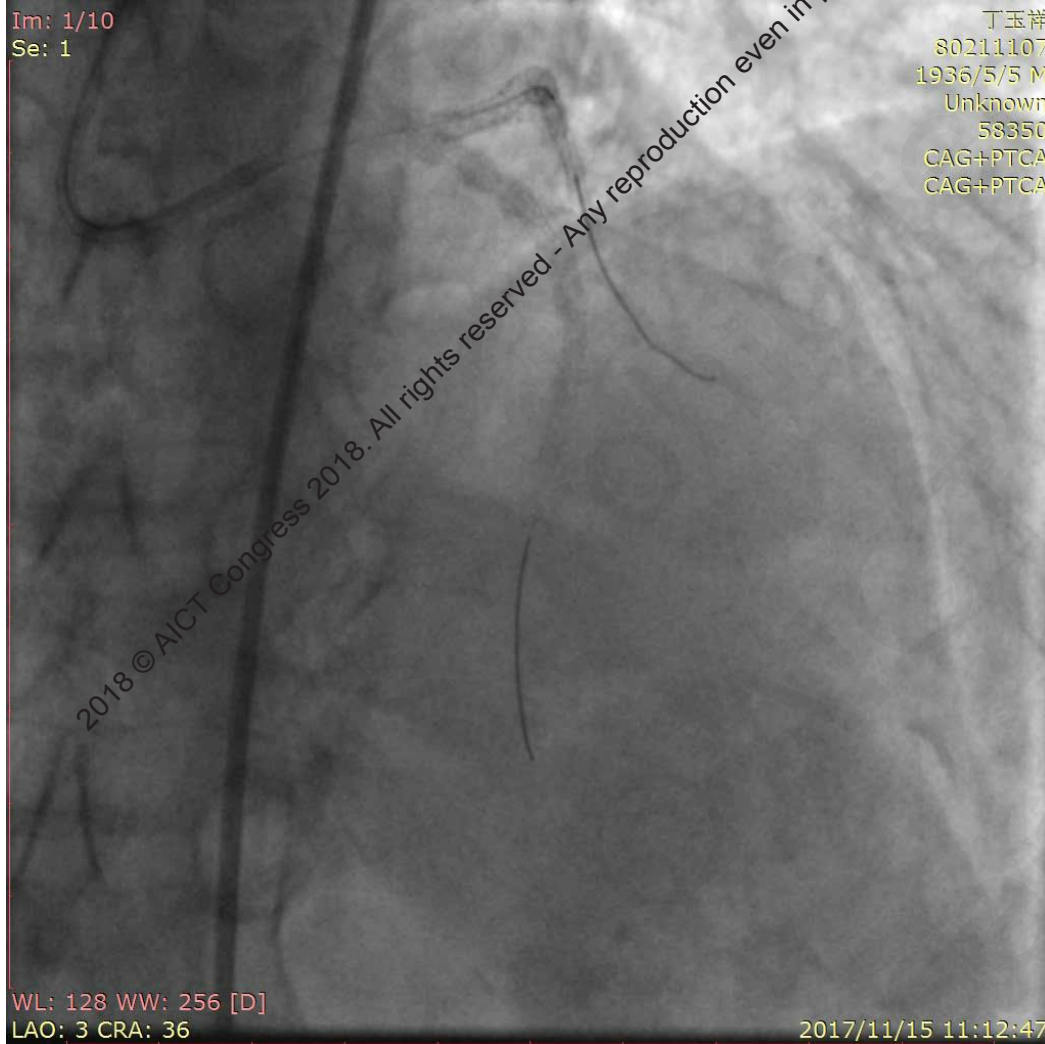
# 2.5mm\*30mm & 3.0mm\*30mm DCB



西安医院  
心血管内科

西安医院  
XI'AN JIAOTONG UNIVERSITY HOSPITAL

# LAD ? How should we treat it?



LAD FFR 0.72

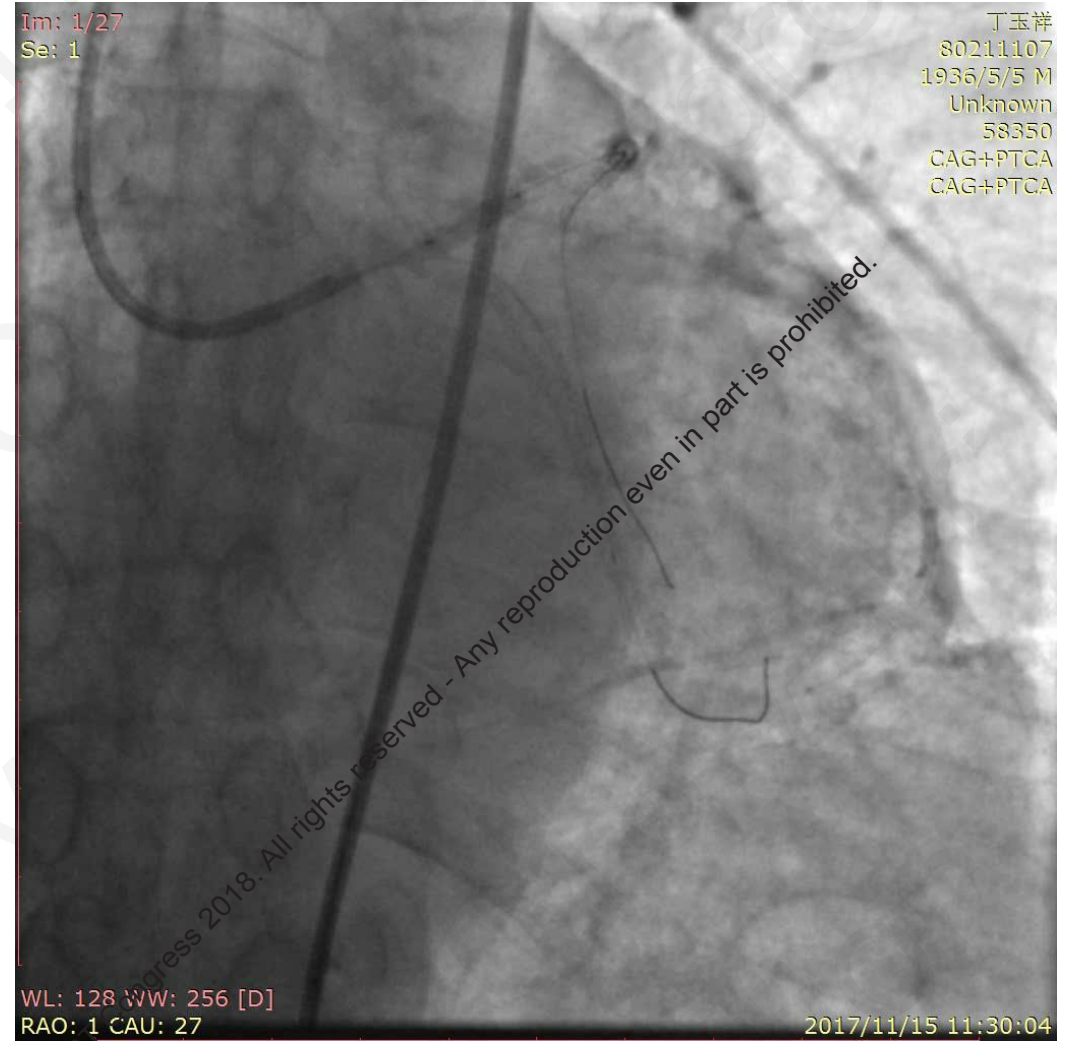
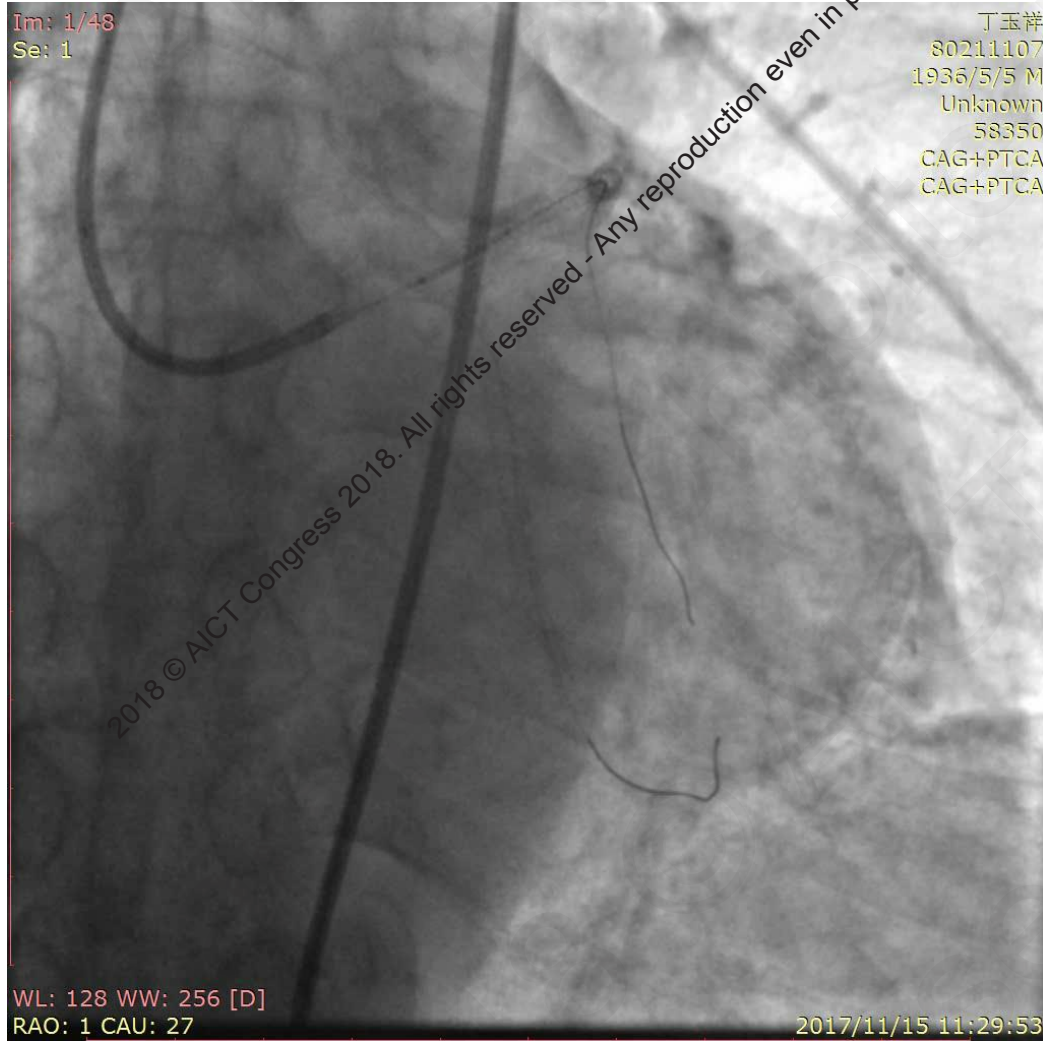
Pullback: Major stenosis is located in the proximal LAD



西京医院  
心血管内科

西京医院  
XIJING HOSPITAL

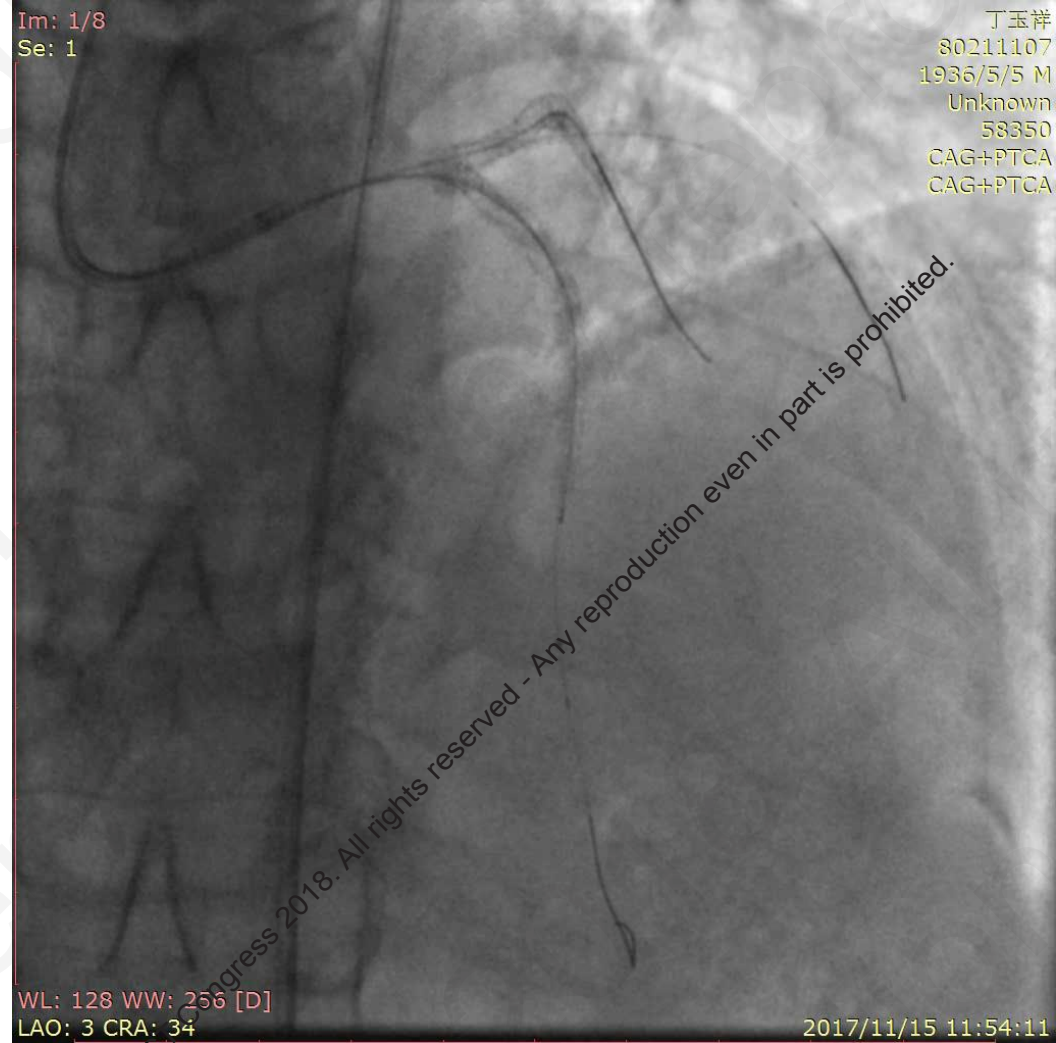
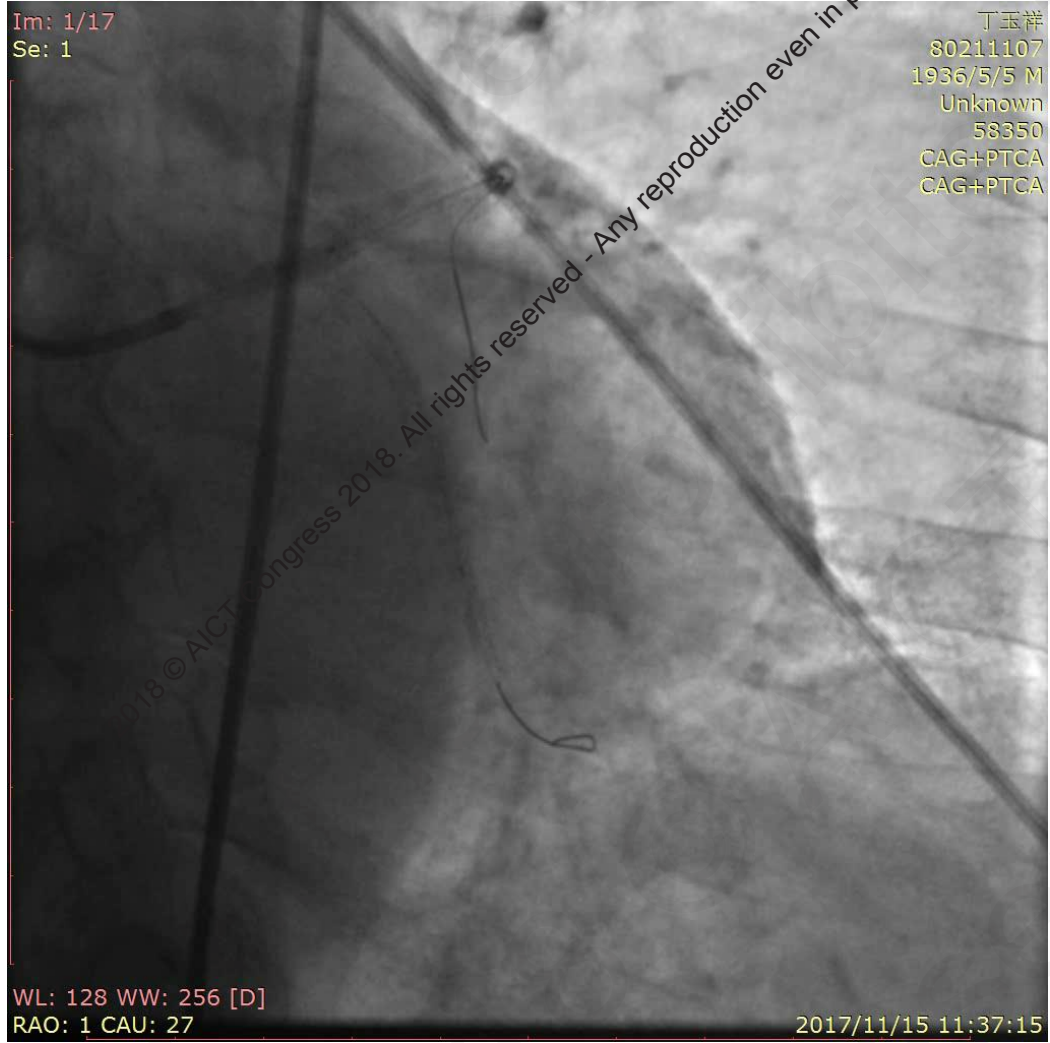
# 3.0mm\*12mm STENT @ 22ATM



西京医院  
心血管内科

西京医院  
XIJING HOSPITAL

# 3.5mm\*8mm NCB @ 24 ATM

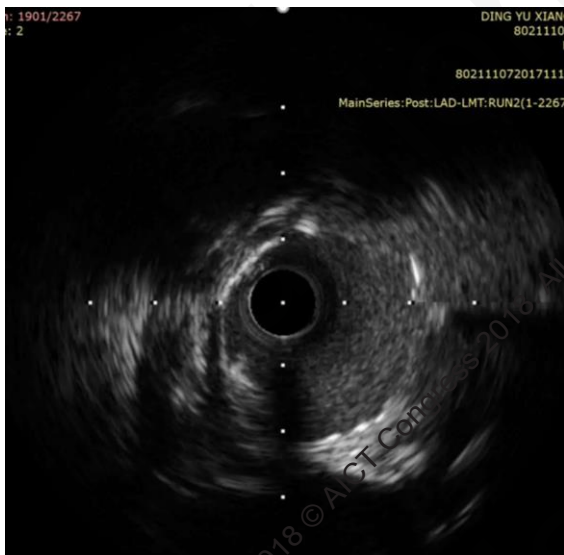


西京医院  
心血管内科

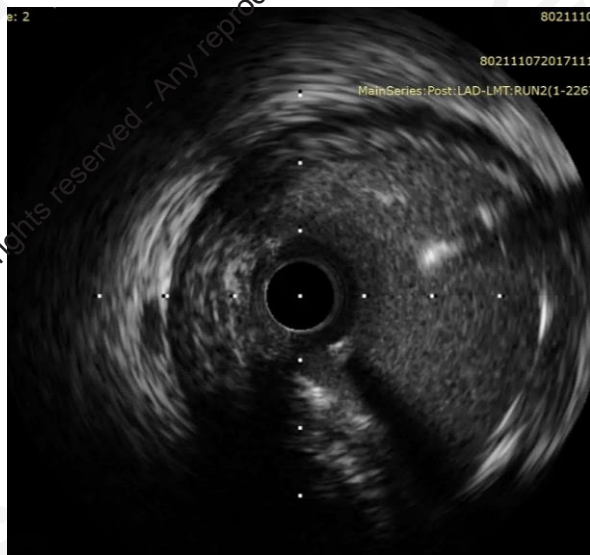
西京医院  
XI JING HOSPITAL



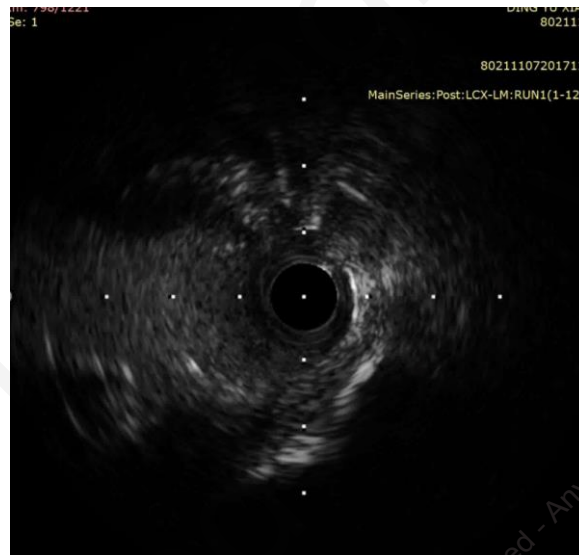
# IVUS: LAD-LM & LCX



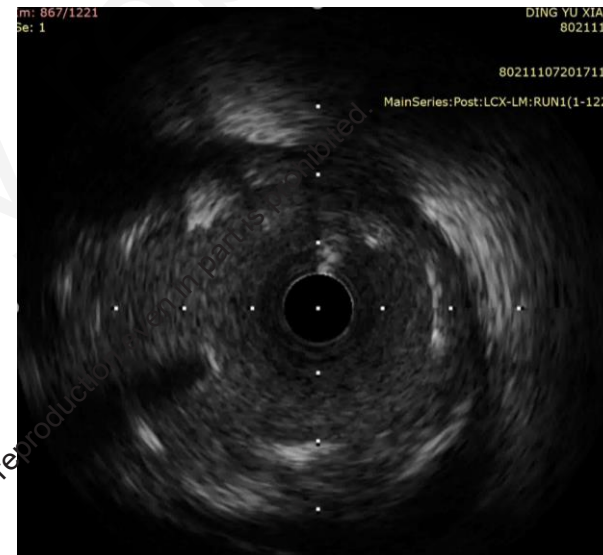
Ostium of LAD



Small Protrusion of stent in LM



POC of LCX/OM1



Ostium of LCX



西京医院  
心血管内科



西京医院  
XIJING HOSPITAL

# Final CAG

Im: 1/50  
Se: 1

丁玉祥  
80211107  
1936/5/5 M  
Unknown  
58350  
CAG+PTCA  
CAG+PTCA

WL: 128 WW: 256 [D]  
RAO: 1 CAU: 27

2017/11/15 11:37:48

Im: 1/57  
Se: 1

丁玉祥  
80211107  
1936/5/5 M  
Unknown  
58350  
CAG+PTCA  
CAG+PTCA

WL: 128 WW: 256 [D]  
LAO: 27 CAU: 30

2017/11/15 11:48:11



西安医院  
心血管内科



西安医院  
XI'AN HOSPITAL

# Follow Up (6 Months)

---

- Significant relieved chest pain and short of breath
- Echo EF 49 % (Previously 43%)
- Cre 103umol/L

2018 © AICT Congress 2018. All rights reserved - Any reproduction even in part is prohibited.

2018 © AICT Congress 2018. All rights reserved - Any reproduction even in part is prohibited.



西京医院  
心血管内科



西京医院  
XIJING HOSPITAL

# Summary

---

- **BAPE technique is derived from BASE (balloon assisted sub-intima entry), which is often useful to facilitate to enter blunted and angled cap.**
- **KDL can help to enter a angled branch without making a large second curve in a wire.**
- **Spending money on FFR is always worthy; Checking IVUS after treating a LM lesion can always make you sleep tight at night.**



2018 © AICT Congress 2018. All rights reserved - Any reproduction even in part is prohibited.

2018 © AICT Congress 2018. All rights reserved - Any reproduction even in part is prohibited.

**谢 谢 !**  
**Thank You!**

2018 © AICT Congress 2018. All rights reserved - Any reproduction even in part is prohibited.



西京医院  
心血管内科



西京医院  
XIJING HOSPITAL

14<sup>th</sup>

# AICT

ASIAN INTERVENTIONAL CARDIOVASCULAR THERAPEUTICS  
THE OFFICIAL CONGRESS OF APSIC



2018 © AICT Congress 2018. All rights reserved - Any reproduction even in part is prohibited.

2018 © AICT Congress 2018. All rights reserved - Any reproduction even in part is prohibited.

**7 - 9th September 2018**

**Hong Kong**

Convention and Exhibition Centre (HKCEC)