

14<sup>th</sup>

**AICT**

ASIAN INTERVENTIONAL CARDIOVASCULAR THERAPEUTICS  
THE OFFICIAL CONGRESS OF APSIC

# An Unexpected Complex PCI Case

Hu Xun M.D. PHD. FAPIC

Department of Cardiology

1<sup>st</sup> Affiliated Hospital, Sun Yat-sen University



# Conflicts of Interest

Speaker's name : Xun Hu, 1st Affiliated Hospital, Sun-yat Sen University

- I do not have any potential conflict of interest

2018 © AICT Congress 2018. All rights reserved - Any reproduction even in part is prohibited.

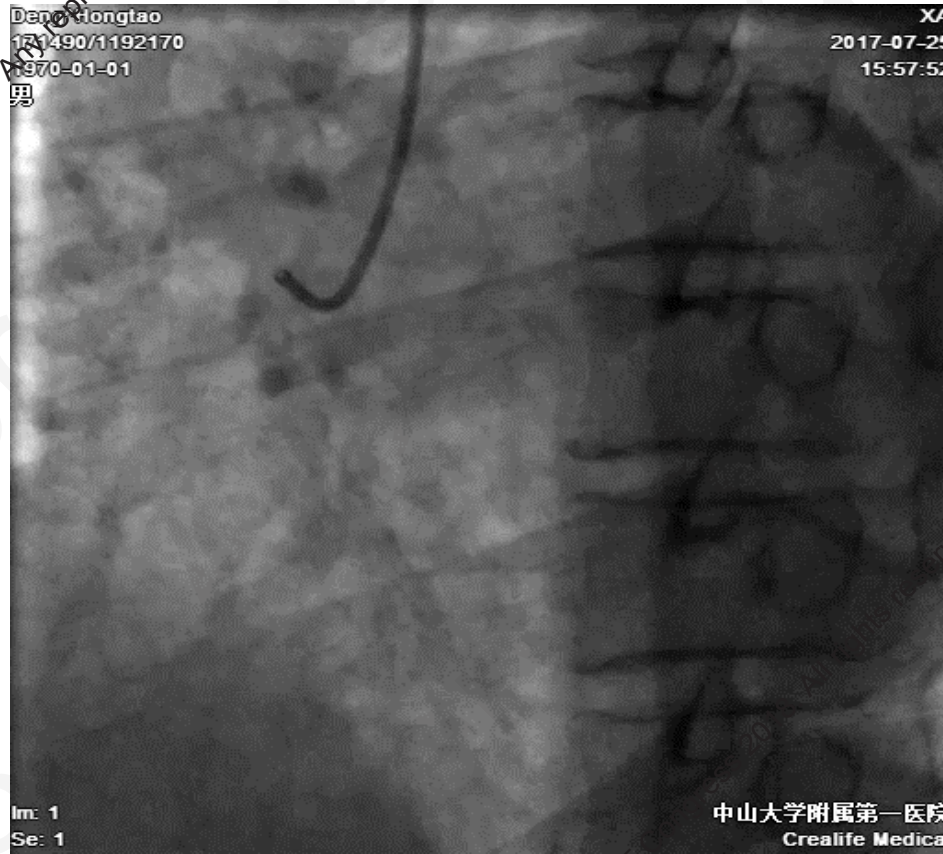
2018 © AICT Congress 2018. All rights reserved - Any reproduction even in part is prohibited.



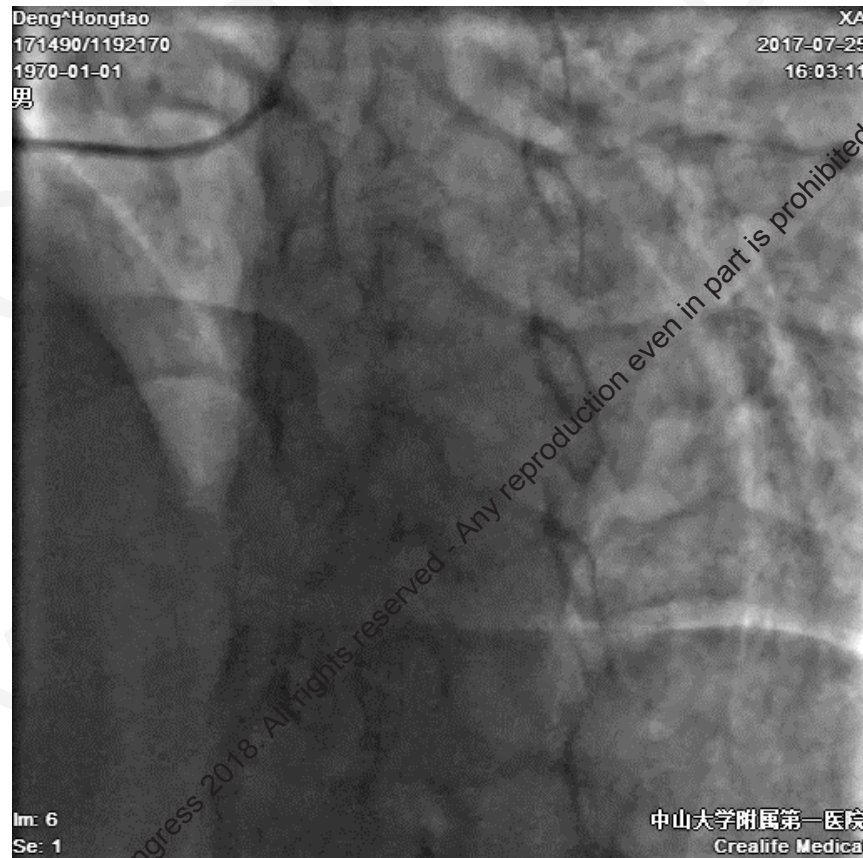
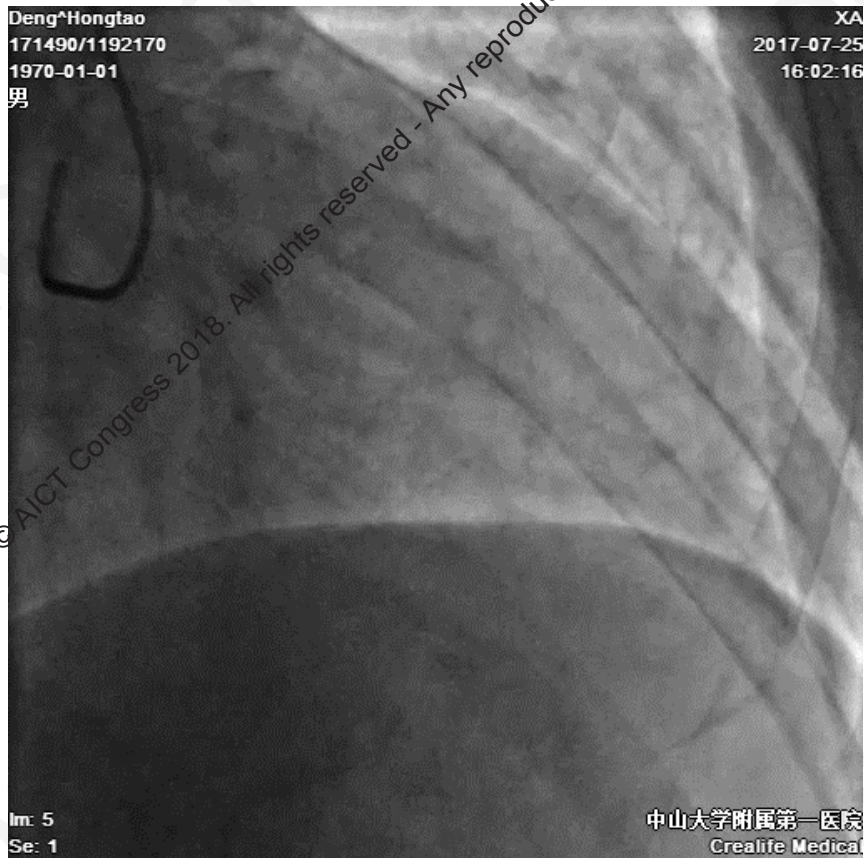
# Brief History

- Male, 47yo
- Smoking
- Recurrent effort chest pain for 1yr, standard treatments, but symptom exacerbated in 1mo
- Rest ECG: negative
- TnT: negative
- Diagnosis: UAP

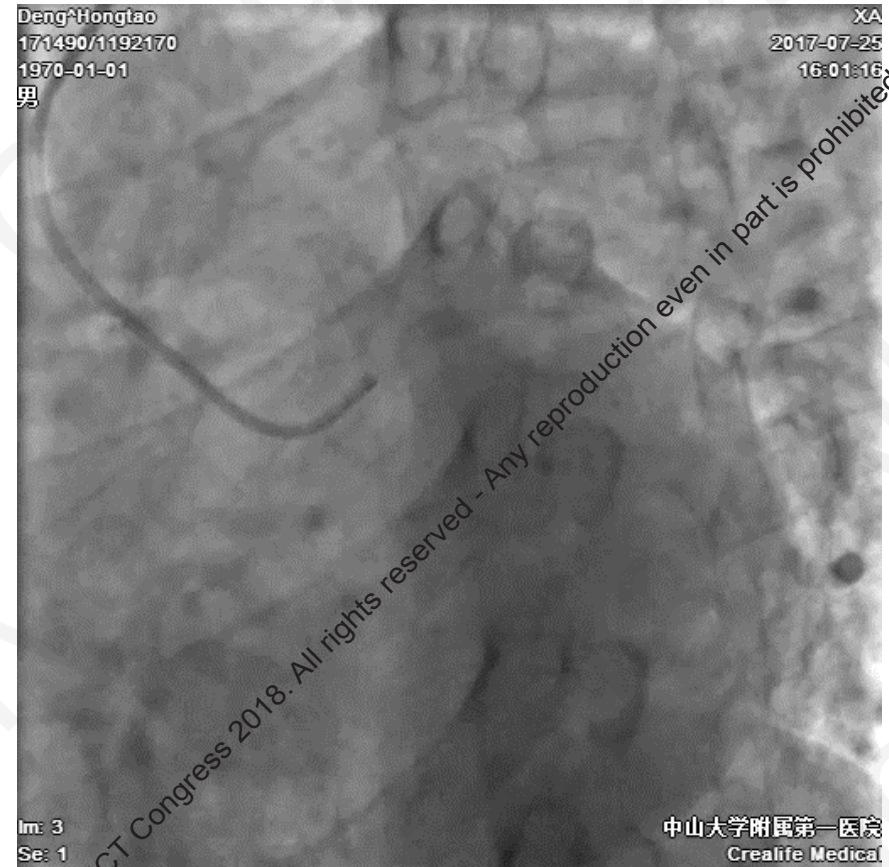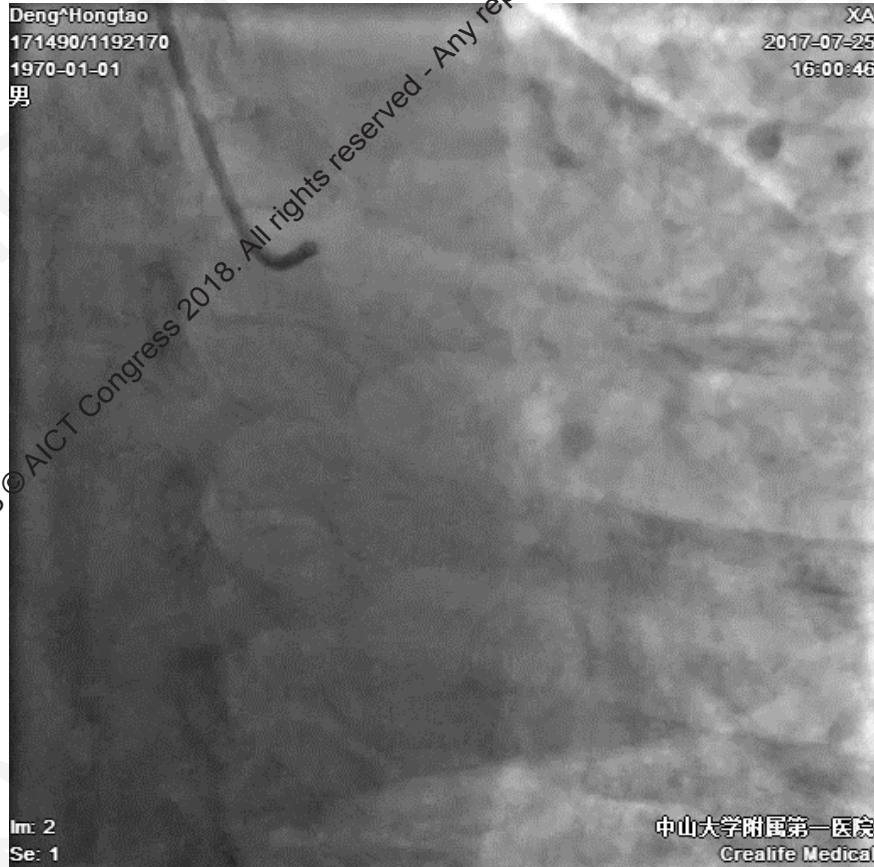## Angio



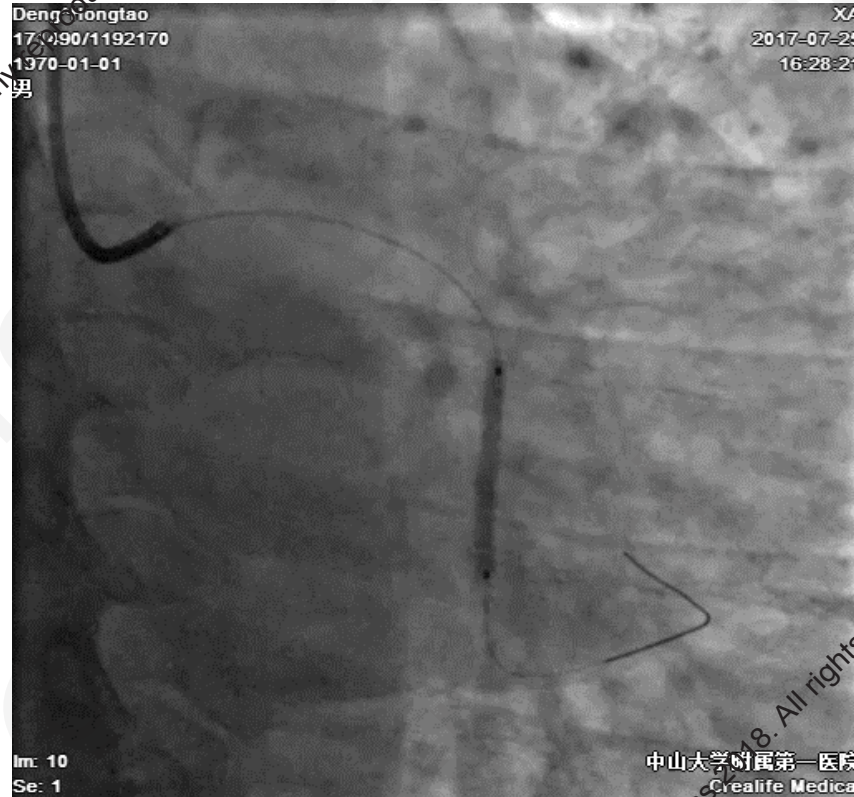
## Angio



## Angio



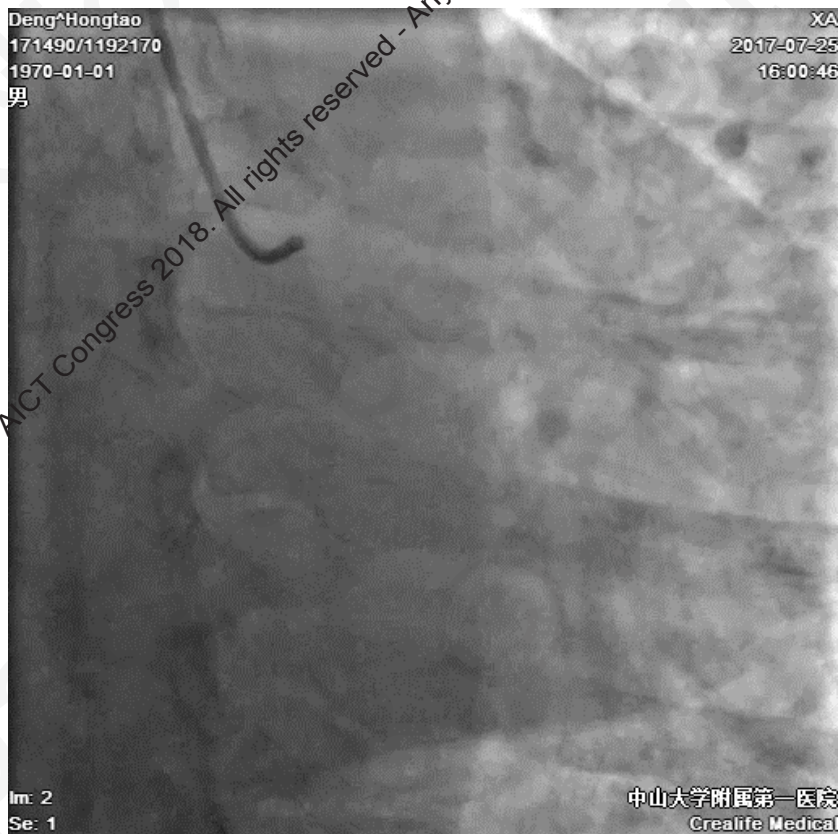## PCI DES 2.25\*24



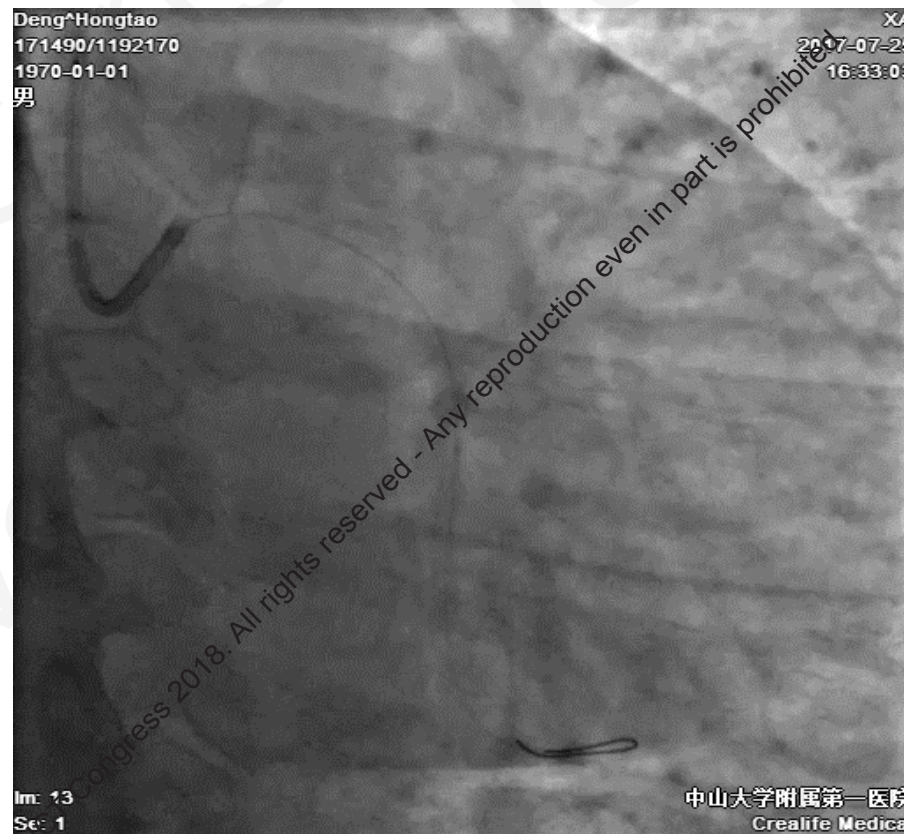First mistake : The operator pulled back the stent balloon a little and inflated again with 16atm, then story came...

## Something happen

Before PCI

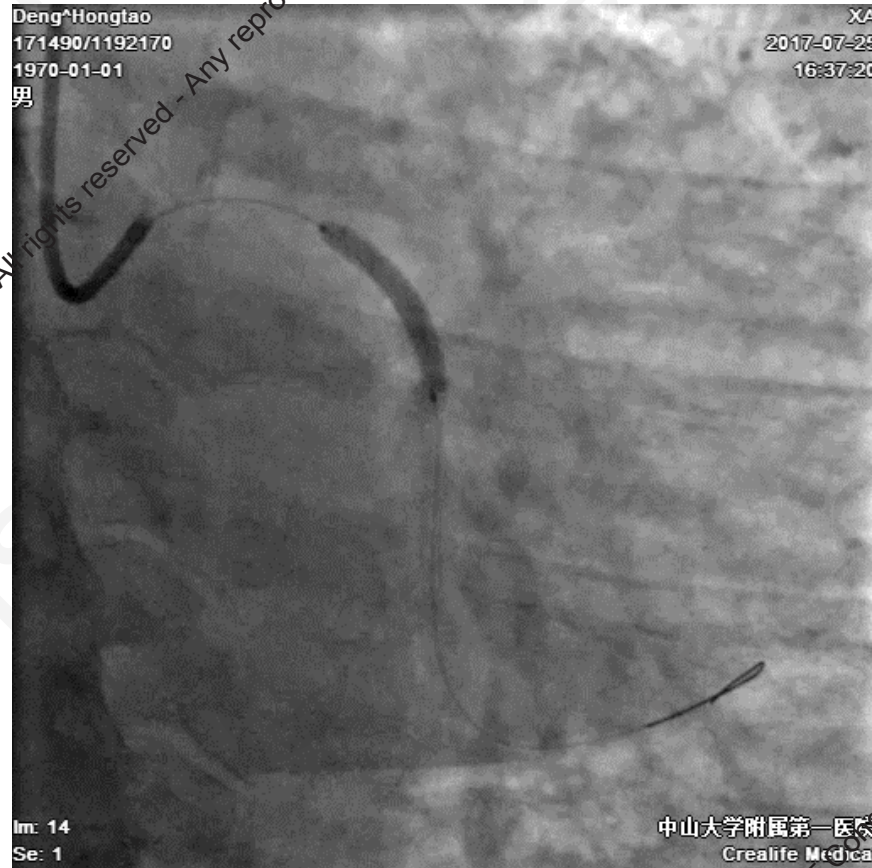


After PCI





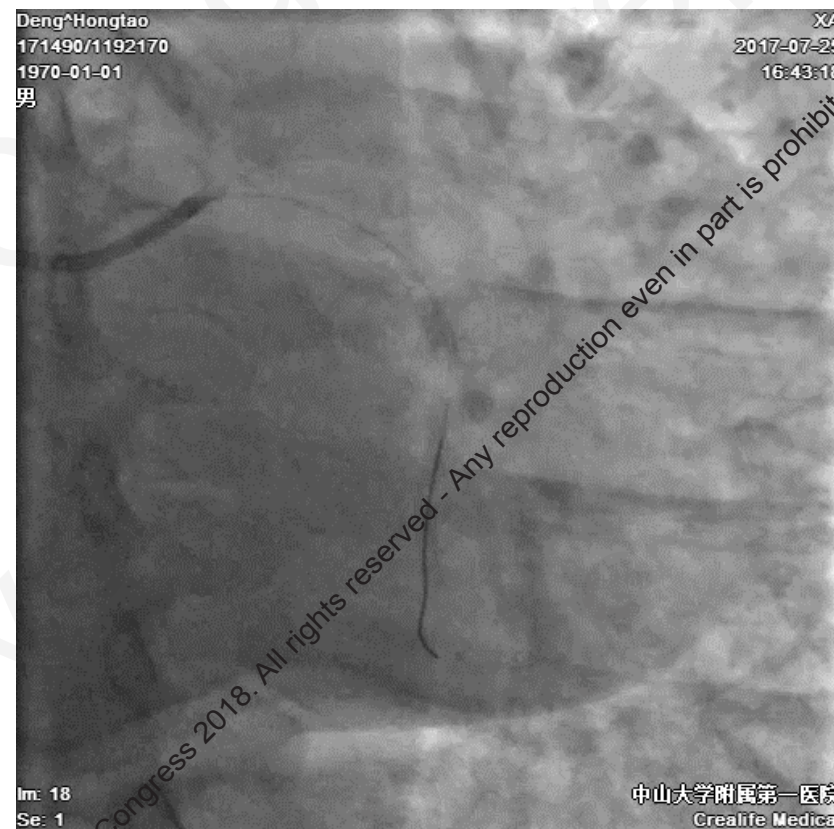
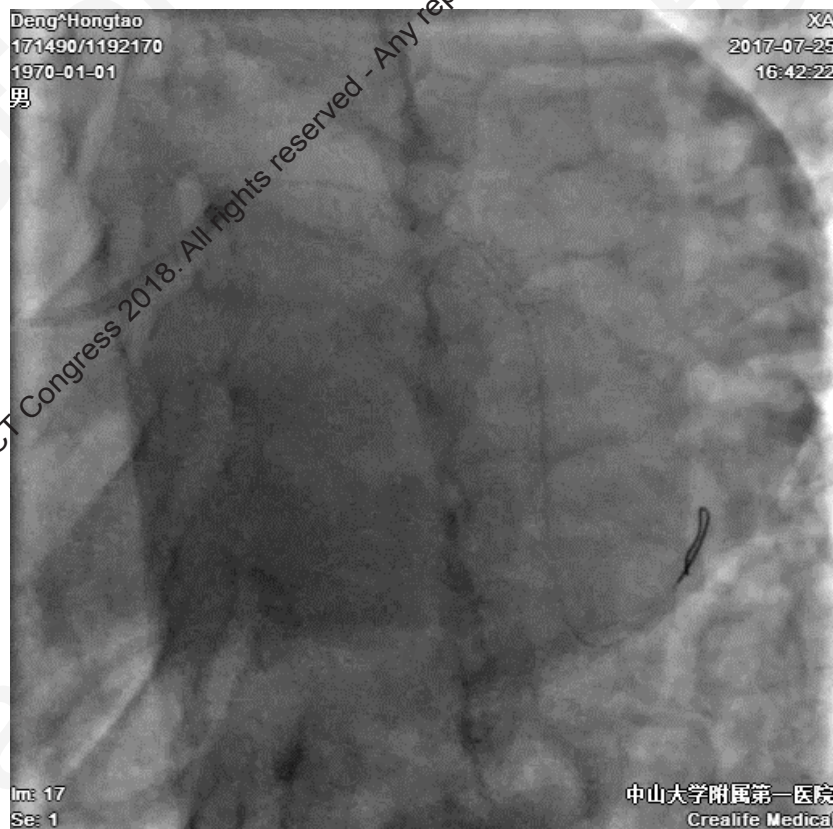
# Another stent to cover the hematoma DES 3.0\*23



Second mistake: stenting  
without intracavity  
imaging instruction

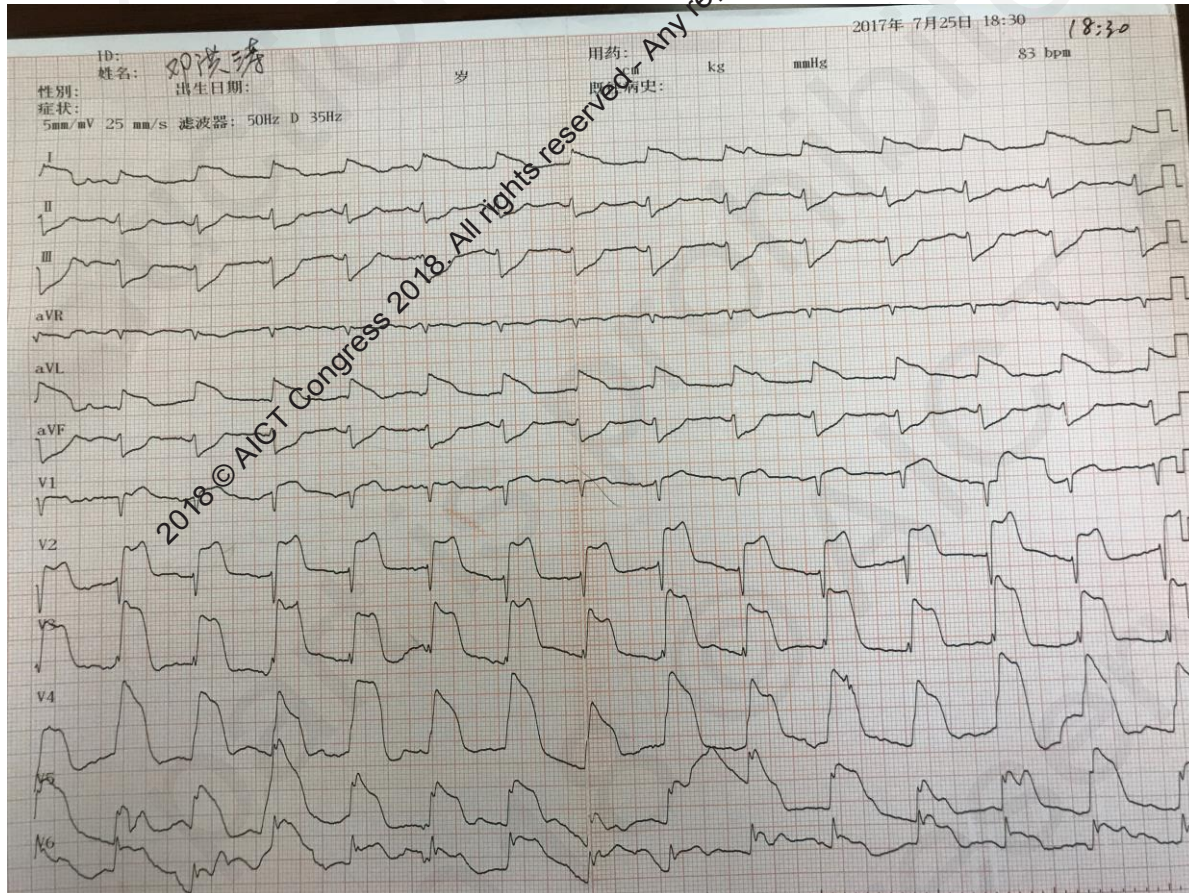
## Final

Third mistake: neglected the residual hematoma



## 30mins after PCI

Severe chest pain attack



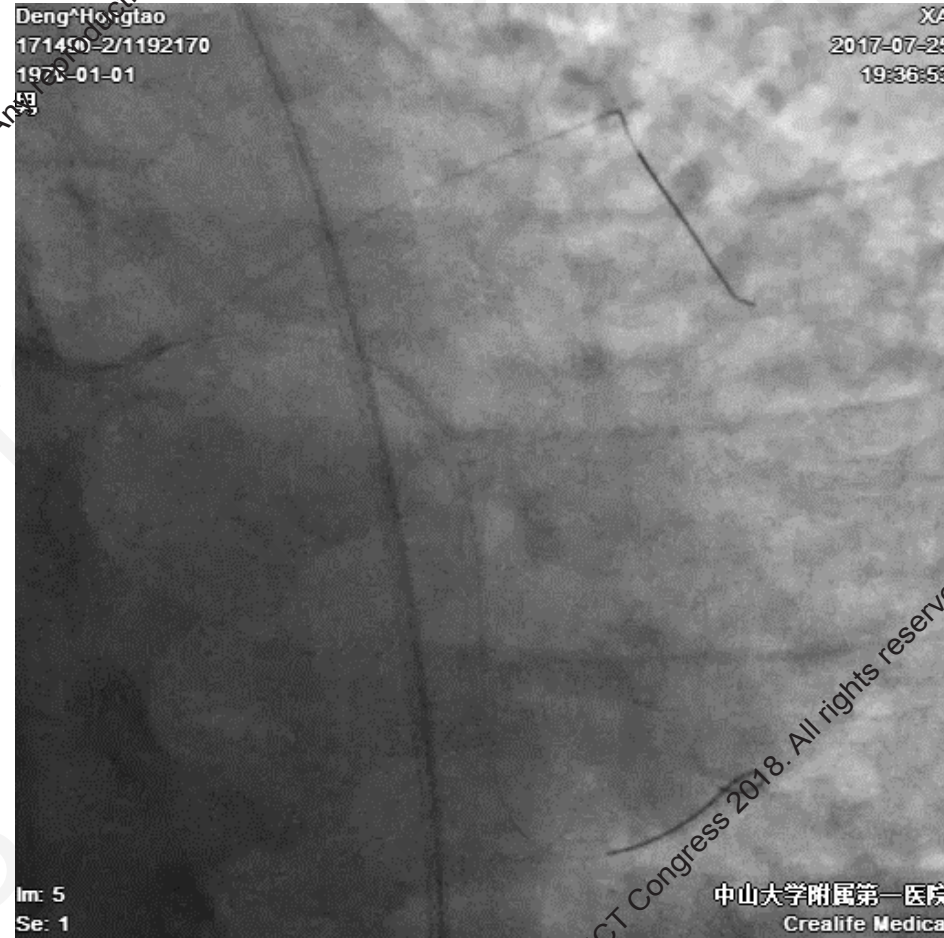
**BP kept stable**

**Chest pain relieved 20mins later**

**Transfer to cathlab**

2018 © AICT Congress 2018. All rights reserved. Any reproduction even in part is prohibited.

# Back to the cathlab

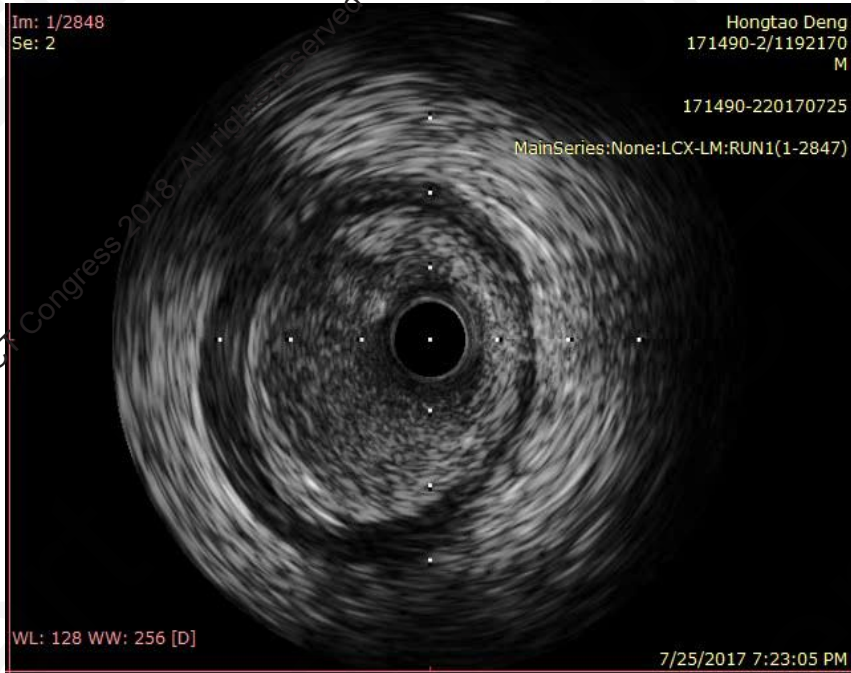

2018 © AICT Congress 2018. All rights reserved - Any reproduction even in part is prohibited.

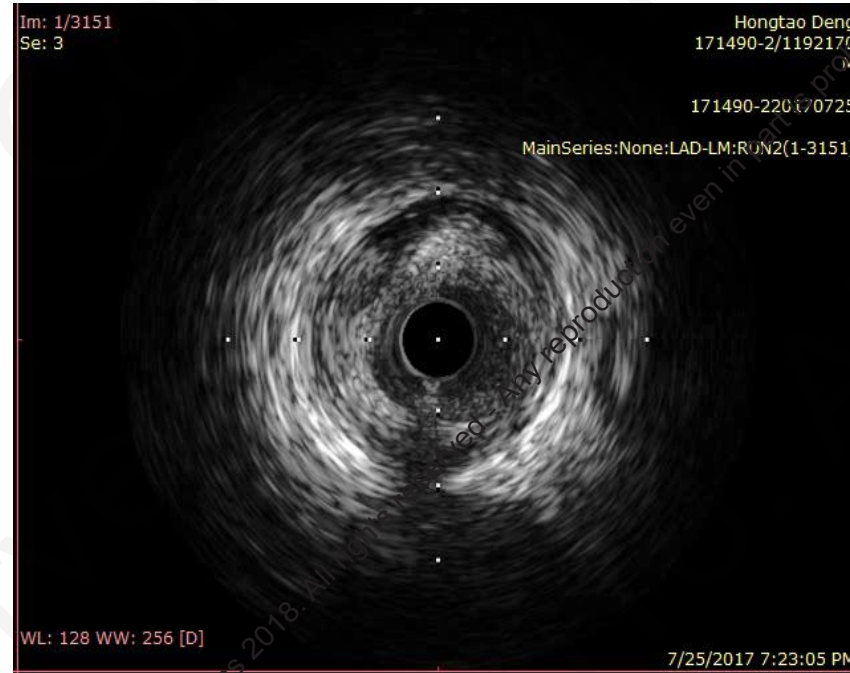
2018 © AICT Congress 2018. All rights reserved - Any reproduction even in part is prohibited.

## IVUS

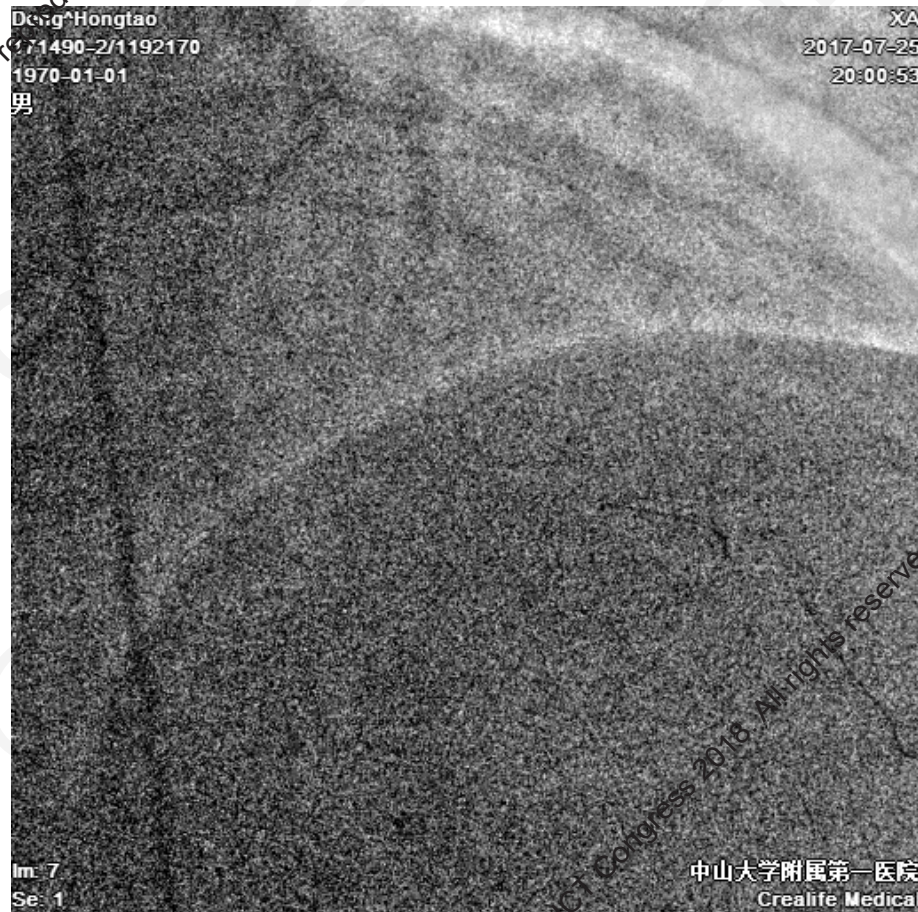### LM-LCX



### LM-LAD



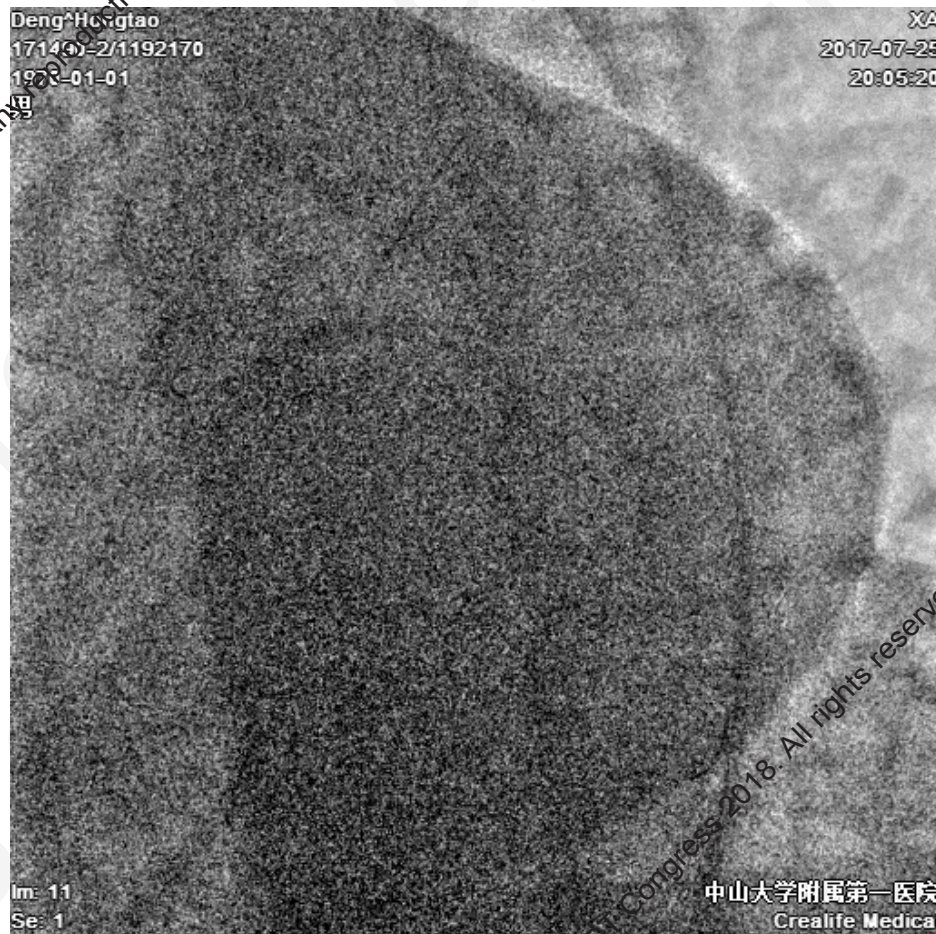
# DES 2.75\*29



2018 © AICT Congress 2018. All rights reserved - Any reproduction even in part is prohibited.

2018 © AICT Congress 2018. All rights reserved - Any reproduction even in part is prohibited.

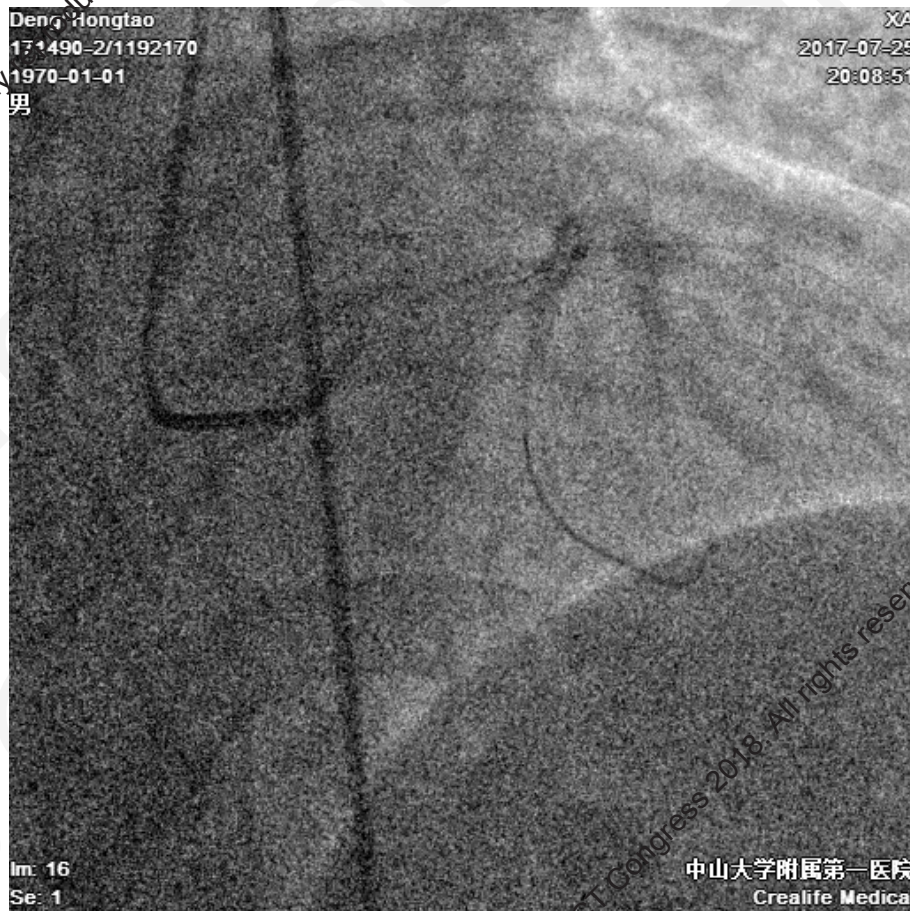
# DES 3.0\*18



2018 © AICT Congress 2018. All rights reserved - Any reproduction even in part is prohibited.

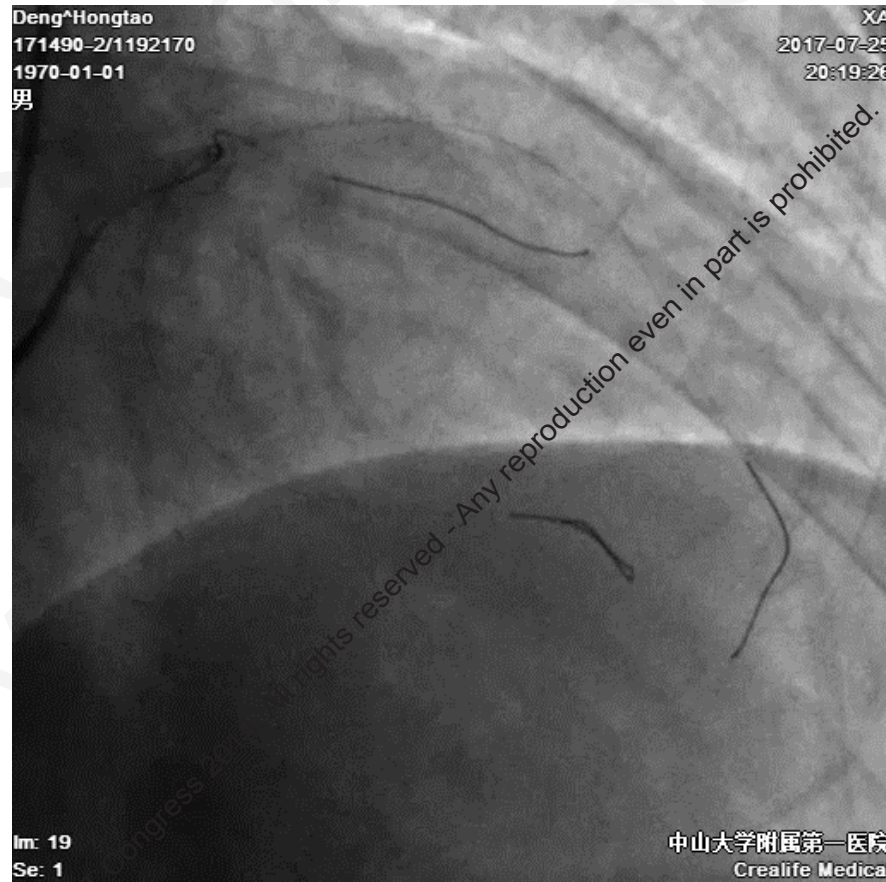
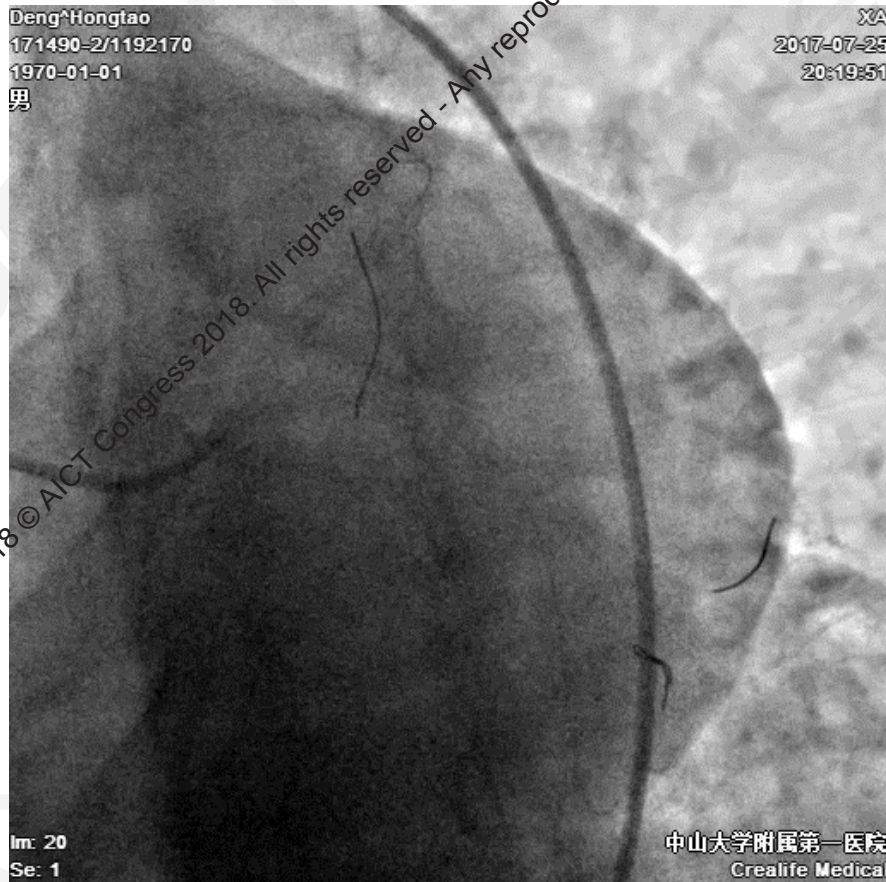
2018 © AICT Congress 2018. All rights reserved - Any reproduction even in part is prohibited.

# DES 3.5\*23





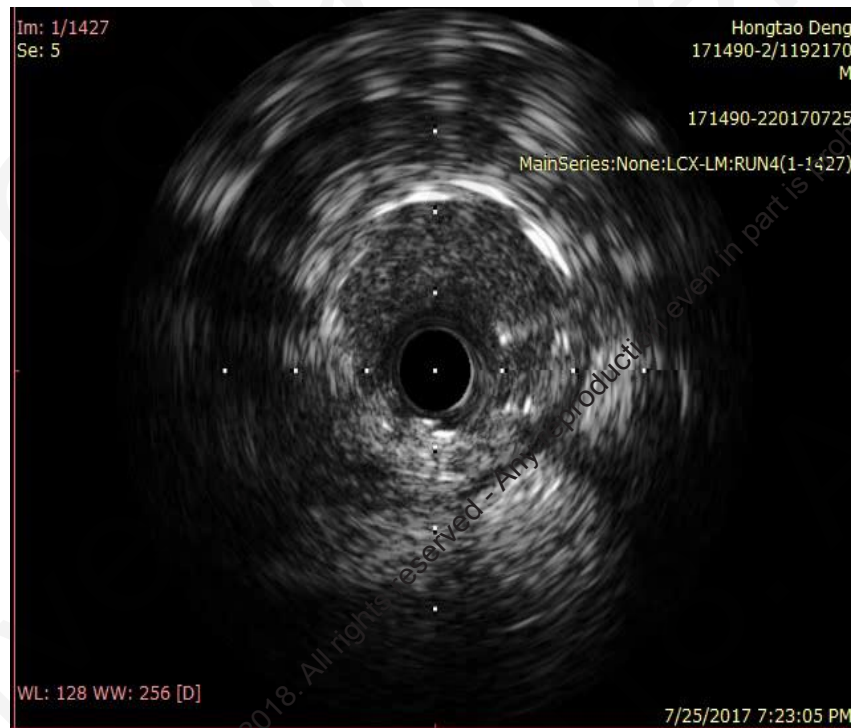
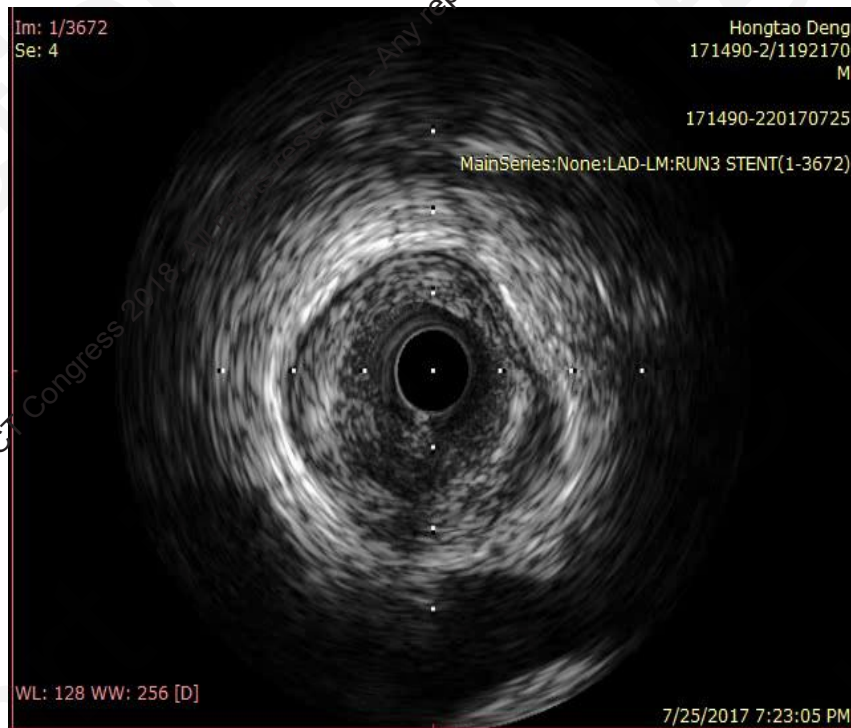
## Final



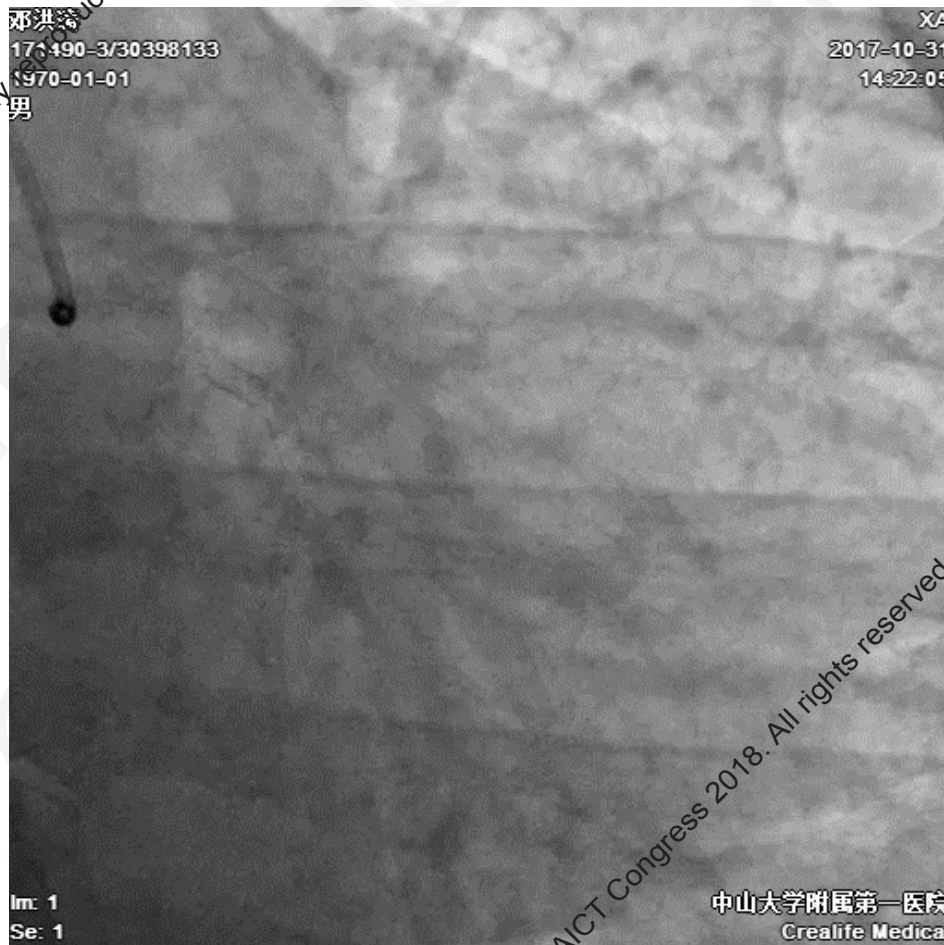# IVUS

## LM-LAD

## LM-LCX



# 3mo FU



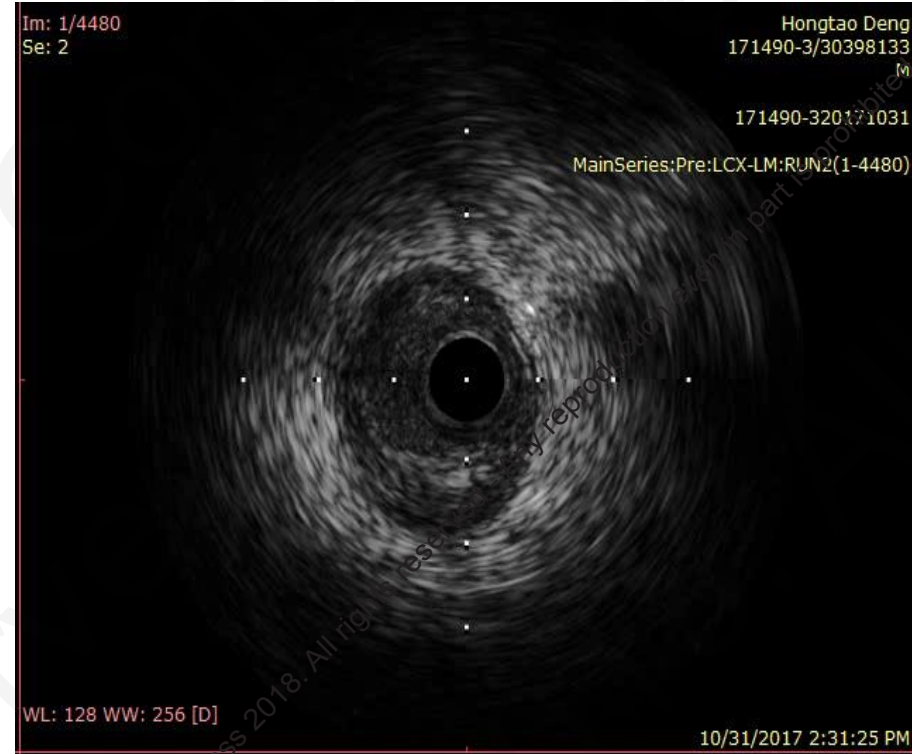
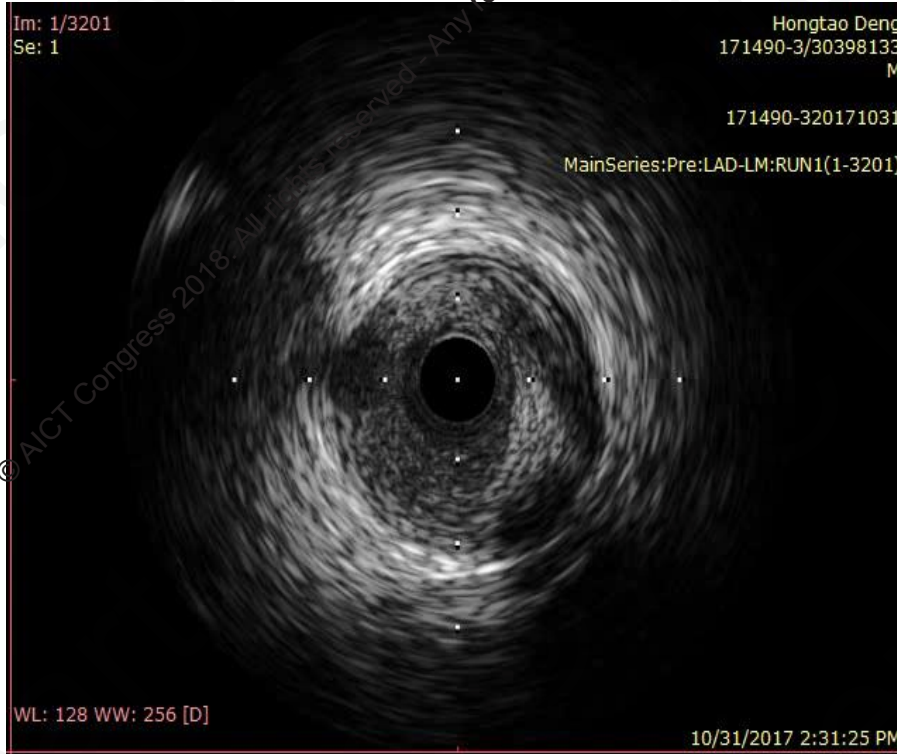
2018 © AICT Congress 2018. All rights reserved - Any reproduction even in part is prohibited.

2018 © AICT Congress 2018. All rights reserved - Any reproduction even in part is prohibited.

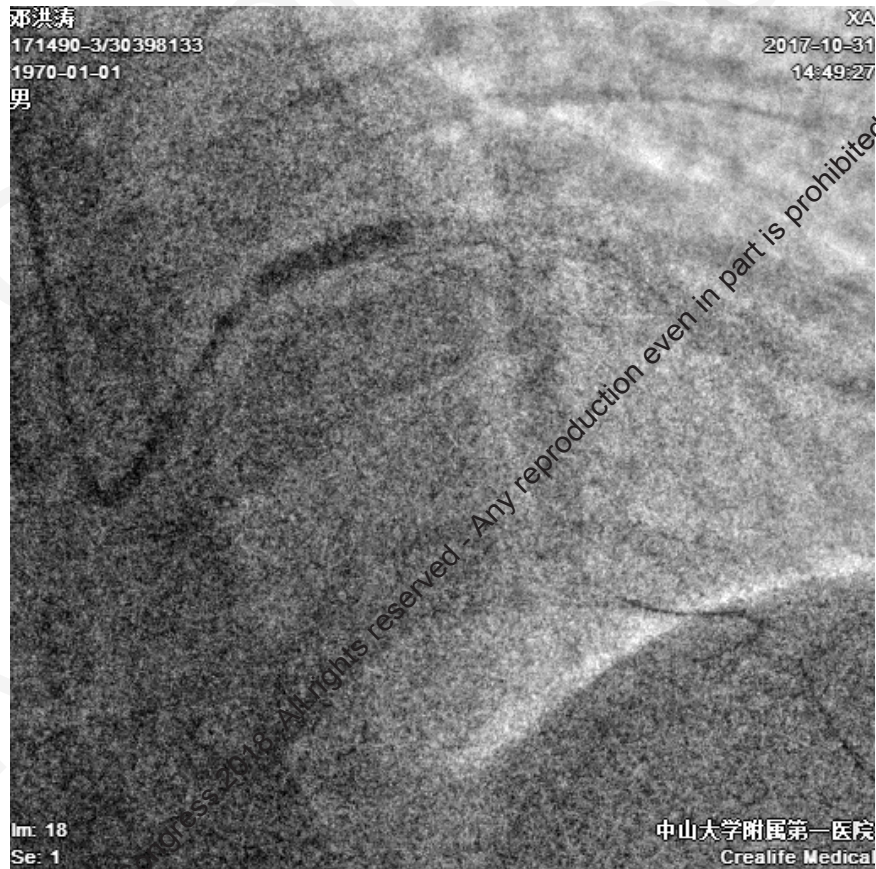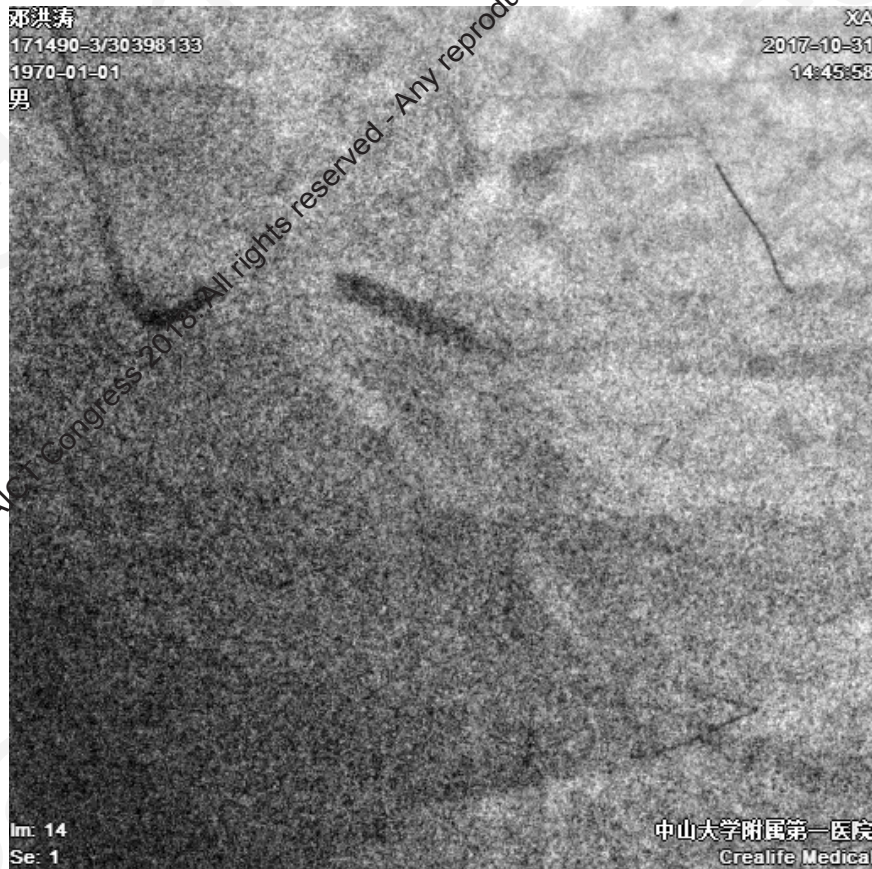## IVUS

### LM-LAD

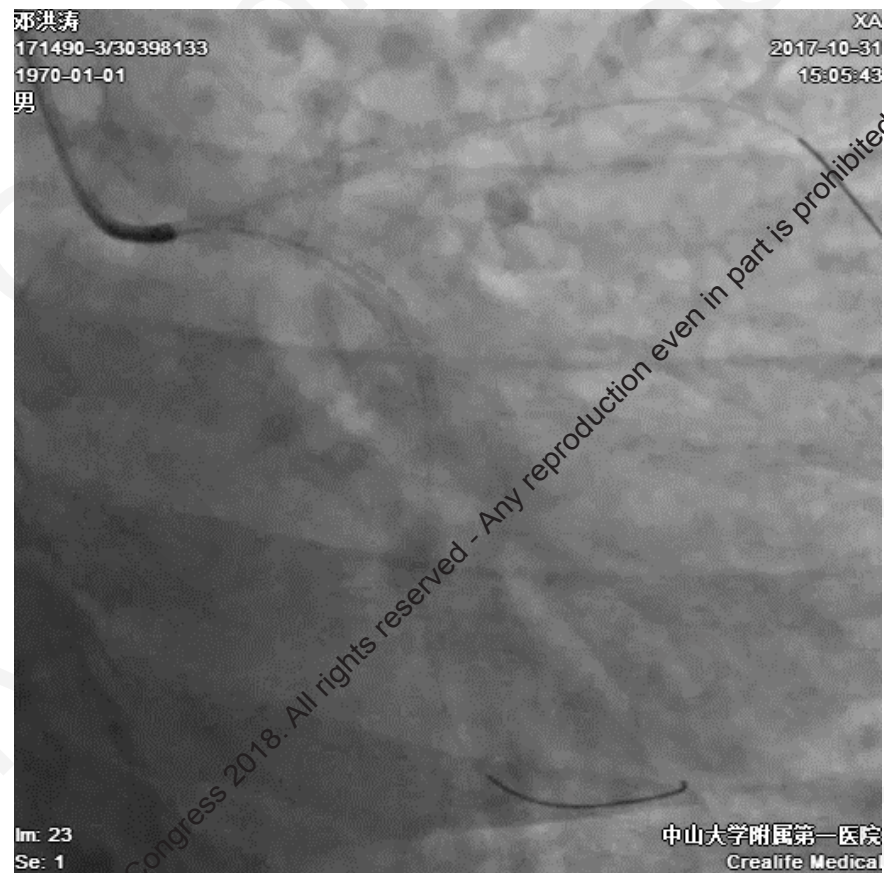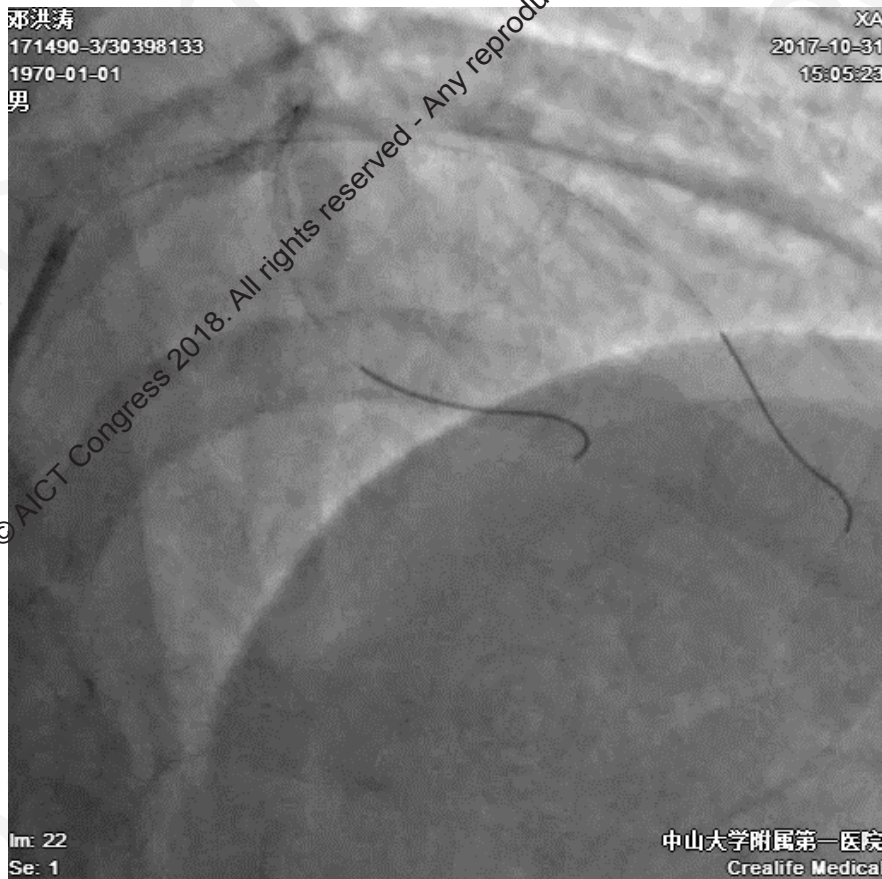### LM-LCX



## Post-dilate



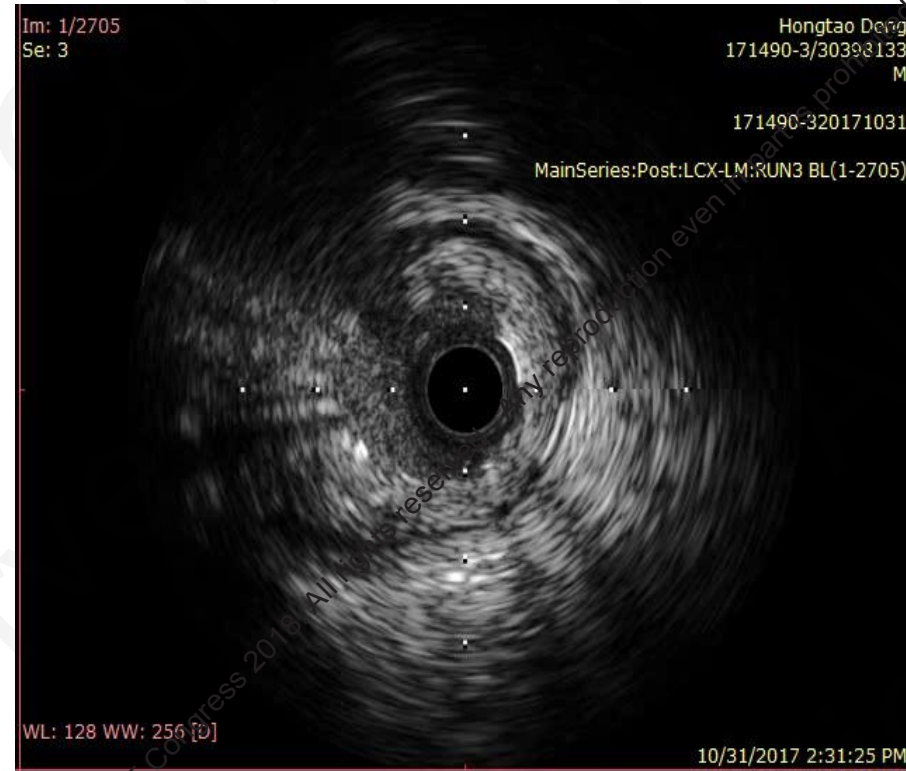
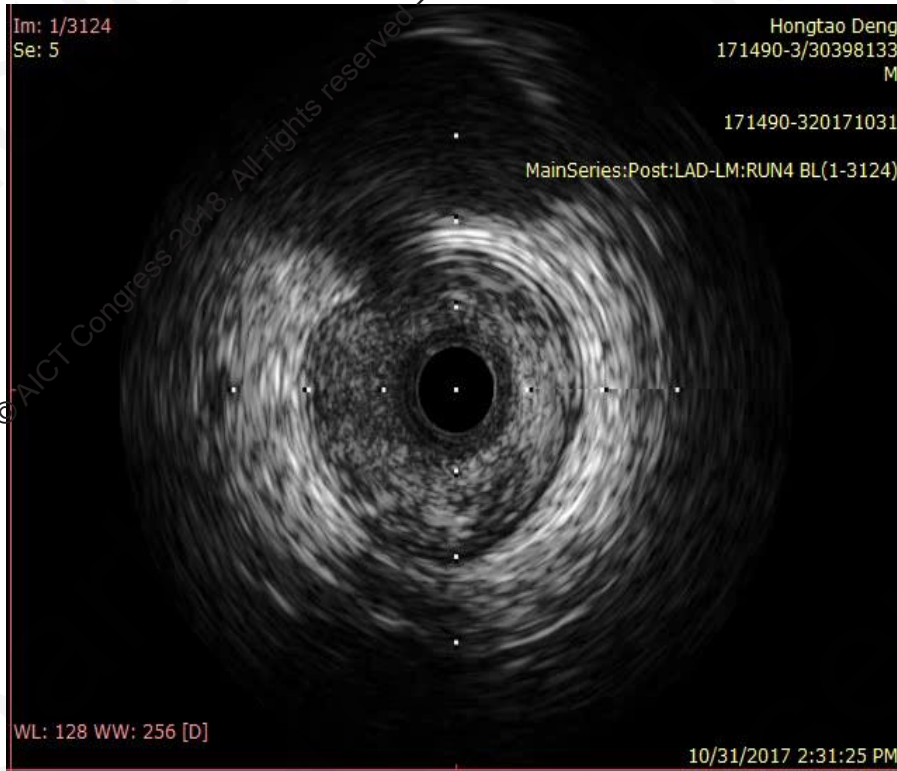
## Final



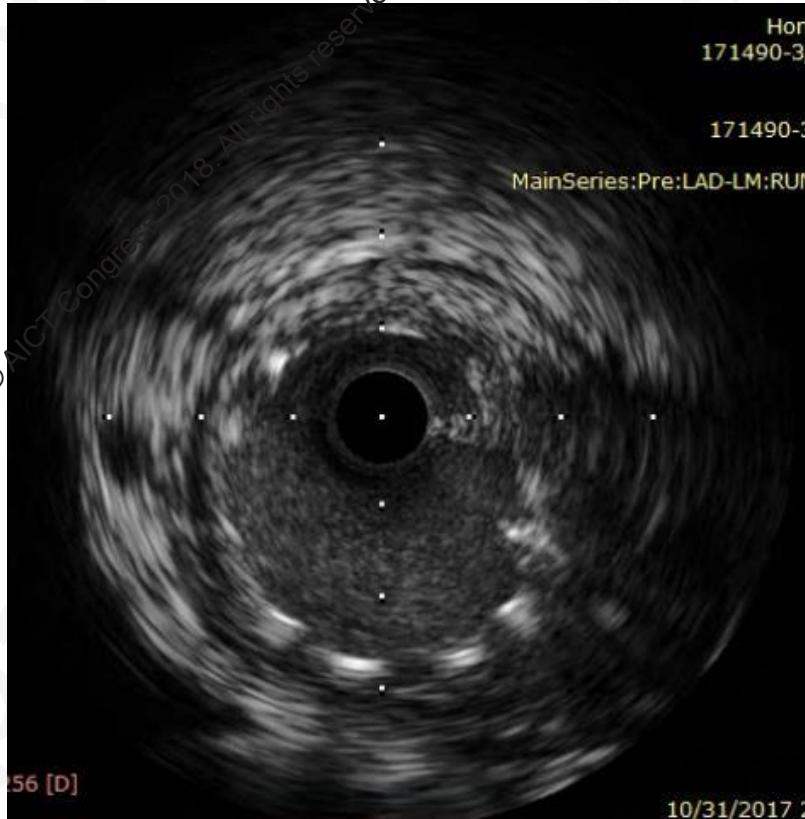
# IVUS after Post-dilate

**LM-LAD**

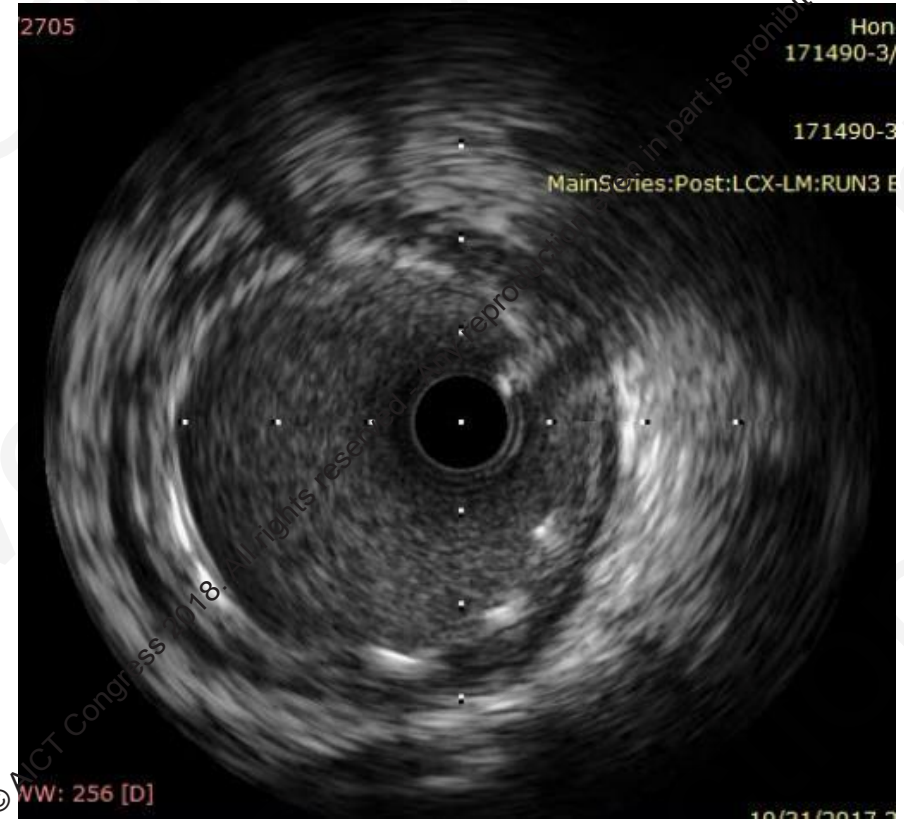
**LM-LCX**



## LM before postdilate



## LM after postdilate





# Personal Experience

- Don't post-dilate the stent by a semi-compliance balloon
- Don't let the post-dilate balloon go outside the stent
- If there is suspected hematoma, don't hesitate to use intra cavity imaging
- Make sure you have blocked the hematoma
- Recheck IVUS after hematoma organization and absorption and fix the stent malapposition



2018 © AICT Congress 2018. All rights reserved - Any reproduction even in part is prohibited.

***Thank you!***

2018 © AICT Congress 2018. All rights reserved - Any reproduction even in part is prohibited.

14<sup>th</sup>

# AICT

ASIAN INTERVENTIONAL CARDIOVASCULAR THERAPEUTICS  
THE OFFICIAL CONGRESS OF APSIC



7 - 9th September 2018

Hong Kong

Convention and Exhibition Centre (HKCEC)

2018 © AICT Congress 2018. All rights reserved - Any reproduction even in part is prohibited.

2018 © AICT Congress 2018. All rights reserved - Any reproduction even in part is prohibited.