



OCT in bifurcation lesion

Dr. Yeung Kwok Kit Lawrence
Tuen Mun Hospital



Bifurcation lesion

- ▶ **Provisional stenting and avoidance of unnecessary SB stenting in generally accepted strategy**
- ▶ **However sometimes 2 stents strategy is necessary in true bifurcation lesion**
- ▶ **Question is how to decide??**



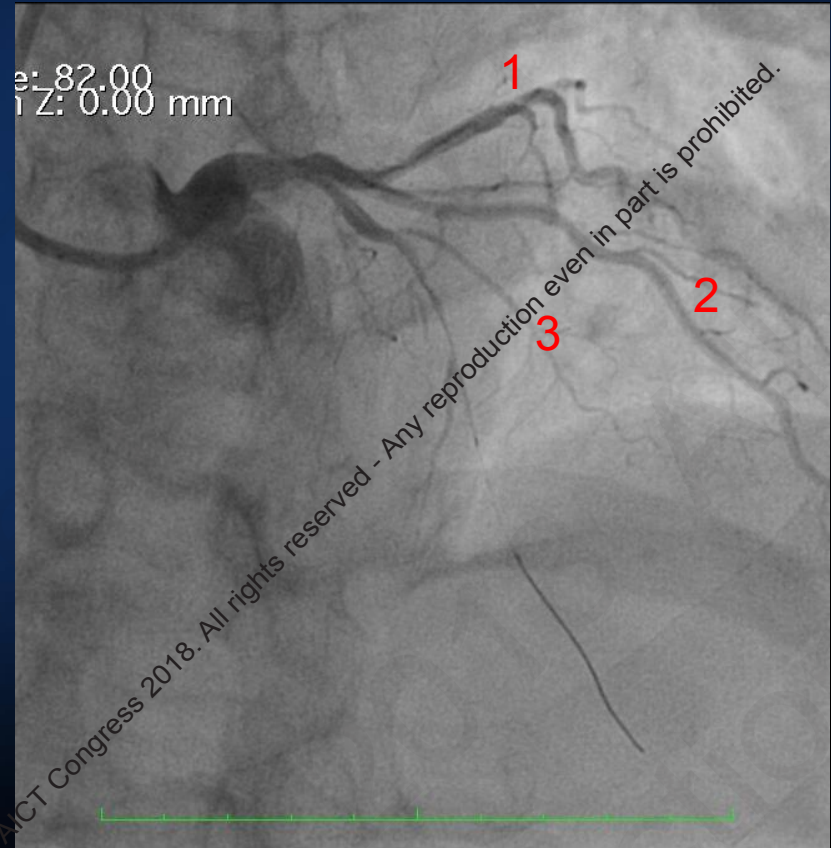
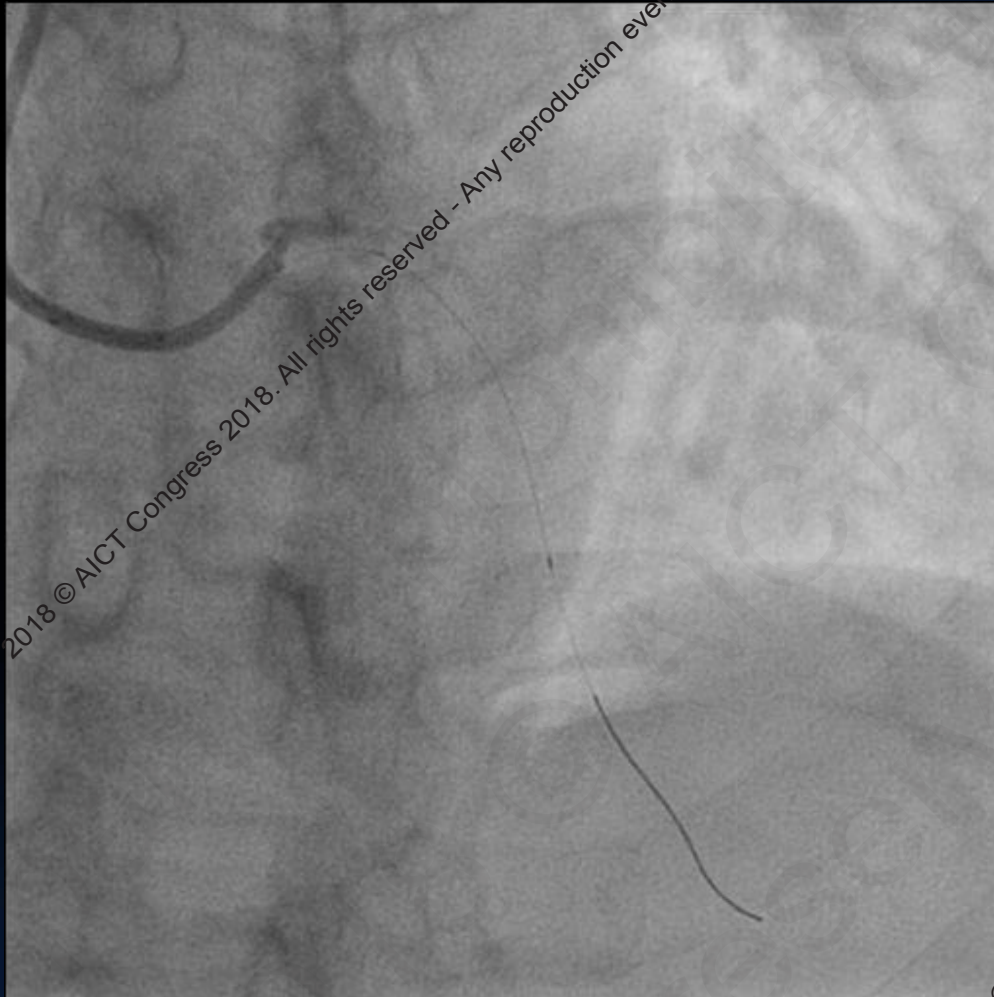
Bifurcation lesion

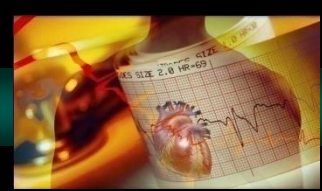- ▶ **15-20% of PCI are bifurcation lesion**
- ▶ **~5% of provisional stenting resulting in SB occlusion**



PCI

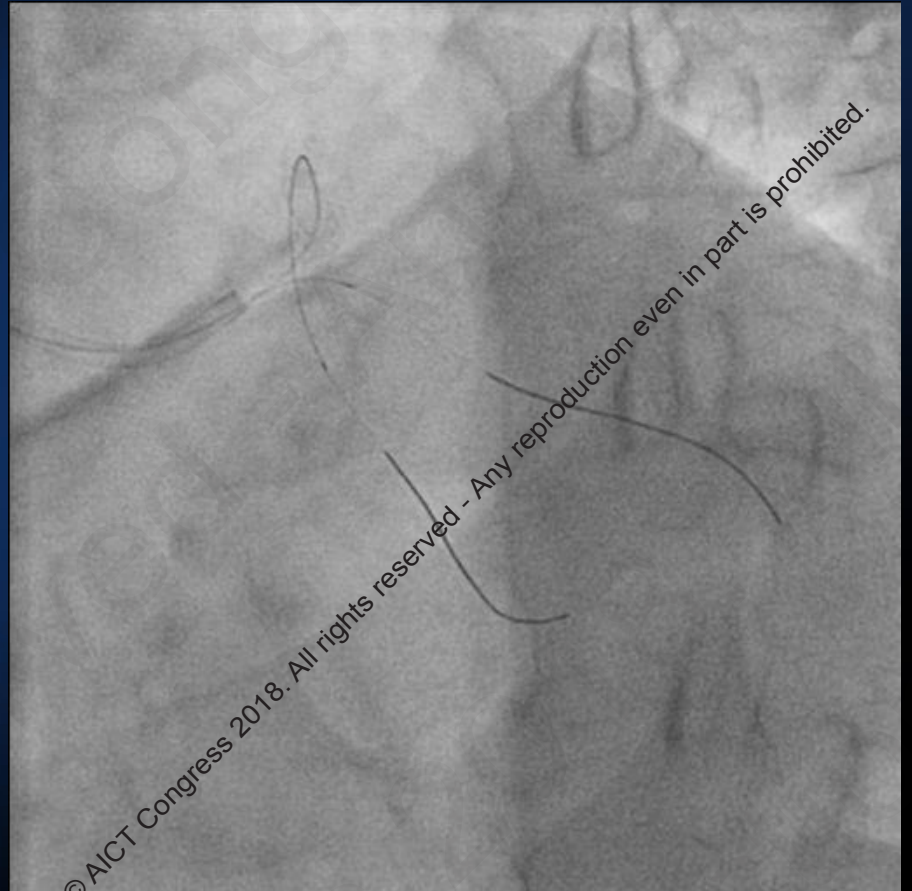
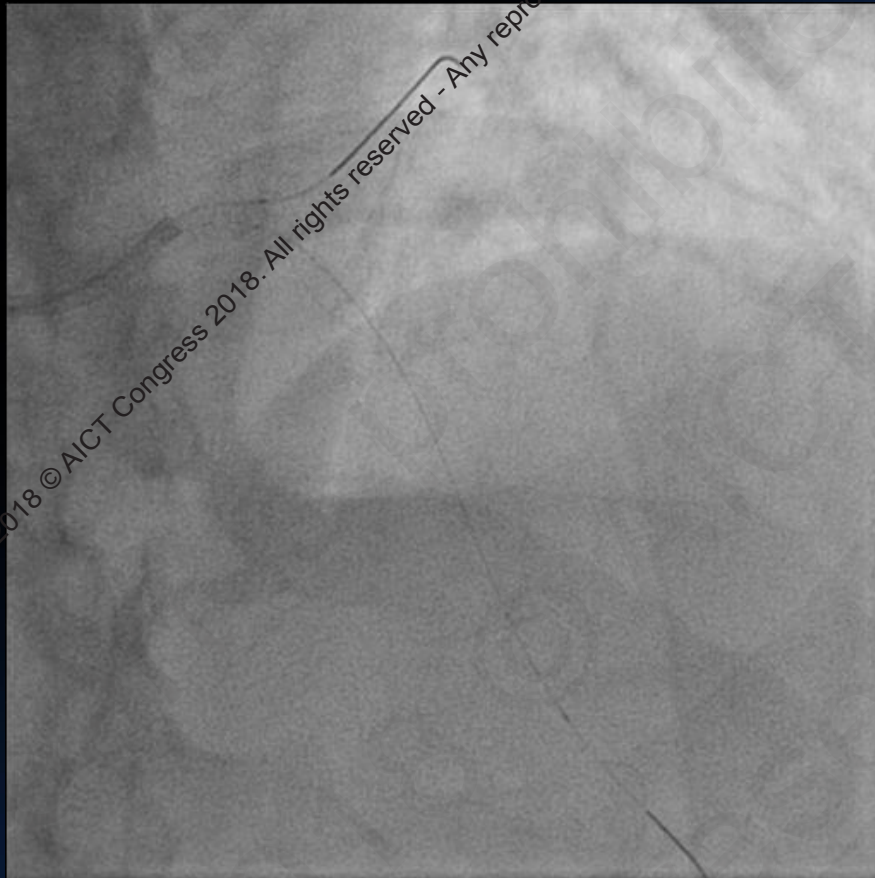Which one?





PCI

Which vessel closed?

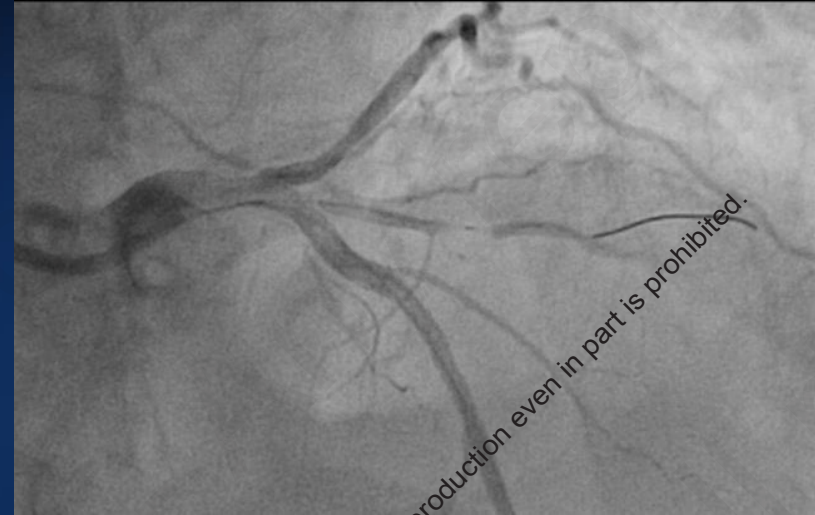
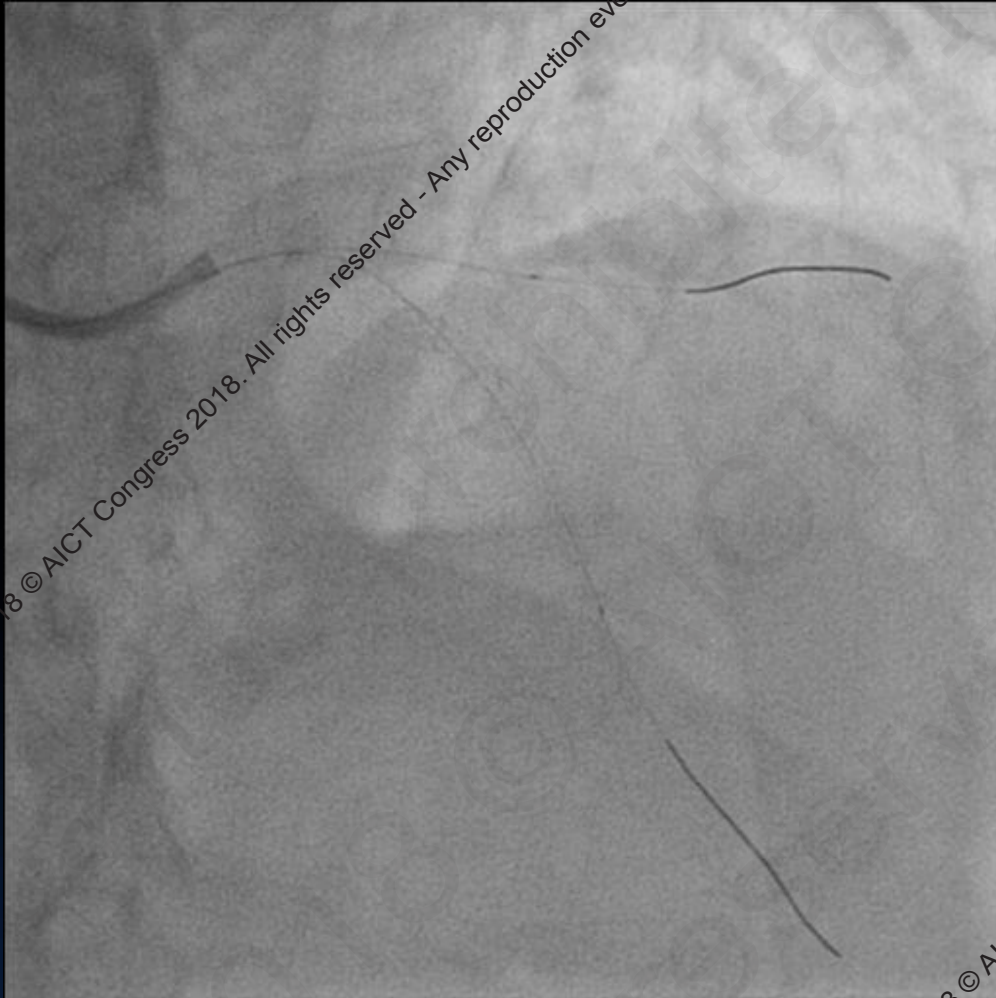
2018 © AICT Congress 2018. All rights reserved - Any reproduction even in part is prohibited.

2018 © AICT Congress 2018. All rights reserved - Any reproduction even in part is prohibited.



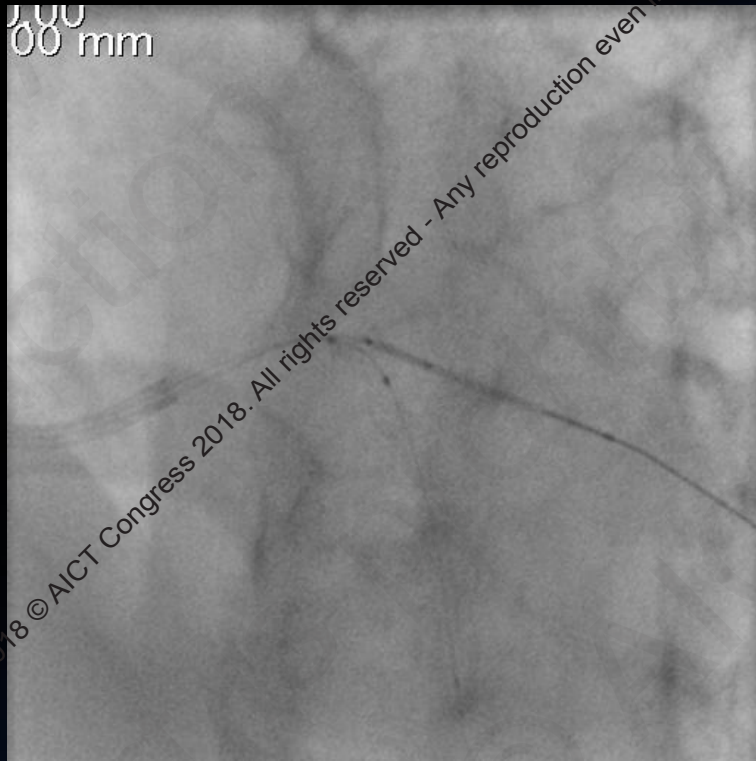
PCI



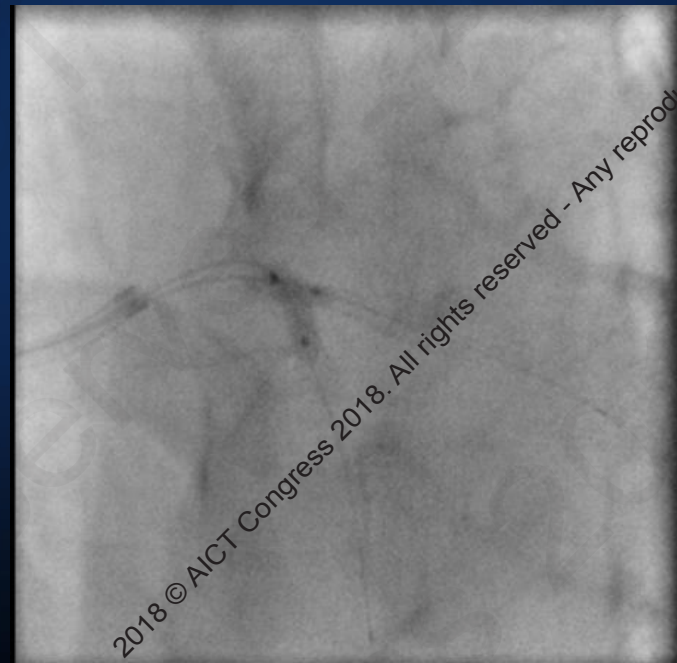
Sub-intimal hematoma
TIMI III flow




PCI

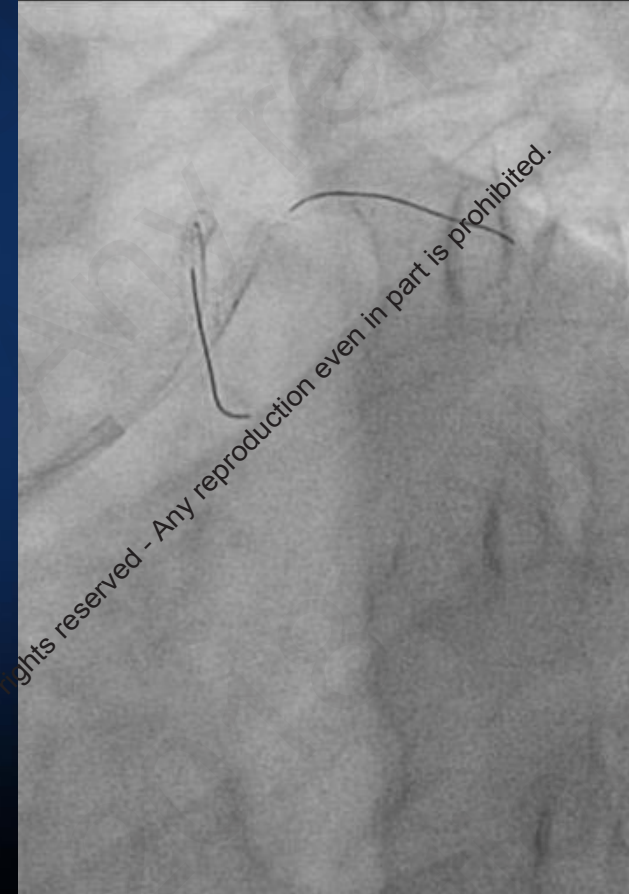
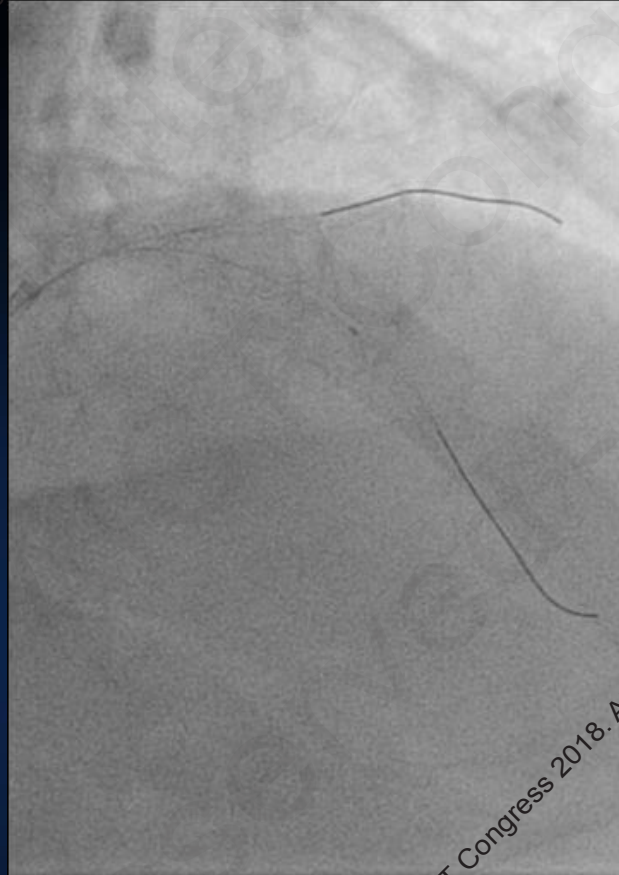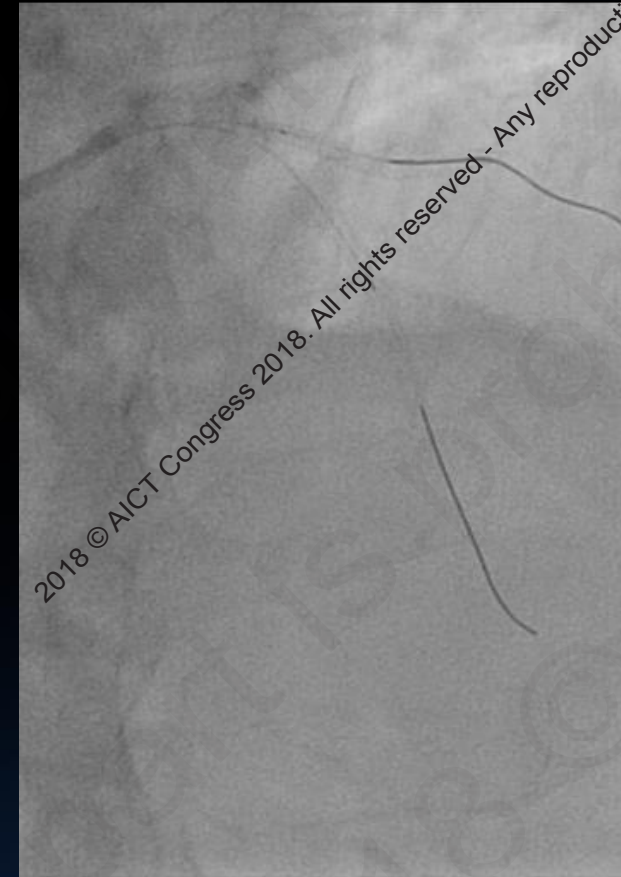


- DES 2.0*30
- NC 3.0*15 in LAD
- NC 2.25*8 in D1
- Sequential kissing
- IVUS check





PCI





What factors predict SB closure?

- ▶ Reference vessel diameter of SB
- ▶ SB ostial stenosis, length of stenosis
- ▶ TIMI flow grade of SB before MV stenting
- ▶ Bifurcation angle
- ▶ Diameter ratio between MV/SB
- ▶ LVEF
- ▶ Presence of thrombus
- ▶ ?calcification

- ▶ Role of OCT ??

ESC guideline

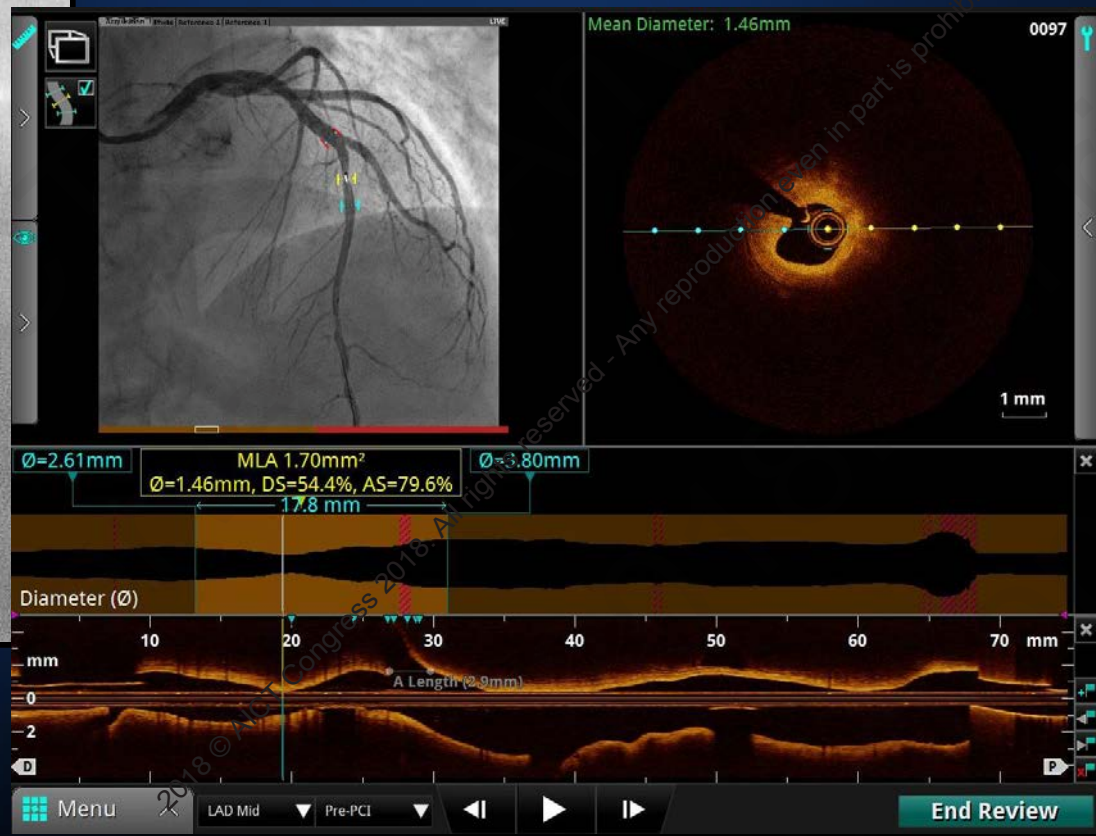
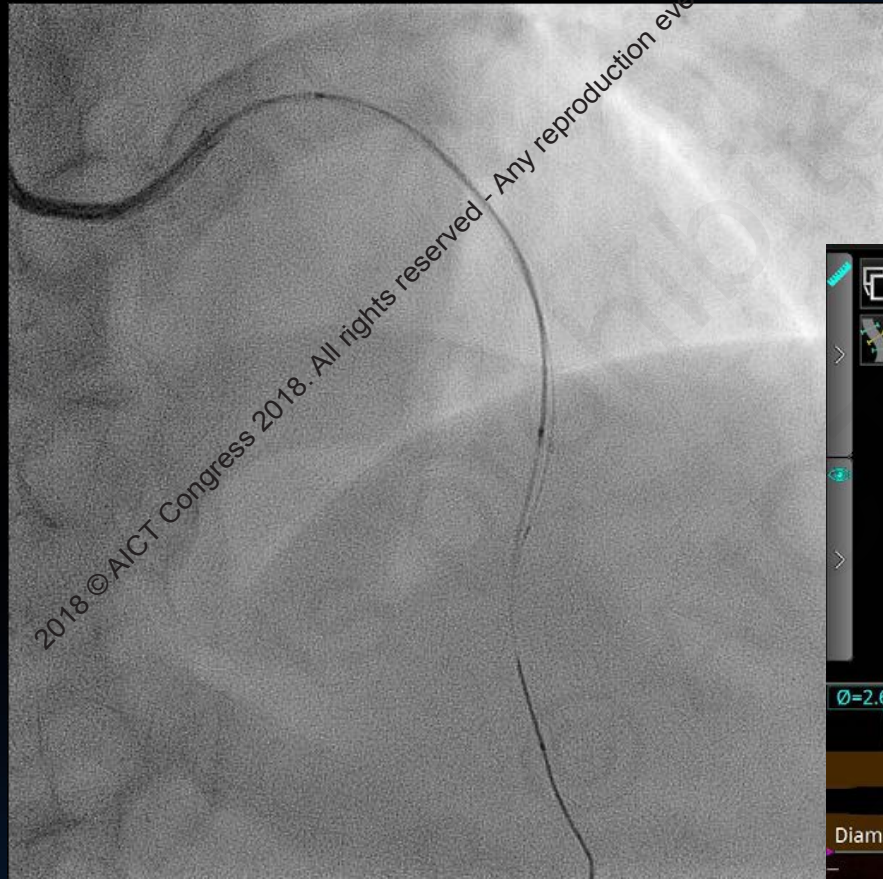
Recommendations	Class ^a	Level ^b
IVUS or OCT should be considered in selected patients to optimize stent implantation. ^{603,612,651–653}	IIa	B
IVUS should be considered to optimize treatment of unprotected left main lesions. ³⁵	IIa	B

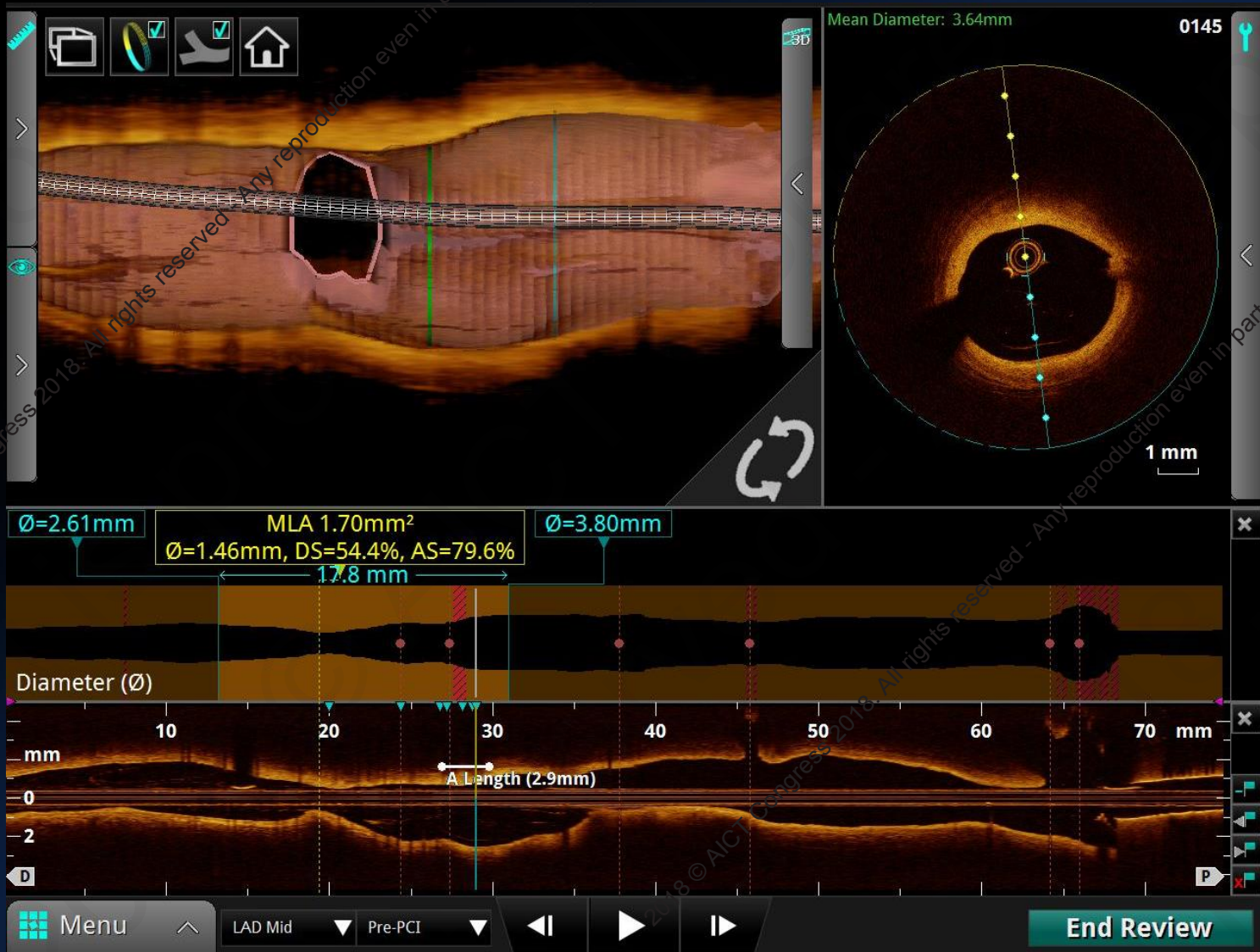
? Role of intravascular imaging in bifurcation PCI



Case 1

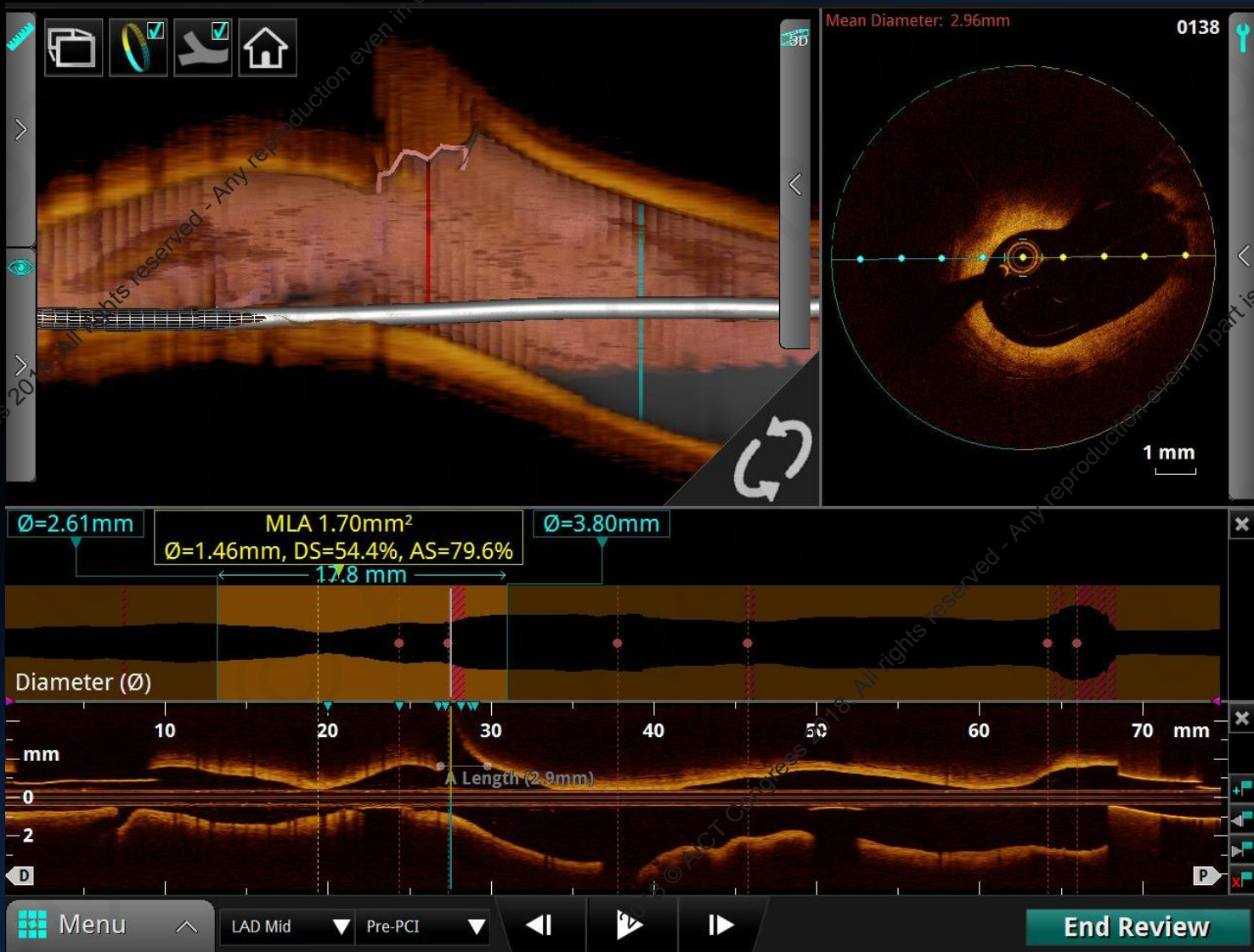
- ▶ **58/M**
- ▶ **Smoker**
- ▶ **Good past health**
- ▶ **Admit for ACS, unstable angina**
- ▶ **ECG: SR, no definite ischemic change**
- ▶ **Tnl normal**

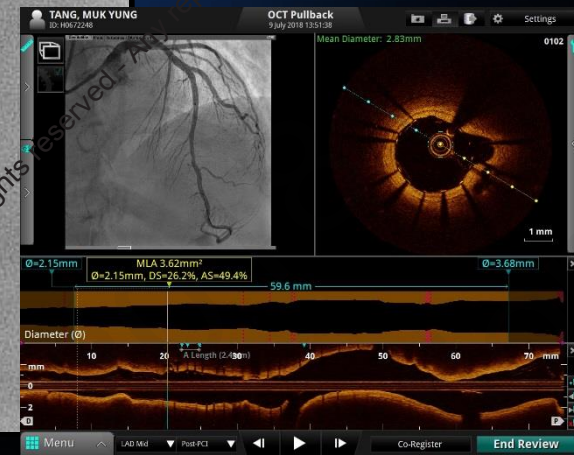
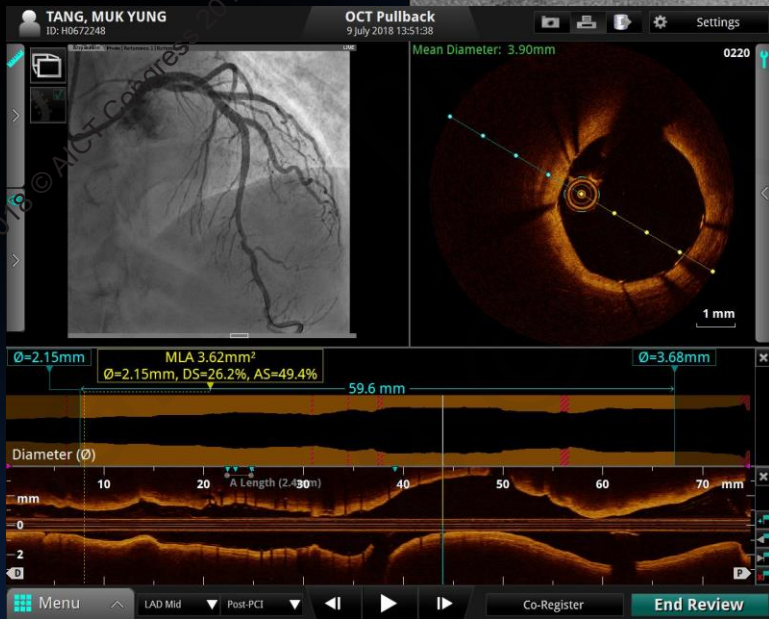
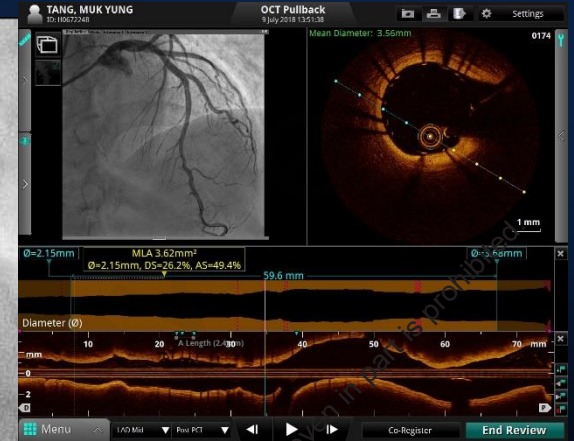
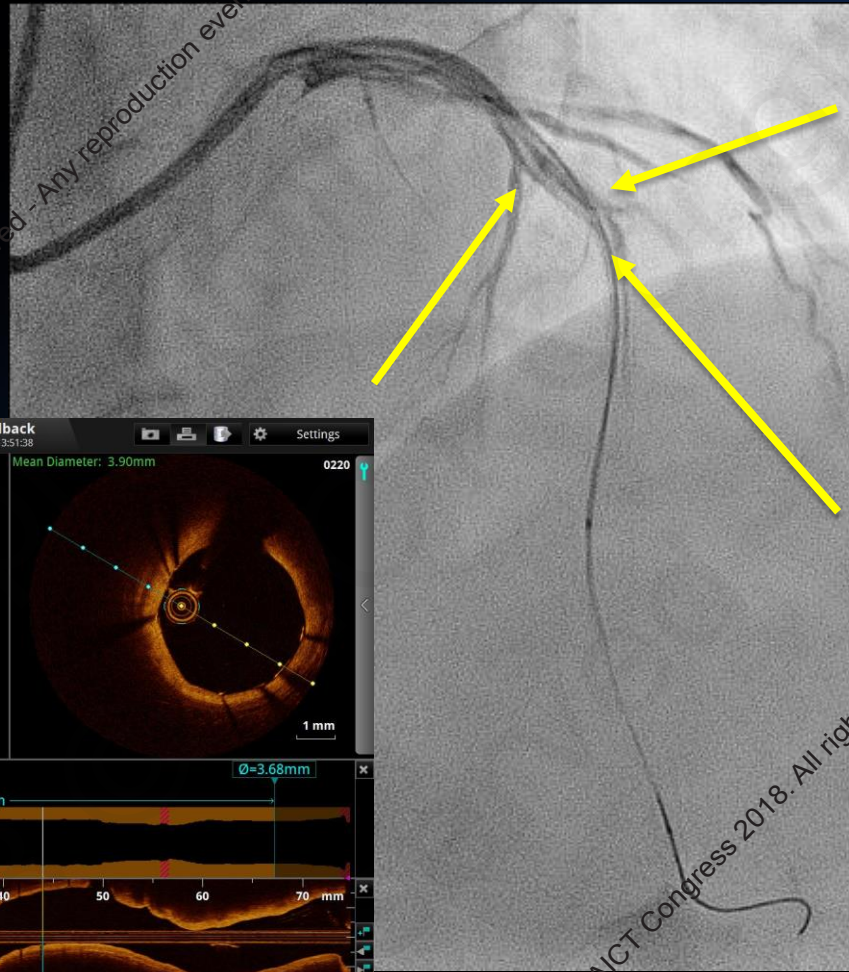




2018 © AICT Congress 2018. All rights reserved - Any reproduction even in part is prohibited.

2018 © AICT Congress 2018. All rights reserved - Any reproduction even in part is prohibited.





2018 © AICT Congress 2018. All rights reserved - Any reproduction even in part is prohibited.

2018 © AICT Congress 2018. All rights reserved - Any reproduction even in part is prohibited.

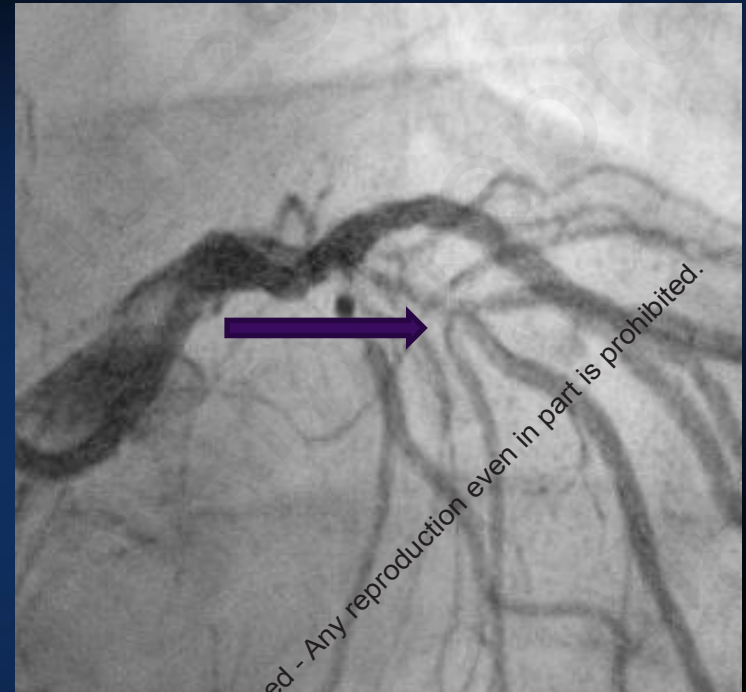
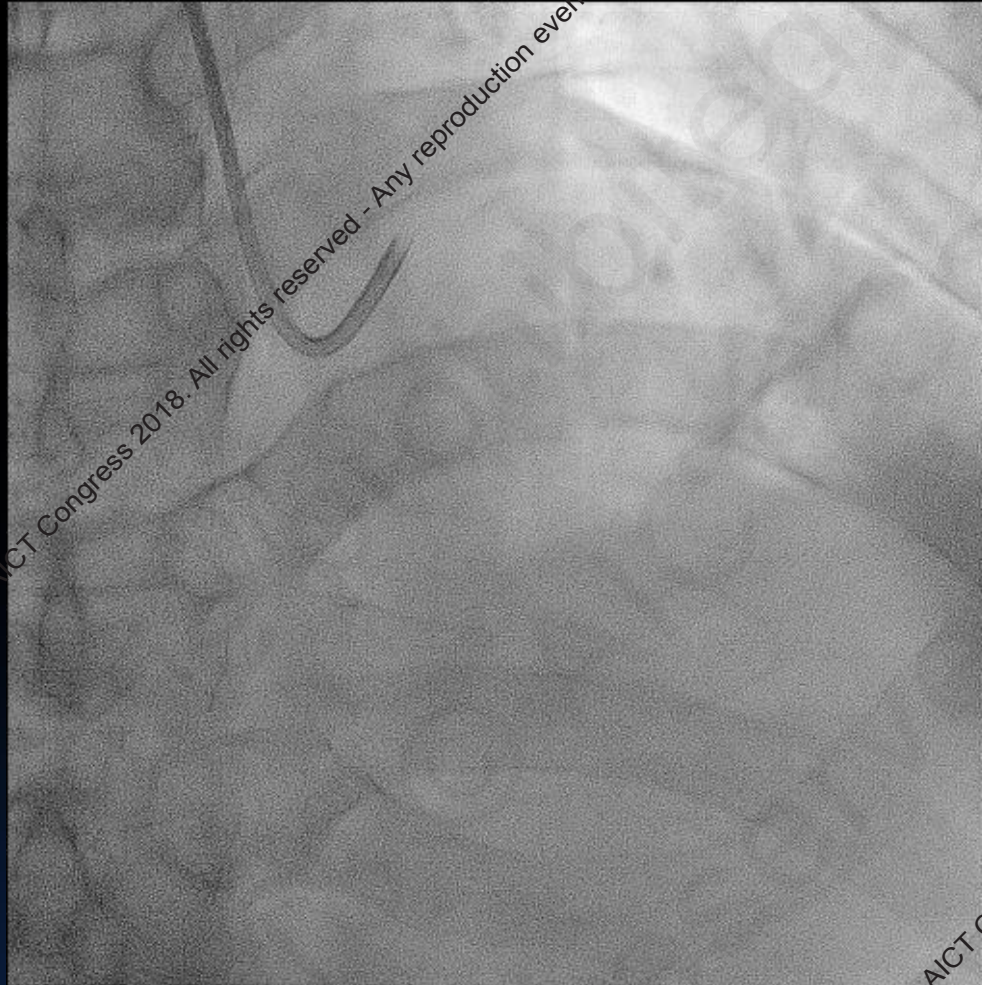


Case 2

- ▶ **Admit for shock and heart failure**
- ▶ **ECG: SR, ST depression over inferior leads**
- ▶ **Echo: EF 45%, global hypokinesia**
- ▶ **Coro: pLAD/D1 significant stenosis, dLCx subtotal occlusion but small, RCA minor disease**



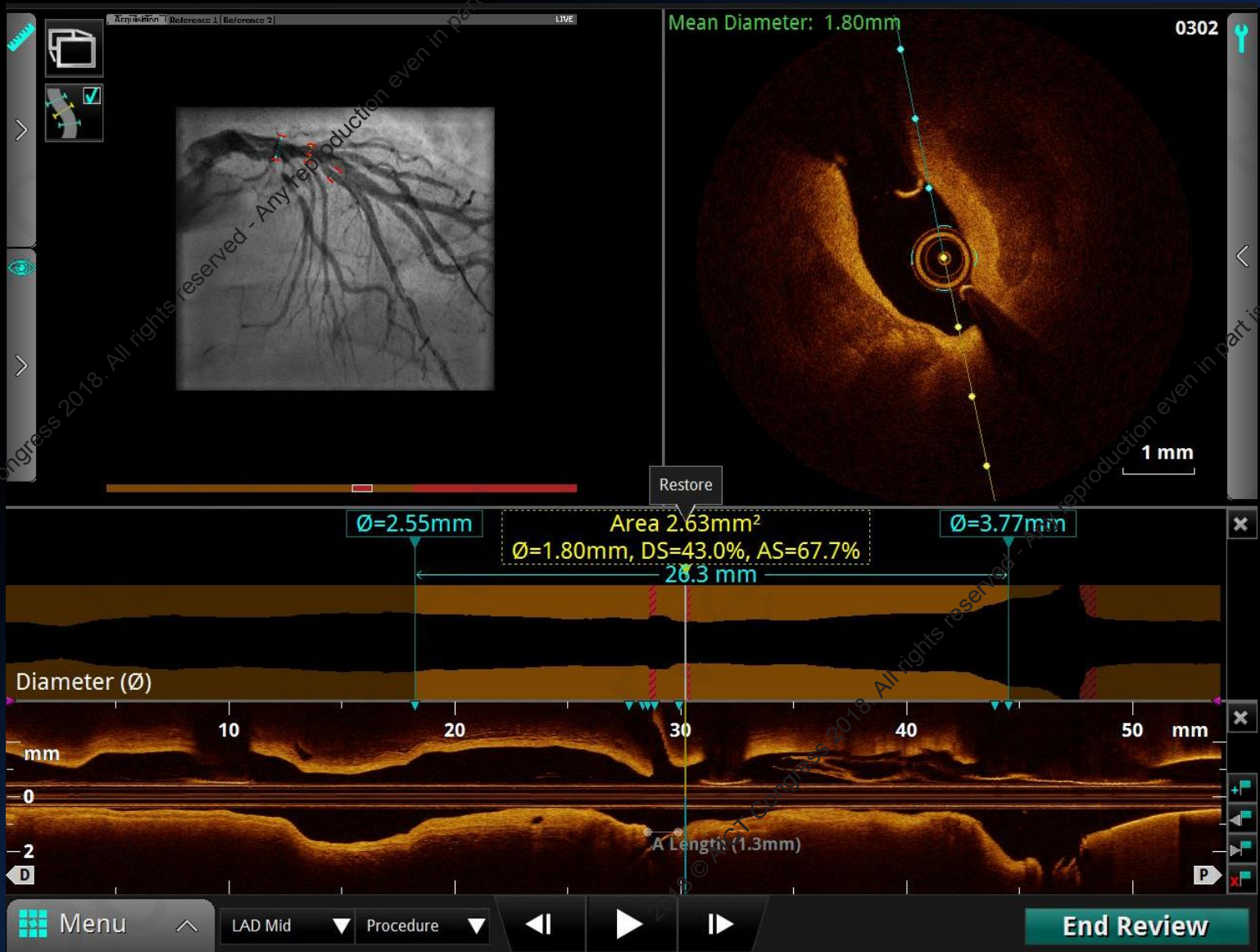
Case 2



LAD/D1 bifurcation lesion

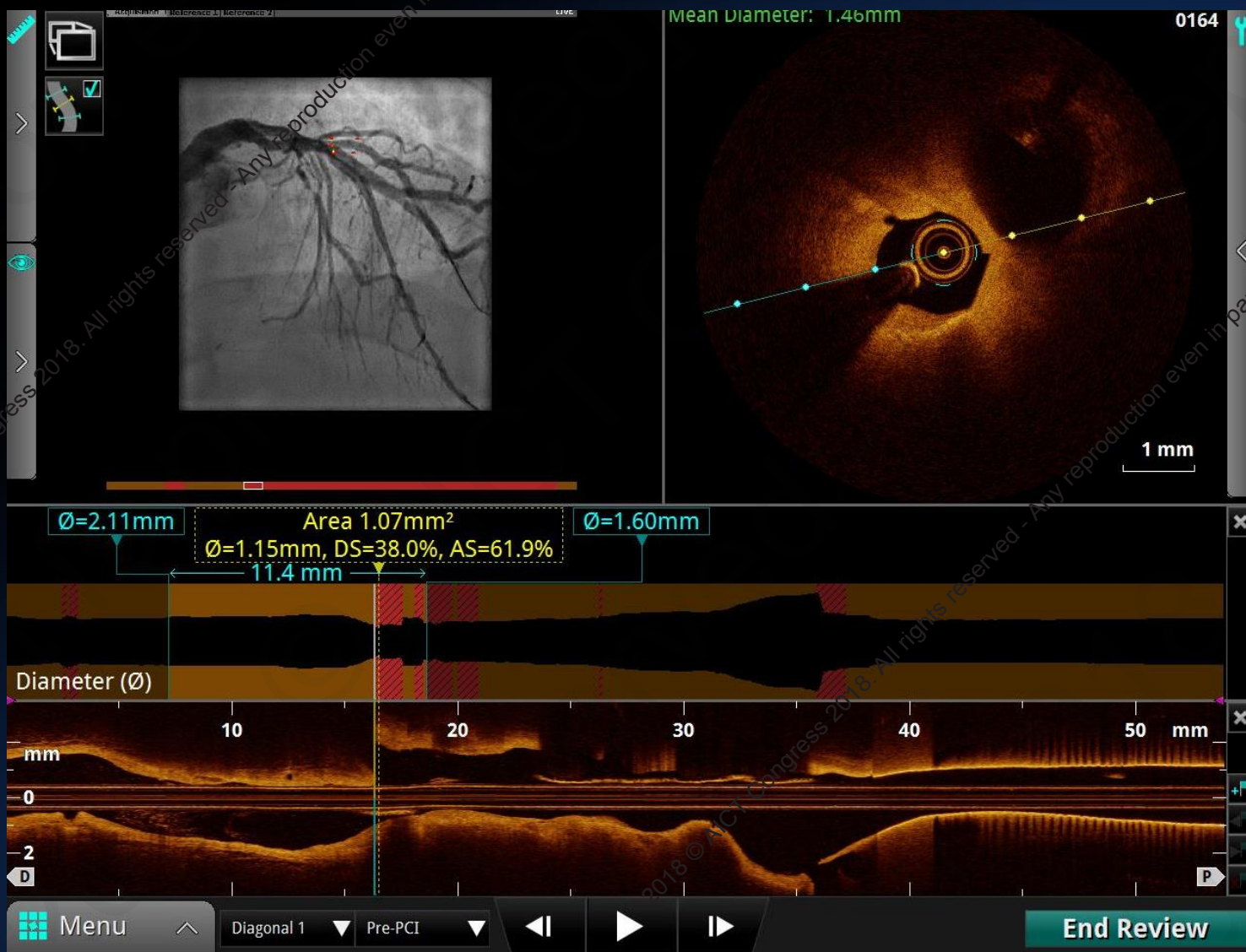


LAD calcified



2018 © AICT Congress 2018. All rights reserved - Any reproduction even in part is prohibited

Diagonal ostium severe plaque load





Strategy

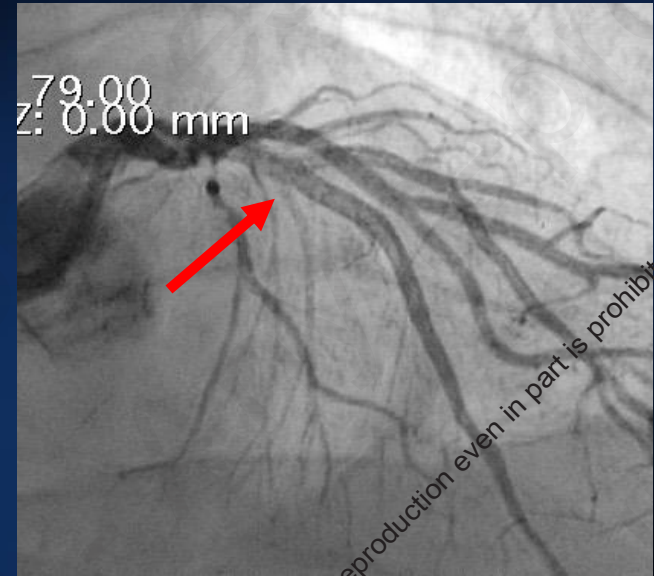
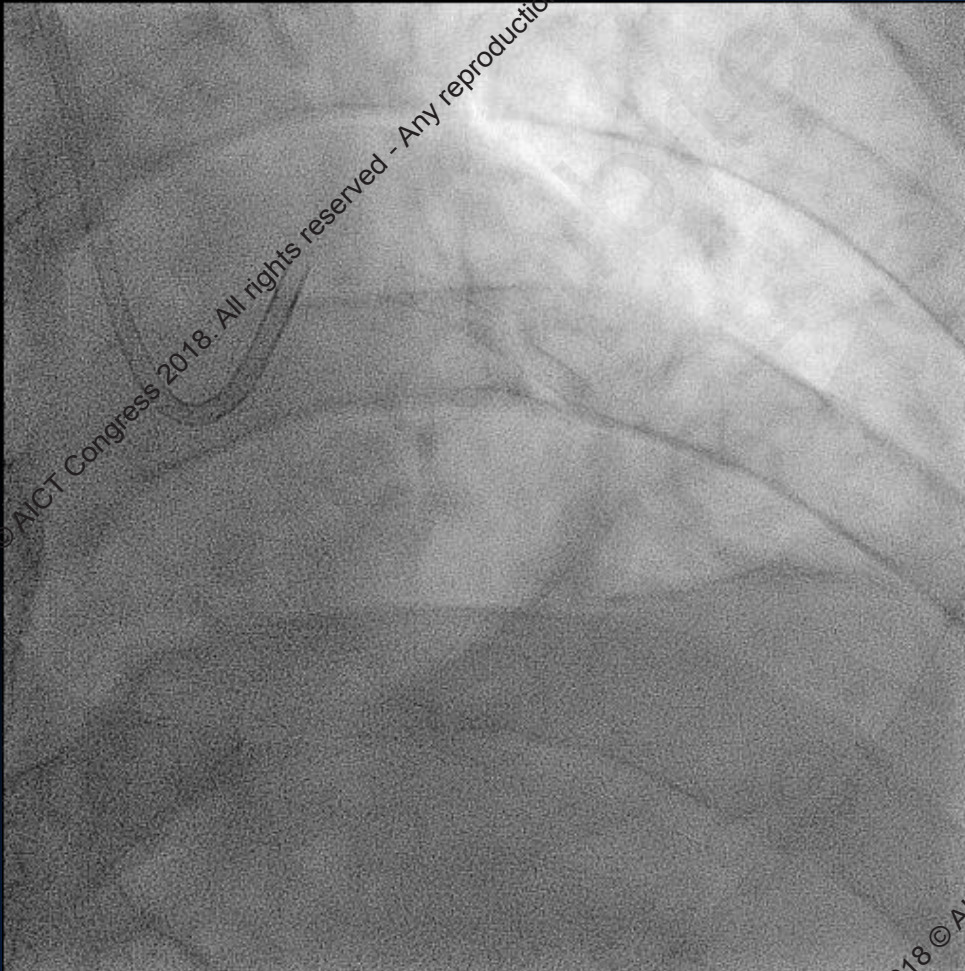
▶ 1 stent provisional

- Side branch pre-dilatation?
- Wire protection?
- Trapping balloon?
- Trapping Corsair?

▶ 2 stent

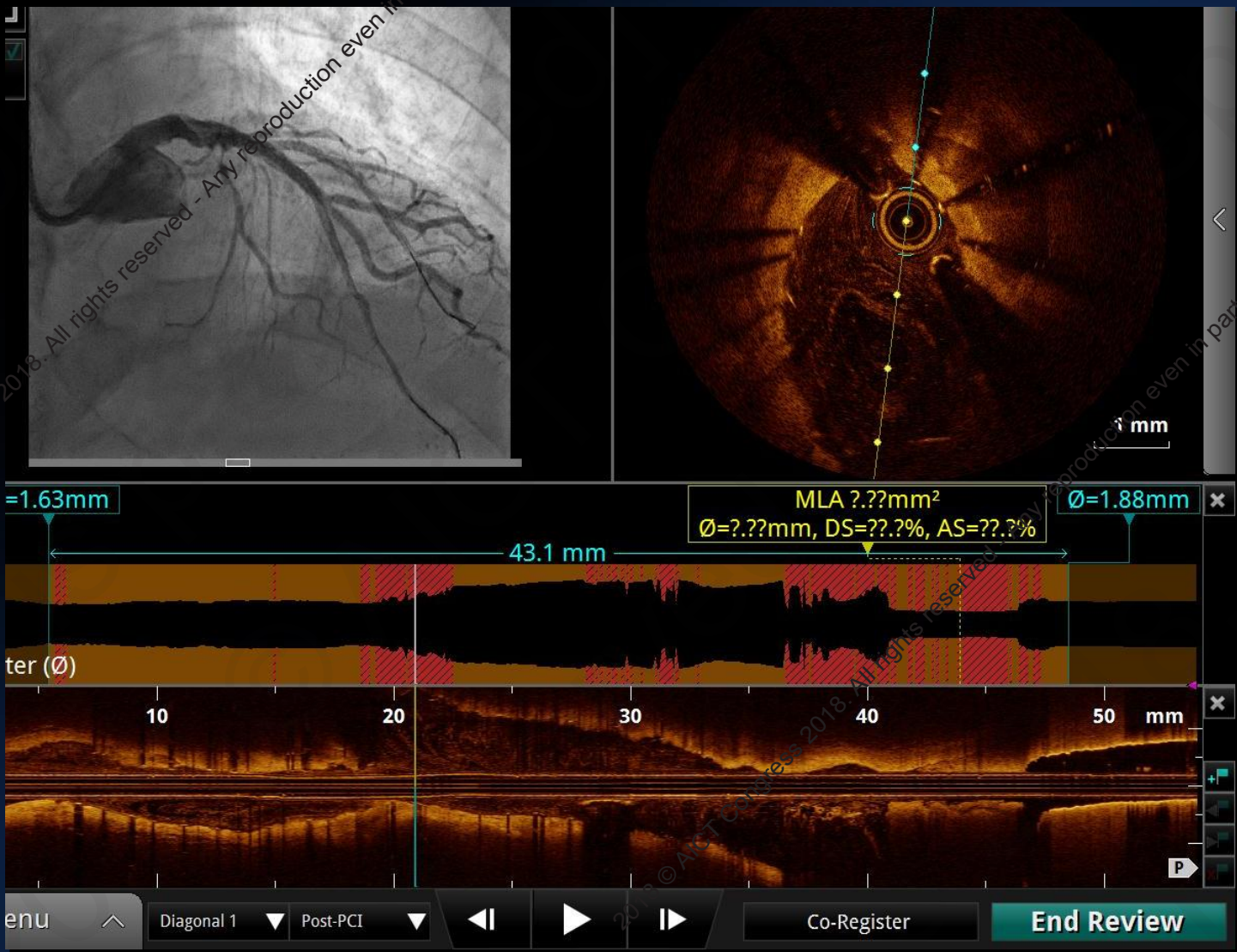
- Crush (Double kissing? Classical? Mini?)
- Culotte
- TAP

2 stent crush

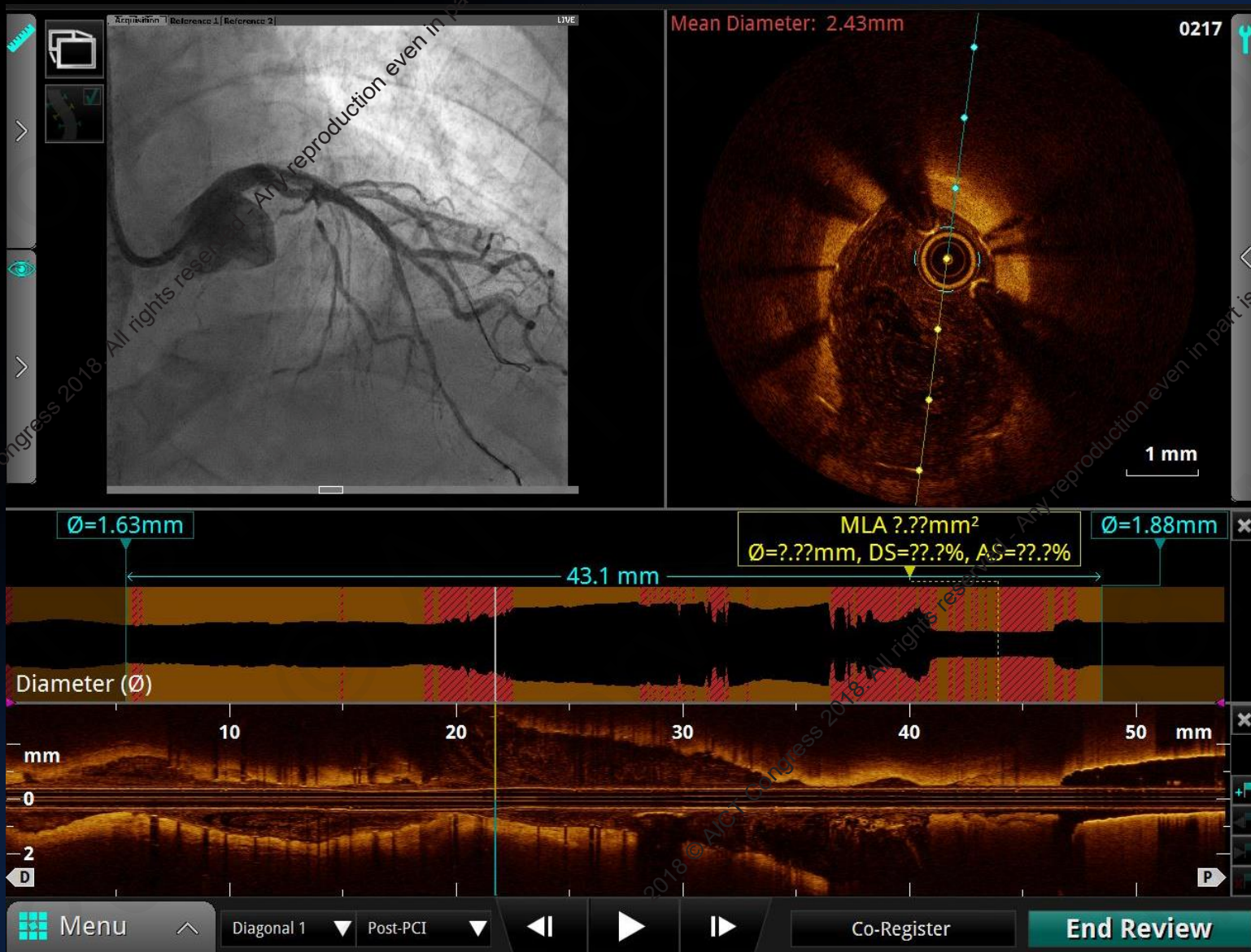


- Full coverage of all disease
- Minimize multiple metal layers
- Full apposition and expansion of stent
- Safe
- Fast

Final OCT after 2 stent crush



Final OCT after two stent crush





Take home message

- ▶ **Some bifurcation lesions have unpredictable behaviours**
- ▶ **OCT help to predict and direct the stenting strategy**
- ▶ **OCT can have clear image, to help improving the skills and decision making of operators**
- ▶ **Better stent size/length, landing zone, stent apposition and expansion detected**
- ▶ **I am still learning**



Thank you

2018 © AICT Congress 2018. All rights reserved - Any reproduction even in part is prohibited.

2018 © AICT Congress 2018. All rights reserved - Any reproduction even in part is prohibited.

14th

AICT

ASIAN INTERVENTIONAL CARDIOVASCULAR THERAPEUTICS
THE OFFICIAL CONGRESS OF APSIC

7 - 9th September 2018

Hong Kong

Convention and Exhibition Centre (HKCEC)

2018 © AICT Congress 2018. All rights reserved - Any reproduction even in part is prohibited.

2018 © AICT Congress 2018. All rights reserved - Any reproduction even in part is prohibited.