

# SCLERAL LENS STARTER KIT

## The Role of Scleral Lenses in Your Practice

Lynette K. Johns, OD, FAAO, FSLC, FBCIA

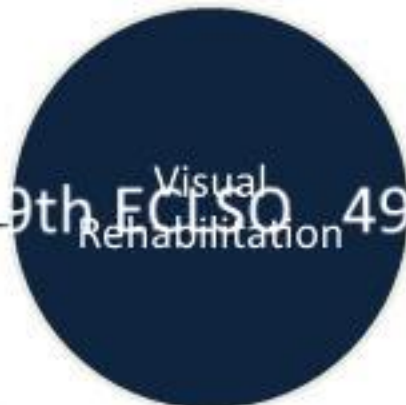Massachusetts Eye and Ear  
Harvard Medical School Department of Ophthalmology

September 2, 2022

# Disclosures

---

- Nothing to disclose



- Keratoconus
- Corneal ectasia
- Post-surgical



- Graft versus Host disease
- Severe Dry Eye
- Ocular Cicatricial Pemphigoid
- Sjögren's syndrome
- Stevens-Johnson syndrome



- Epithelial defects
- Filamentary keratitis
- Neurotrophic keratopathy



- Trichiasis
- Distichiasis
- Lagophthalmos
- Keratinized lid



# Multidisciplinary Collaboration

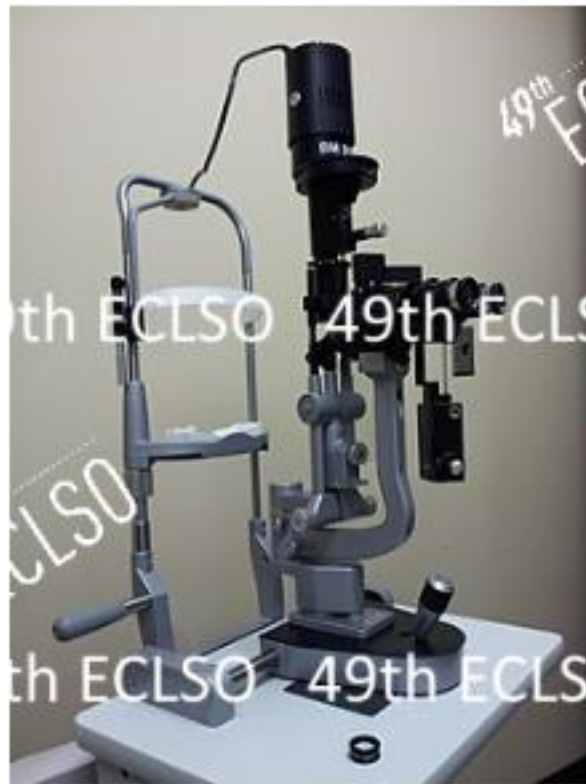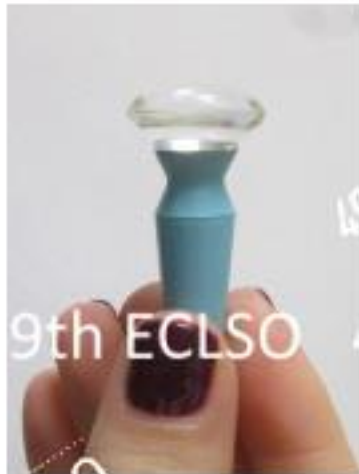---

- Cornea specialists
- General ophthalmologists
- Oculoplastic surgeons
- Oncologists
- Hematologists
- Rheumatologists
- Neurologists
- Dermatologists
- Dentists
- Psychologists
- Psychiatrists
- Chronic pain specialists
- Social workers



# Scleral Lens Starter Kit: What I need

- The Basics



# Scleral Lens Solutions: **PRESERVATIVE-FREE**

- Examples provided are available in the United States

- LacriPure
- ScleralFil
- Purilens
- Nutrifil





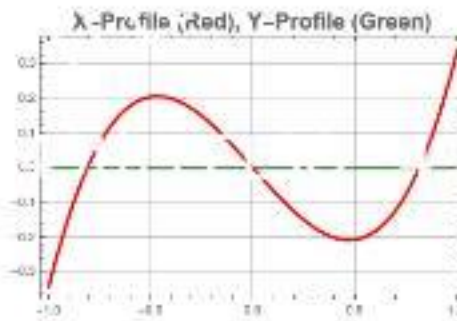
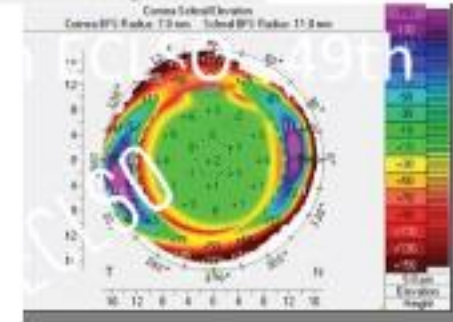
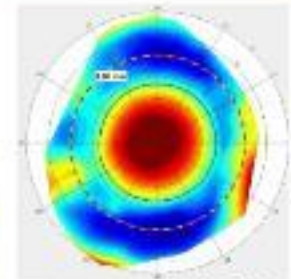
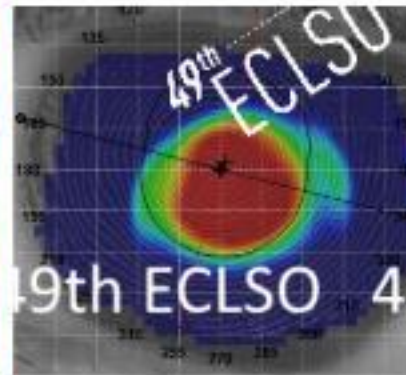
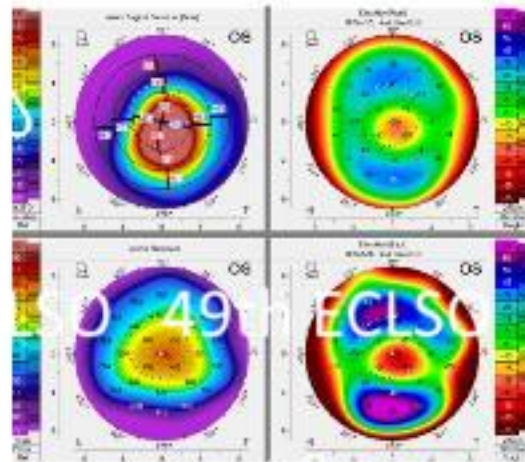
- Single unit dose 0.9% Inhalation saline
- Preservative-free artificial tears
- Preservative-free gel drops to reduce bubble and debris intrusion





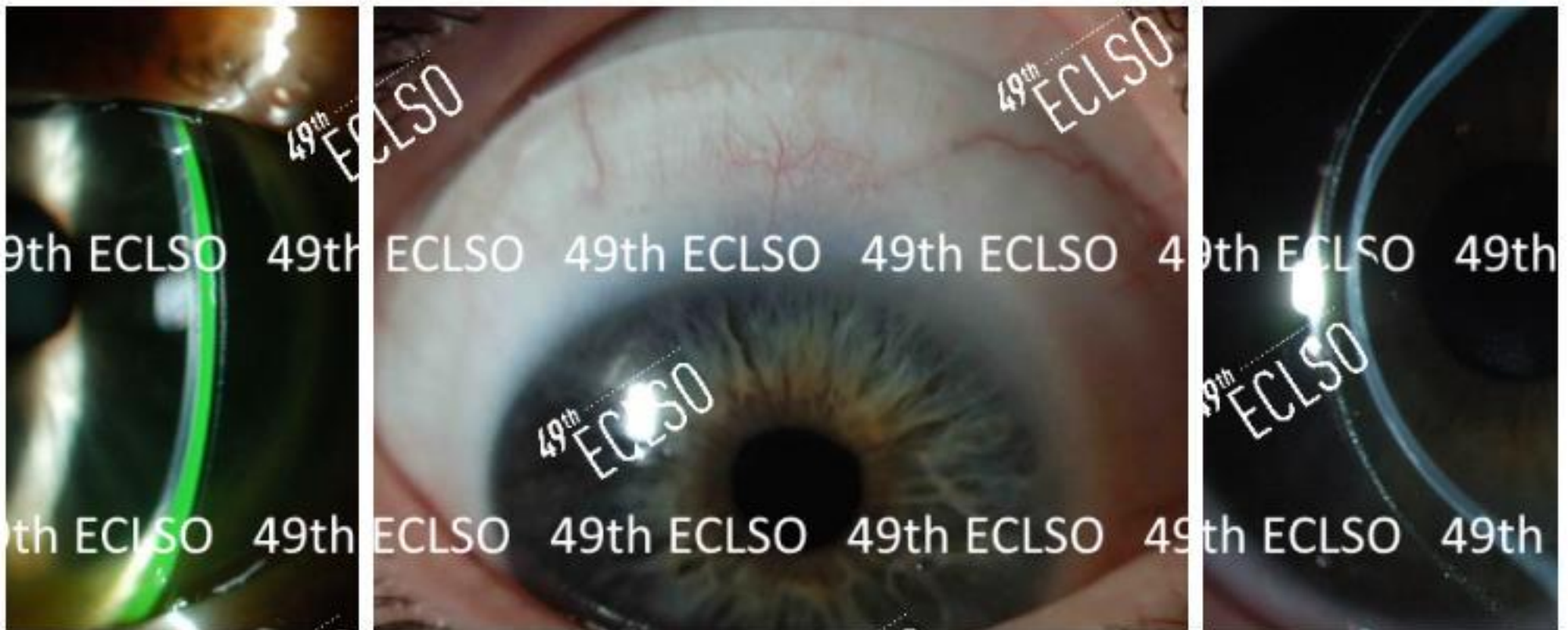# Scleral Lens Starter Kit: Fun but **not** Required

- Topographers
- Tomographers
  - OCT
  - Scheimpflug
- Profilometers
- Aberrometers
- Slit Lamp Camera



Goals of fit: Central corneal clearance and even conjunctival alignment

---

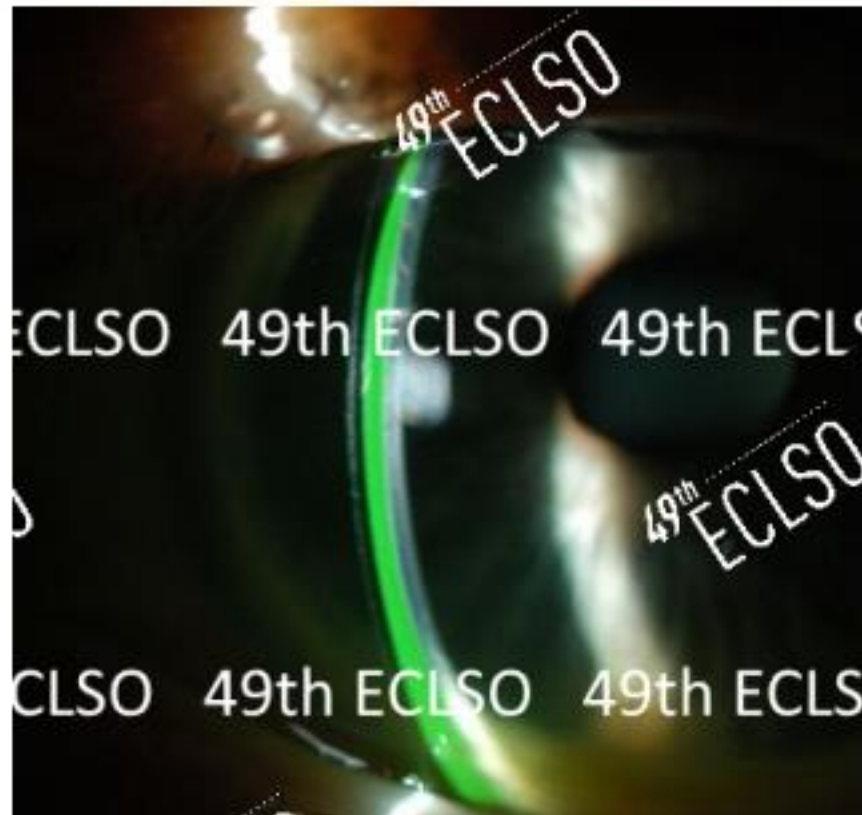




# Corneal Clearance: With Fluorescein

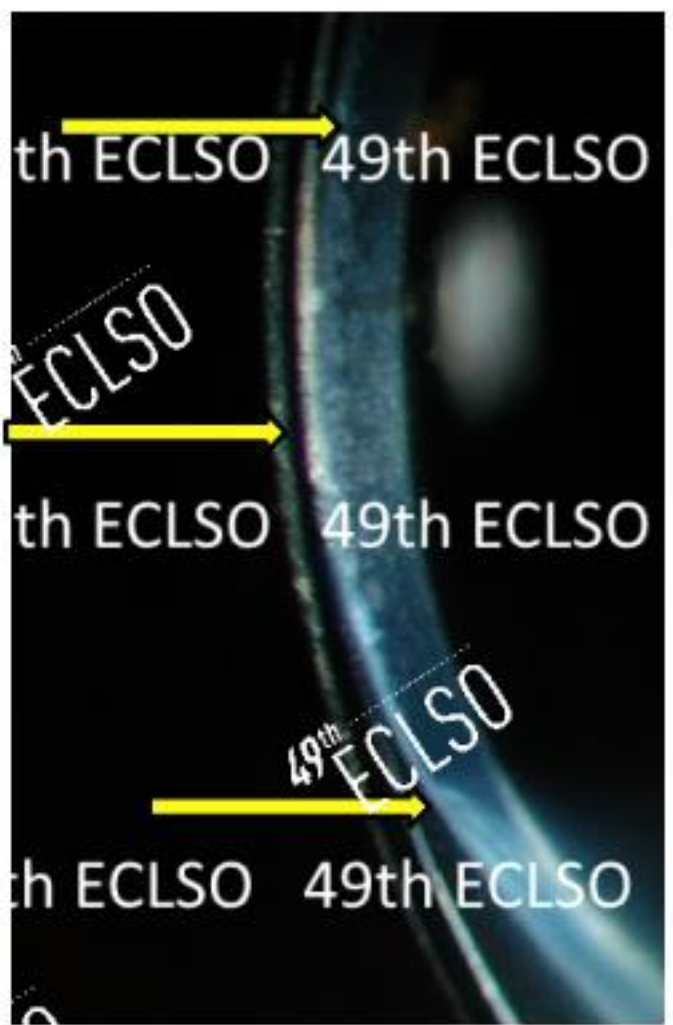
---

- Evaluate Central and Peripheral Clearance



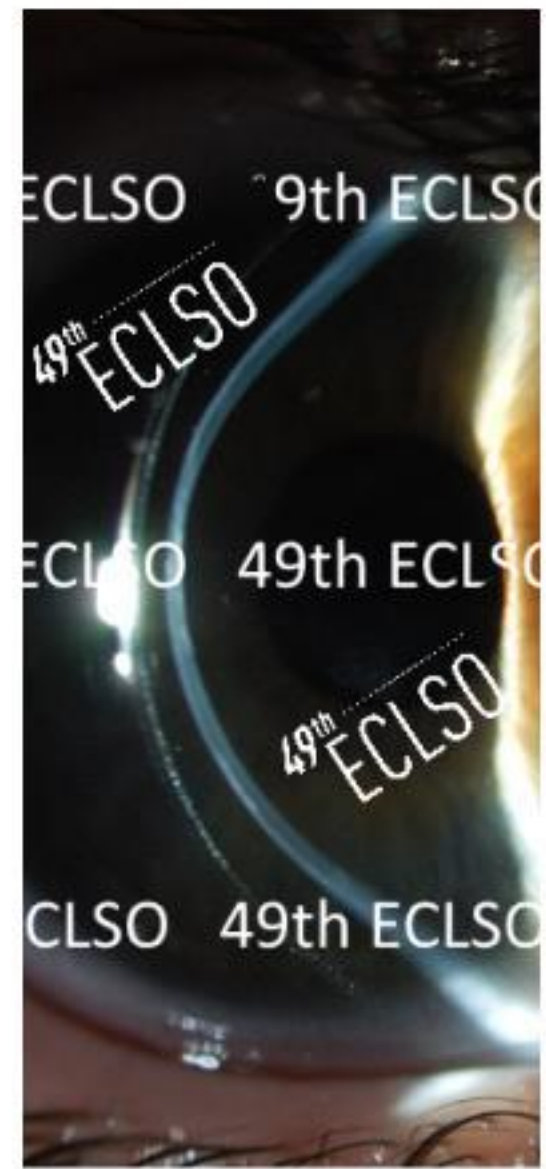


Vaulted space



Lens to cornea contact

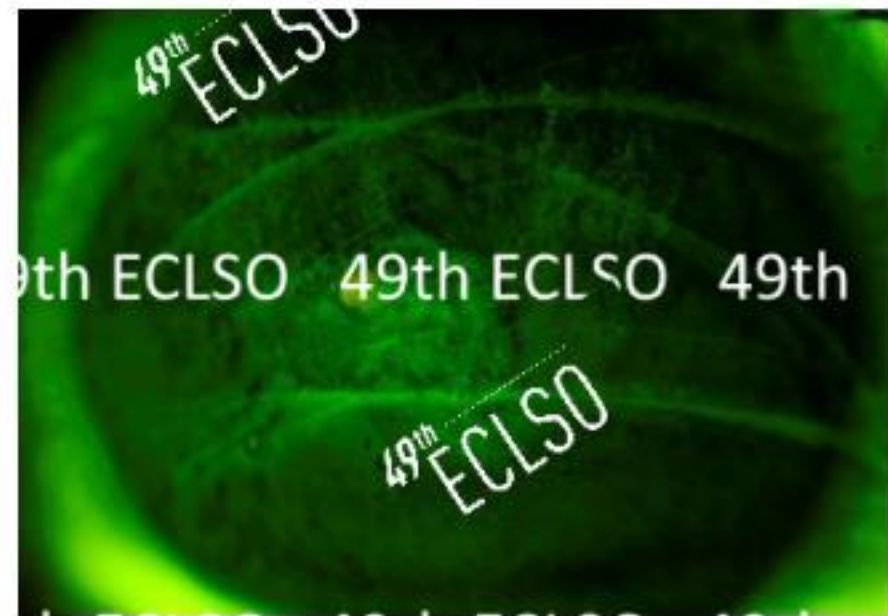
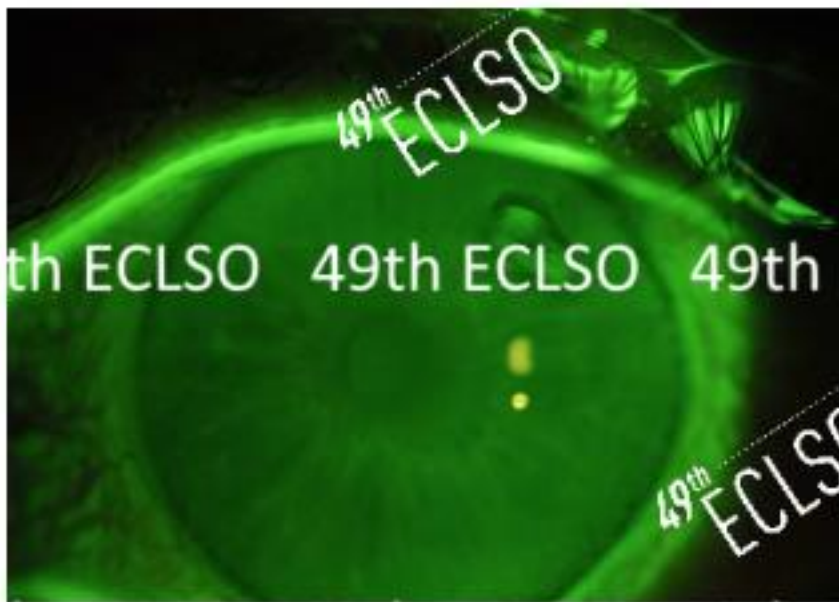
Vaulted space





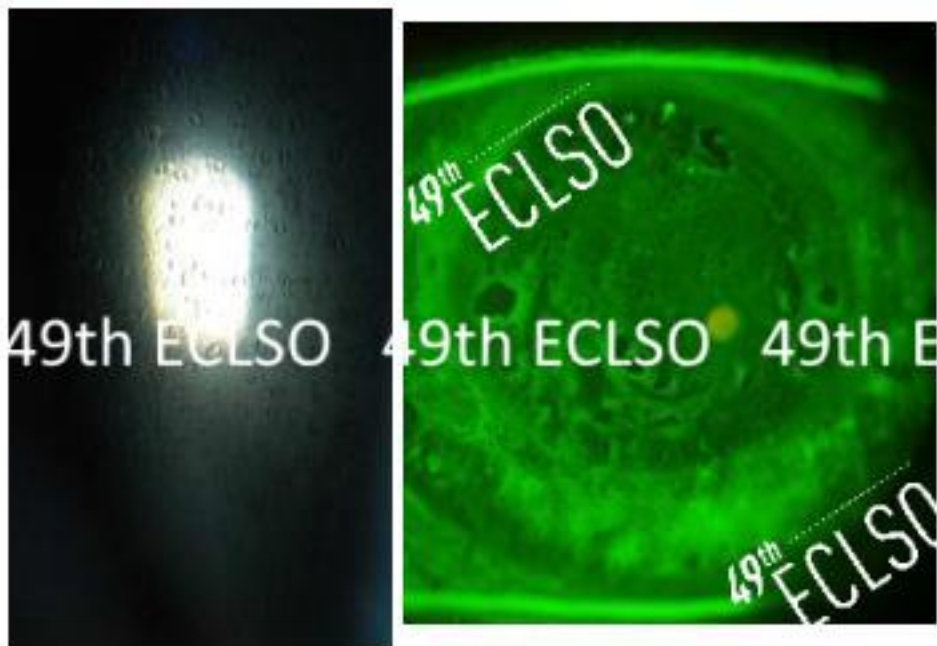
## Signs to Watch For: Cornea

---

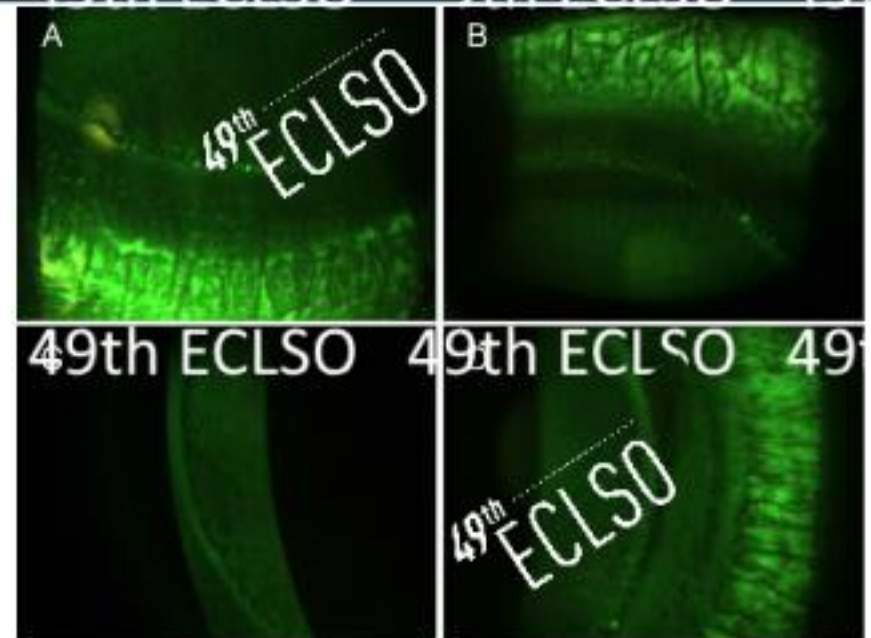


Application errors: Usually in novice patients  
Solution: Need more supervised training

# Microcystic Edema and Bullae



Possible Solutions: Refit to higher Dk  
Loosen the periphery to enhance tear exchange  
If endothelial cell count is low: Consider endothelial keratoplasty

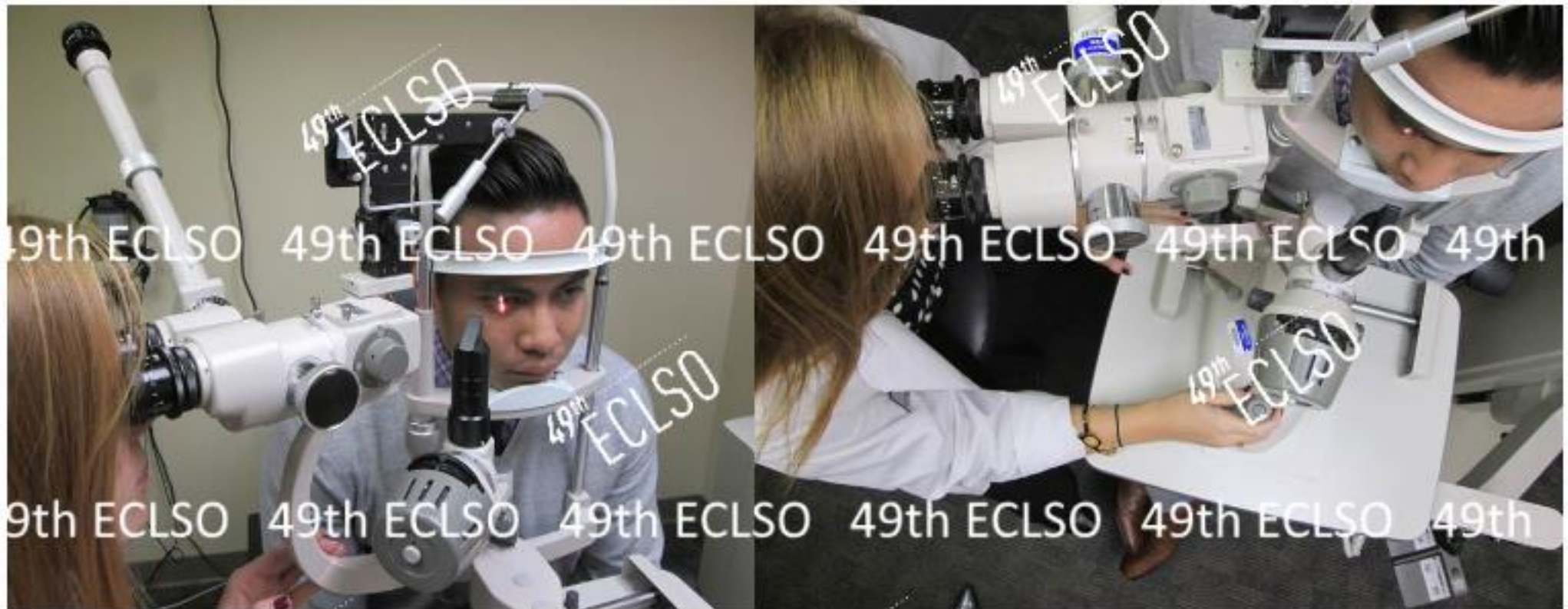

Nixon et al. Contact Lens and Anterior Eye 40 (2017) 116–126

Possible Solutions: Increase limbal clearance zone  
Increase overall diameter  
Depending on design: Flatten base curve  
Increase overall sagittal height



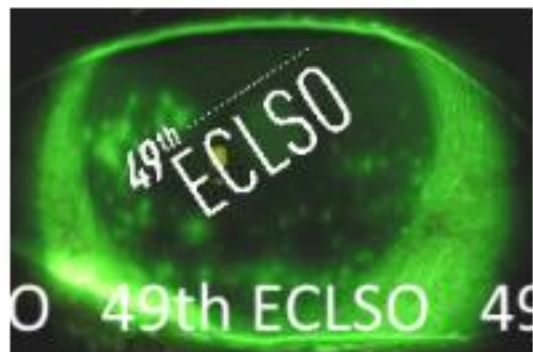# Evaluate the Limbus



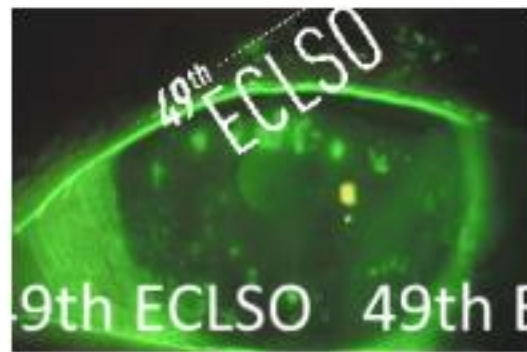


# Optimal Fit: Reduction in Staining with Lens Wear

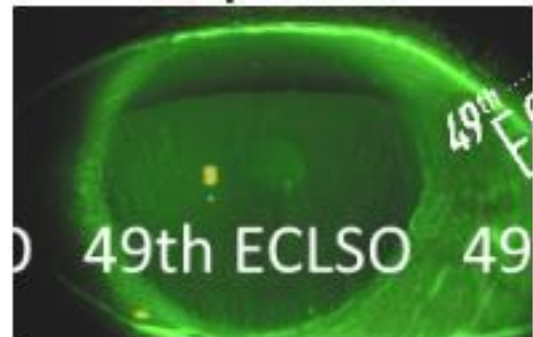
---



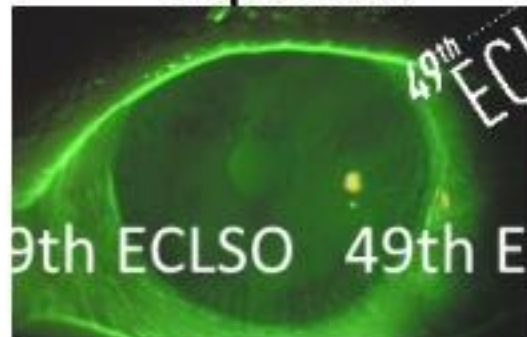
**OD pre-lens**



**OS pre-lens**

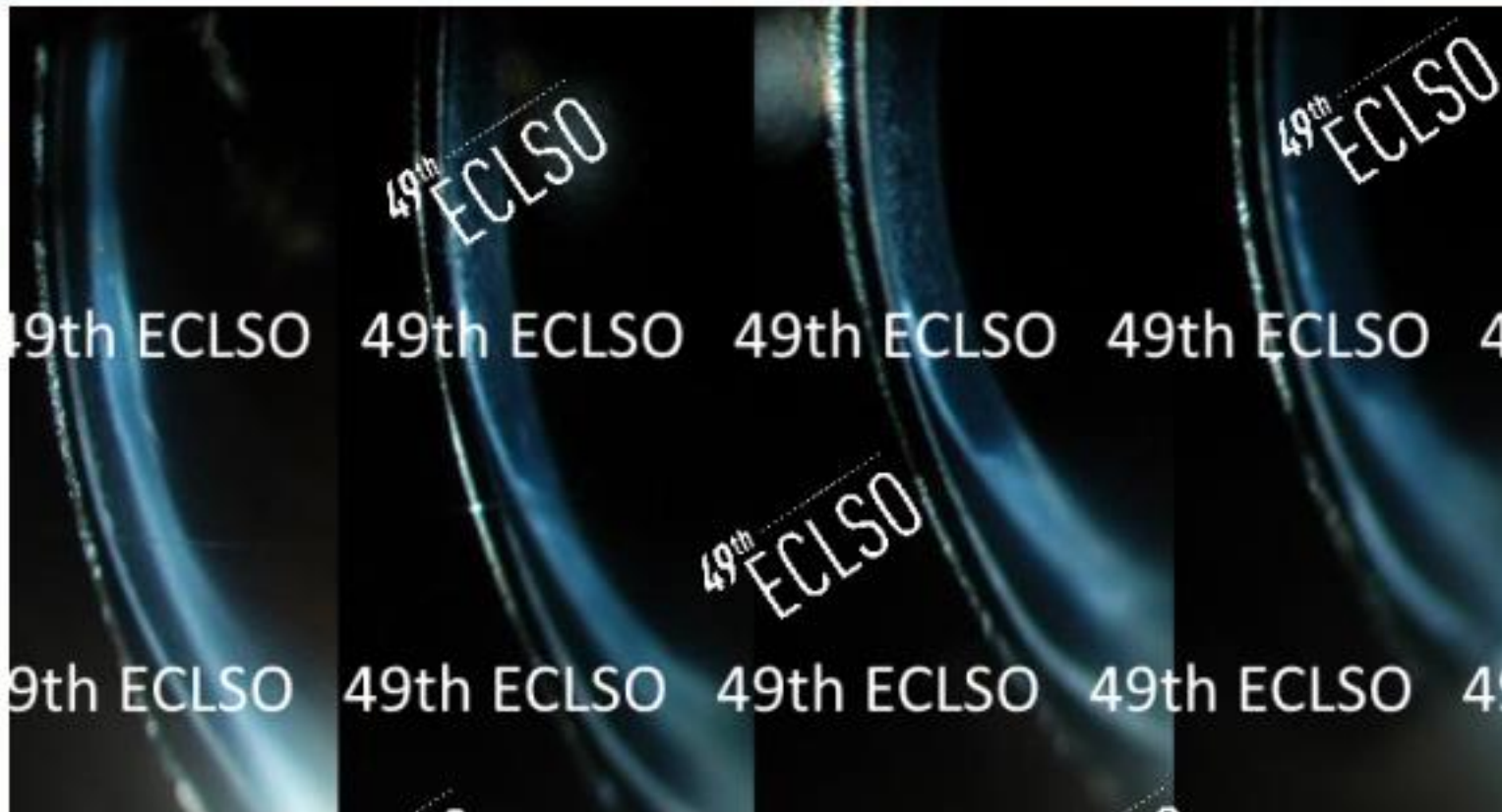

**OD after 6 hours**



**OS after 6 hours**

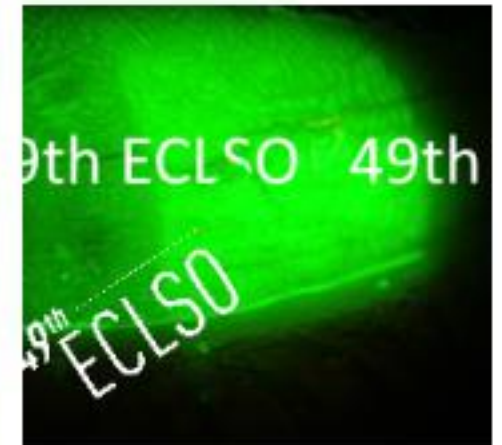
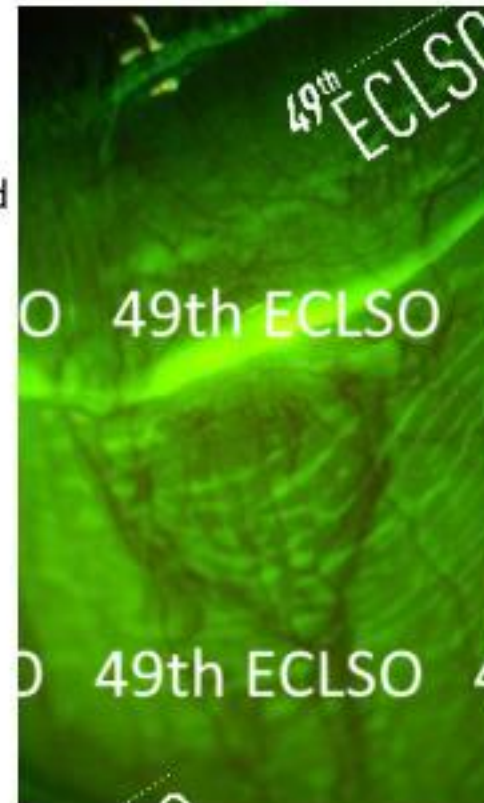
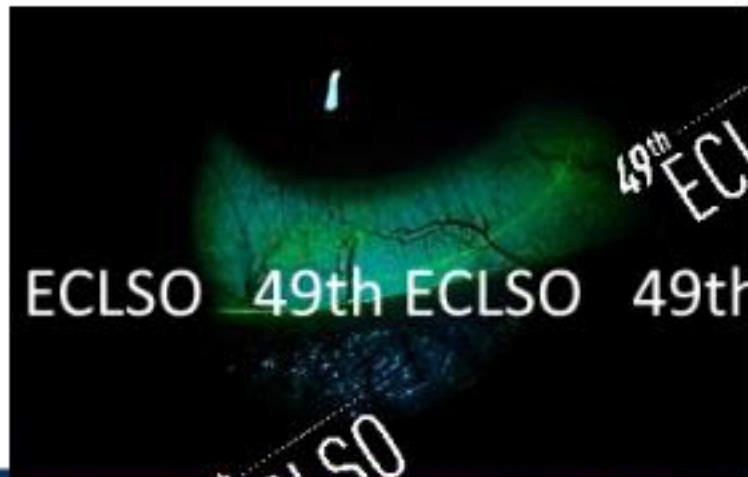
# Corneal Staining after Lens Removal



# Signs to Watch for: Conjunctiva

## Conjunctival Staining

- Arcuate conjunctival staining is likely caused from scleral lens impingement
- Impingement that is very focal can lead to lacerated conjunctiva
- Sometimes a scleral lens can reduce conjunctival staining





# Conjunctival Hyperemia

- When does the redness occur?
  - Before application
    - Nocturnal lagophthalmos
  - Immediately after lens application
    - Mechanical
    - Solutions
    - Bubble
  - End of wearing
    - Compression
    - Impingement
  - After removal
    - Rebound hyperemia
    - Mechanical
- Where is it?
  - Outside the lens vs Inside the lens
- Changes in solutions?
- Changes in systemic medications?
  - Systemic condition flare-up

# Conjunctival Prolapse

- Excessive conjunctival tissue drawn underneath the clearance zone of a scleral lens
- Often associated with an area of extreme clearance
- Neovascularization may occur to leading edge of prolapse
- Prolapse may adhere

*Contact Lens Spectrum*, Volume: 27,  
Issue: April 2012, page(s): 56

---

## Benefits of Scleral Lenses in Ocular Surface Disease

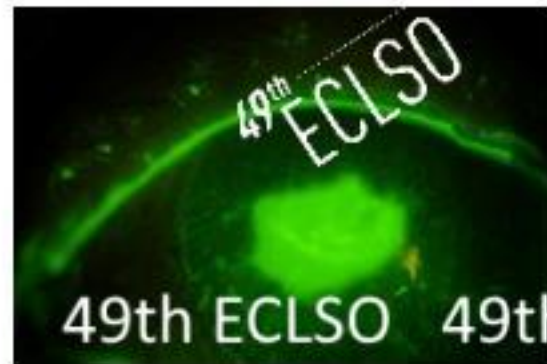

# Re-epithelialization

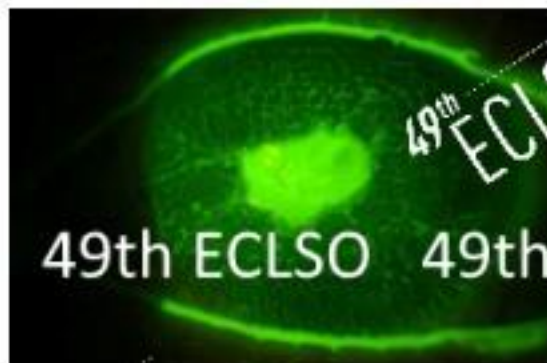---



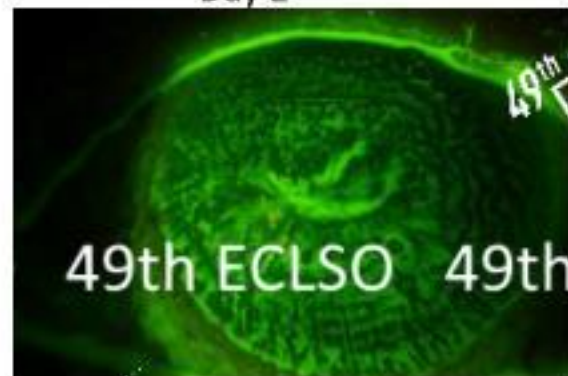Day 1



Day 2



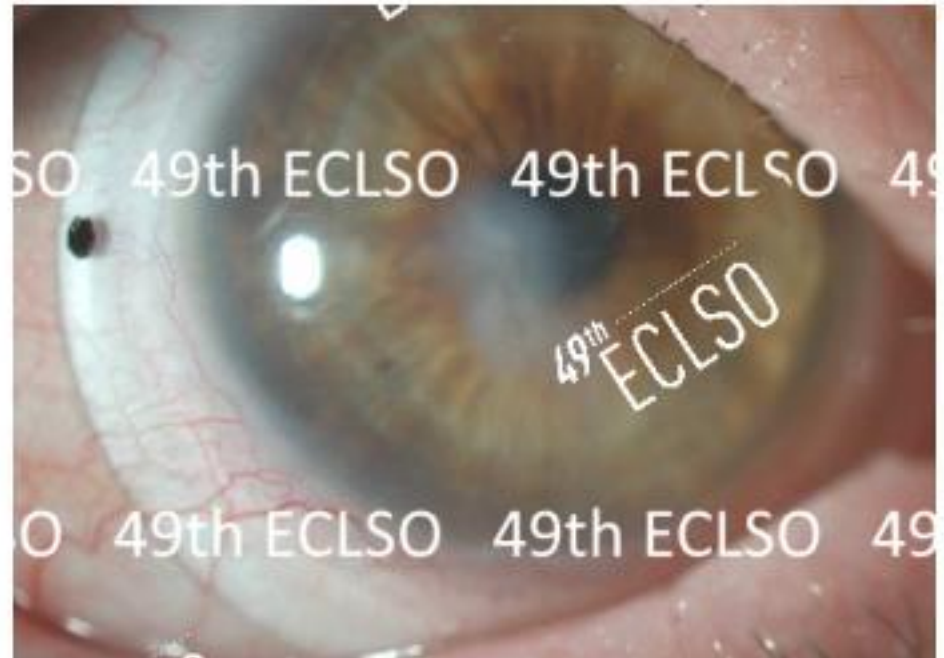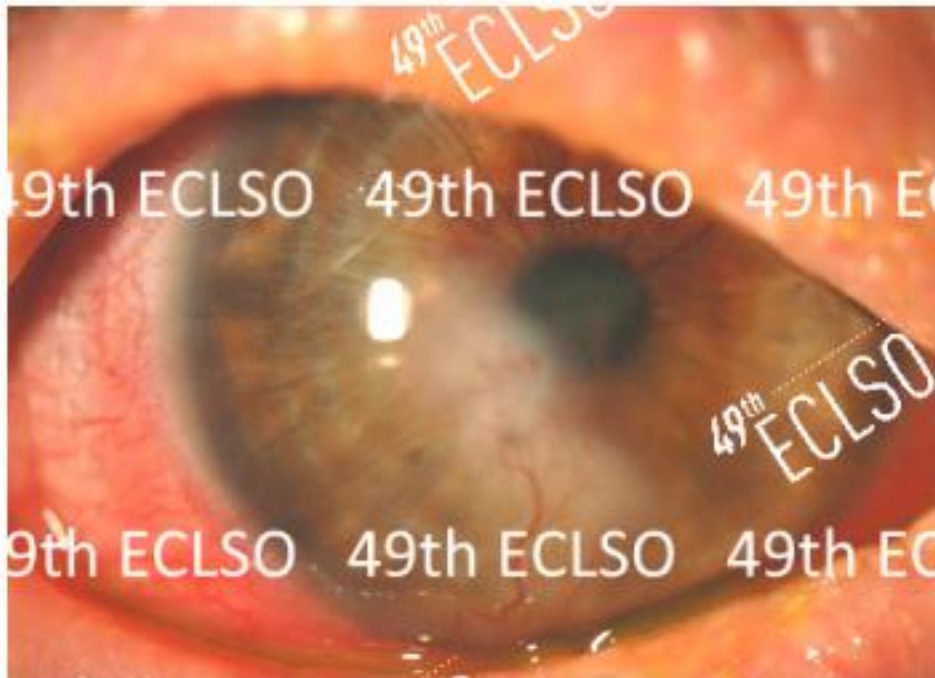
Day 3



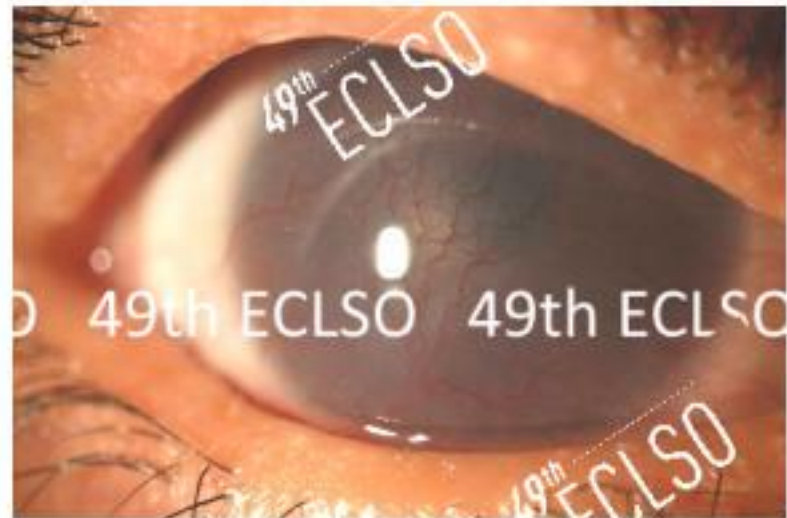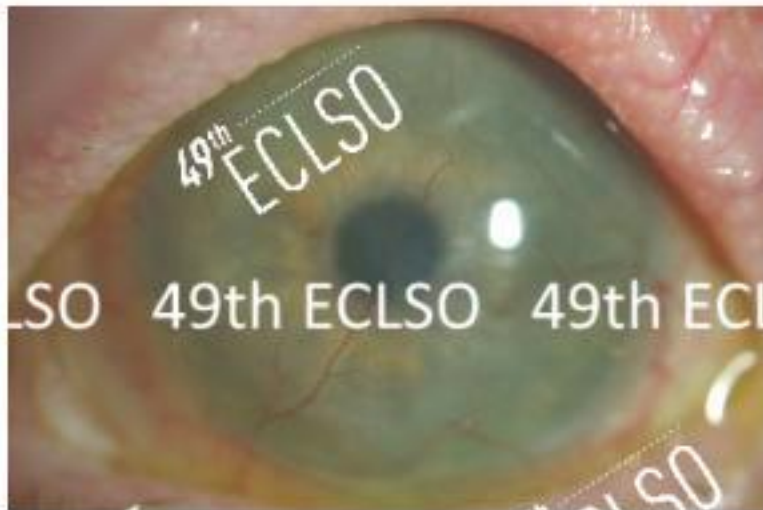
Day 5

# Neovascularization

---



# Visual Rehabilitation




	HM	HM	HM
	20/400	6/120	.05
	20/100	6/30	0.2
→	20/50	6/15	0.4 ←
	20/25	6/7.5	0.8 ←



# Reduction in Opacification

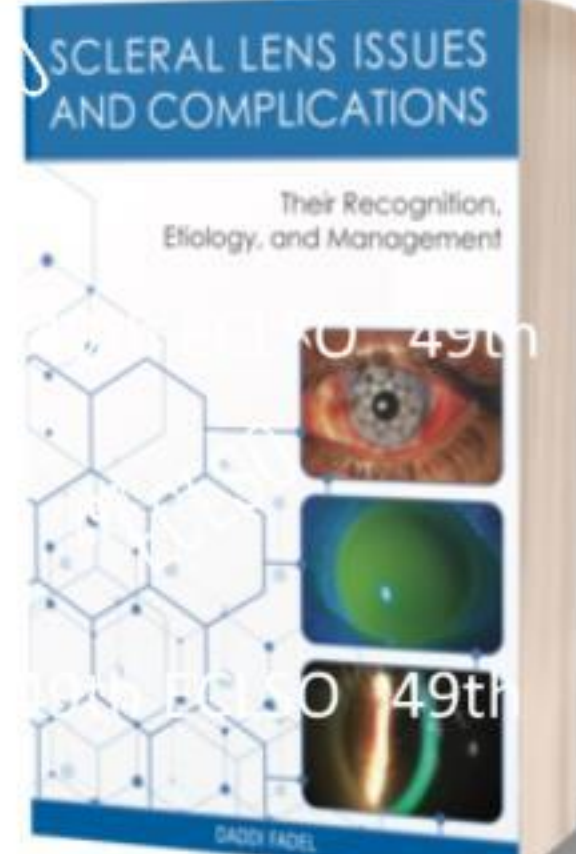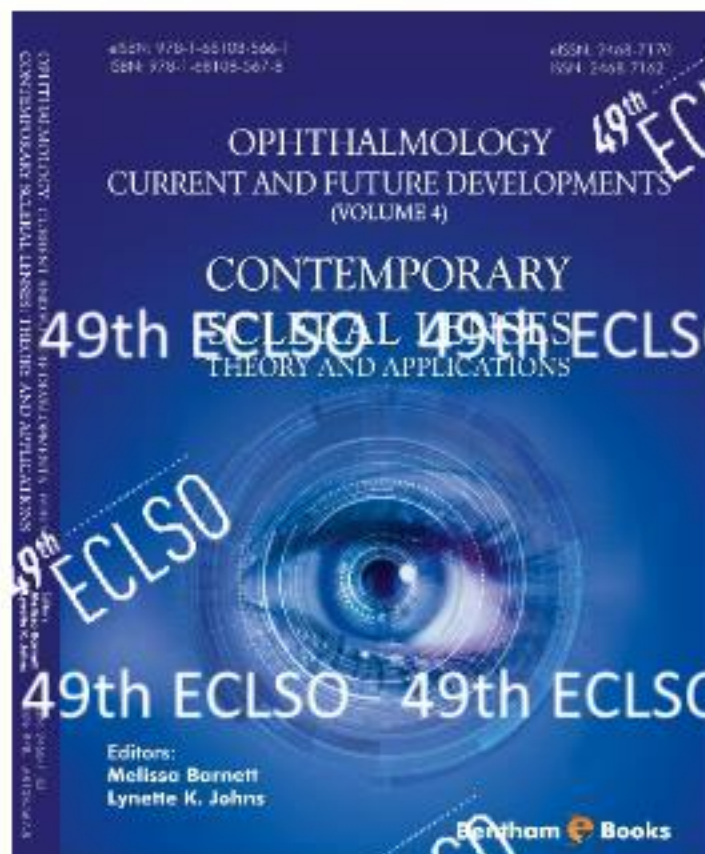
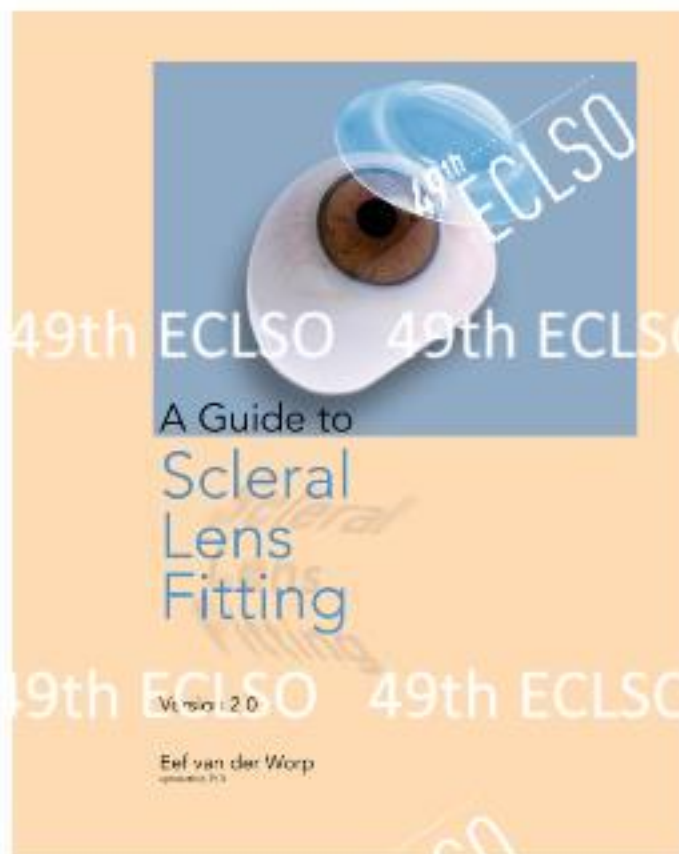
---



Initial Presentation

6 years later

# Sccleral Lens Resources

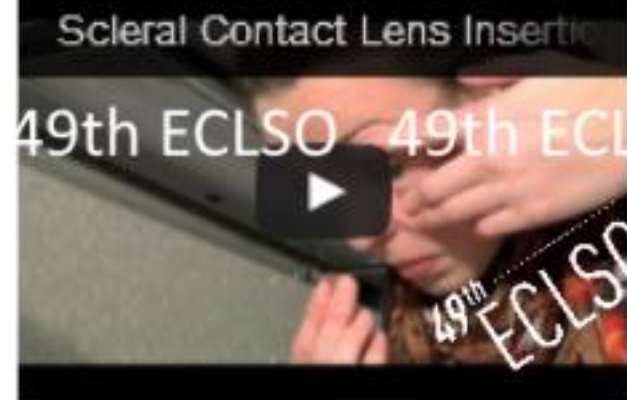

# Application and Removal Video



[www.sclerallens.org](http://www.sclerallens.org)

Video



Scleral Contact Lens Insertion, Removal, Troubleshooting and Lens Care




# Thank you to my mentors!

---



THANK YOU!



Lynette\_Johns@meei.harvard.edu